

A Comparative Outcome Analysis of Bilateral versus Unilateral Endoscopic Extraperitoneal Inguinal Hernioplastics

HUNG LAU, MD, NIVRITTI G. PATIL, MD, and WAI K. YUEN, MD

ABSTRACT

Background: Bilateral inguinal hernia is an accepted indication for endoscopic totally extraperitoneal inguinal hernioplasty (TEP), but few studies have proved that the outcomes of bilateral TEP are as good as those of unilateral TEP. The objective of the present study was to compare the clinical outcomes of patients who underwent unilateral TEP with those of patients who underwent bilateral TEP.

Patients and Methods: From June 1999 to May 2002, 103 patients underwent simultaneous bilateral TEP. The clinical data and outcomes of these patients were compared with those of an age-matched cohort of patients who underwent unilateral TEP during the same period.

Results: The demographic features and hernia types were similar for the two groups. The incidence of direct inguinal hernia was significantly higher in the patients with bilateral inguinal hernia. The mean operative time for unilateral TEP was 65 minutes, and for bilateral TEP it was 97 minutes. The mean pain score at rest was significantly lower in the bilateral group than in the unilateral group on postoperative days 2 and 3. Pain scores at rest and during coughing from the day of operation to day 6 were otherwise comparable for the two groups. Comparisons of postoperative morbidity, length of hospital stay, and time to resumption of normal outdoor activities showed no significant differences between the two groups.

Conclusions: The postoperative recovery and morbidity of patients who underwent bilateral TEP were equivalent to those who underwent unilateral TEP. Simultaneous bilateral TEP is safe and advantageous in patients with from bilateral inguinal hernias.

INTRODUCTION

PATIENTS WITH BILATERAL INGUINAL HERNIA account for about 15% of all inguinal hernia surgical procedures.¹ Although sequential open repair of bilateral inguinal hernia has been the traditional school of thought, simultaneous bilateral repair, irrespective of the technique, has been gaining in popularity during the past two decades.² Simultaneous repair confers the advantage of a single anesthesia, avoids another operation, shortens the length of hospitalization, reduces costs, and averts the risk for strangulation of the contralateral hernia before the patient undergoes the second surgery.³⁻⁷

In comparison with the anterior open repair of an inguinal hernia, the posterior preperitoneal approach reduces the risk for nerve injury and achieves an absolutely tension-free repair, with the mesh acting as an additional buttress to the repair.⁸ Endoscopic totally extraperitoneal inguinal hernioplasty (TEP) is based on the principles of the posterior approach via key hole incisions, thereby bestowing additional benefits of minimal access surgery. Although bilateral inguinal hernia is currently an accepted indication for TEP, little evidence is available to indicate whether bilateral TEP achieves the same results as those of unilateral TEP.⁹ The objective of the present study was to compare the outcomes of patients who un-

Department of Surgery, University of Hong Kong Medical Center, Tung Wah Hospital, Hong Kong.

derwent unilateral TEP with those of patients who underwent bilateral TEP.

PATIENTS AND METHODS

Between July 1999 and May 2002, 103 patients underwent bilateral TEP (bilateral group). An age-matched cohort of 103 patients, who underwent unilateral TEP (unilateral group), was randomly selected during the same period. The perioperative outcomes and follow-up data were extracted from a computer database, and the demographic features and outcome data of the unilateral and bilateral groups were compared.

Surgical technique

The operative details of unilateral TEP have been previously described.¹⁰ A three-port technique was used. Balloon dissection and urinary catheterization were not performed. The extraperitoneal space was dissected and created by means of endoscissors with diathermy. Our technique for unilateral TEP evolved during the study period. Stapling of the mesh has been considered unnecessary for a hernial defect measuring less than 4 cm diameter since February of 2001. The hernia types were determined intraoperatively according to the Nyhus classification.¹¹

For bilateral TEP, after the left inguinal hernia had been repaired as described previously, endoscissors were used to dissect the right extraperitoneal space. A 5-mm trocar, the fourth port, was inserted at the right anterior axillary line approximately 2 cm proximal to the anterior superior iliac spine (Fig. 1). After reduction of the hernial sac and parietalization of the spermatic cord for a length of approximately 4 cm, a 10 × 14-cm² Prolene mesh was introduced to cover the posterior wall of the right inguinal canal, deep inguinal ring, and femoral ring. For bilateral TEP, both meshes were routinely anchored in place with an endostapler (Multifire Endo Hernia 0°, U.S. Surgical Corporation, Norwalk, Connecticut). Skin incisions were infiltrated with 10 mL of 0.5% bupivacaine before closure.

The patients were allowed to resume a normal diet and normal activities after the operation. All patients were prescribed an oral compound analgesic, 50 mg of propoxyphene and 325 mg of paracetamol, four times daily, and were given 100 mg of diclofenac sodium SR daily on demand. All were instructed to complete a chart for the daily documentation of pain scores, on a scale from 0 to 10, at rest and during coughing. The length of hospital stay was defined as the total number of nights spent in the hospital after the operation. All patients were seen at the hernia clinic by the operating surgeon 1 week after discharge. All complications were recorded, and any clinical recurrence was documented.

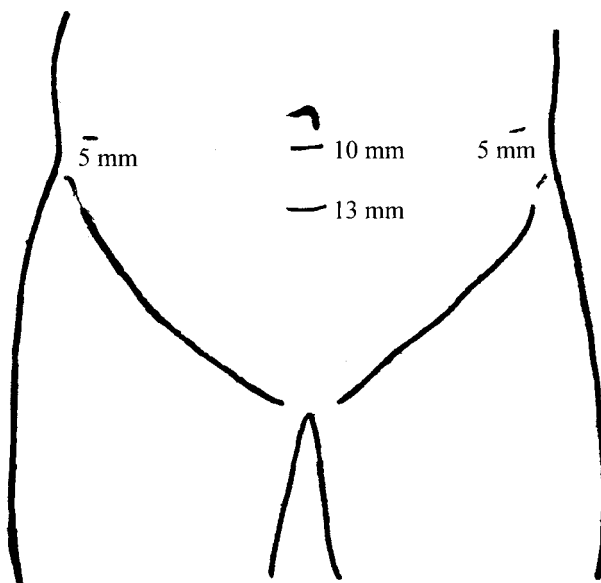


FIG. 1. Sites of the four trocar ports on the abdomen.

Statistical analysis

The statistical differences between groups were determined by the Student *t* test and the chi-square test when appropriate. A *P* value of less than .05 was regarded as significant. Statistical analysis was performed with the aid of computer software (SPSS/PC+ 9.0, SPSS, Chicago, Illinois). Values were expressed as mean ± standard deviation. Some of the early results have been published previously.¹²

RESULTS

Of the 450 patients who underwent TEP, 103 patients (22.9%) had a simultaneous bilateral procedure, for a total of 553 repairs. Preliminary examination of the baseline data for the patients who underwent unilateral TEP (*n* = 347) and those who underwent bilateral TEP (*n* = 103) revealed that the patients who underwent bilateral TEP were significantly older (67 ± 10 years) than those who underwent unilateral TEP (63 ± 14 years) (*P* < .05). An age-matched cohort of 103 patients was therefore randomly selected for subsequent analyses.

Table 1 compares the demographic features and hernia types of the two groups. The incidence of direct inguinal hernias (63%) was significantly higher in the bilateral group than in the unilateral group (24%) (*P* < .05). The mean operative time for unilateral TEP was 64 ± 26.1 minutes, and for bilateral TEP it was 97 ± 35.4 minutes. Conversions to transabdominal preperitoneal inguinal hernioplasty (TAPP) were required in one patient in the bilateral group and two patients in the unilateral

TABLE 1. COMPARISON OF DEMOGRAPHIC FEATURES AND HERNIA TYPES BETWEEN THE TWO GROUPS OF PATIENTS

	<i>Unilateral TEP</i> (<i>n</i> = 103)	<i>Bilateral TEP</i> (<i>n</i> = 103)	P
Age (y)	66.8 ± 10.4	66.8 ± 10.3	NS ^b
Sex (male:female)	97:6	101:2	NS ^c
Hernia types ^a			0.05 ^c
II	48	35	
IIIA	25	130	
IIB	18	24	
IIIC	1	2	
IVA	5	9	
IVB	4	5	
IVC	1	0	
IVD	1	1	

^aNyhus classification.¹¹

^bStudent *t* test.

^cChi-square test.

NS, not significant; TEP, totally extraperitoneal inguinal hernioplasty.

group because of adhesions (*n* = 2) and a sliding inguinal hernia (*n* = 1). No conversions to open repair were required in the present series. Concomitant procedures included the Jaboulay operation (*n* = 2), laparoscopic cholecystectomy (*n* = 1), repair of paraumbilical hernia (*n* = 1), hemorrhoidectomy (*n* = 1), and excision of an elbow mass (*n* = 1).

Table 2 shows the postoperative morbidity of the two groups. The mean length of hospital stay was 1.5 ± 1.6 days for the unilateral group and 1.7 ± 1.1 days for the bilateral group (*P* = NS). The postoperative pain score at rest was significantly lower in the bilateral group than in the unilateral group on postoperative days 2 and 3 (*P* < .05). Otherwise, the postoperative pain scores at rest and during coughing from the day of operation to postoperative day 6 were comparable between the two groups (Figs. 2 and 3). The patients required a convalescence of 3.8 ± 2.5 days after unilateral TEP and 3.5 ± 1.8 days after bilateral TEP before resuming normal outdoor ac-

tivities (*P* = NS). Follow-up ranged from 1 week to 2.6 years, with a mean of 7 months. A single recurrence in the bilateral group required an open repair. The overall recurrence rate was 0.3%.

DISCUSSION

Consistent with the findings of other studies, the incidence of direct inguinal hernia was significantly higher in patients with bilateral hernia than in those with unilateral hernia.^{4,13} The development of direct inguinal herniation has been attributed to defective collagen in the inguinal tissues, which accounts for the frequent development of bilateral lesions and a greater risk for recurrence than in indirect inguinal hernia.¹⁴ In the present study, bilateral TEP was performed only in patients with clinical inguinal hernia. Prophylactic repair of the contralateral side has been advocated by some centers.^{15,16}

TABLE 2. COMPARISON OF POSTOPERATIVE ADVERSE EFFECTS BETWEEN THE TWO GROUPS OF PATIENTS

	<i>Unilateral TEP</i> (<i>n</i> = 103)	<i>Bilateral TEP</i> (<i>n</i> = 103)	P ^a
Seroma	9	9	NS
Urinary retention	3	4	NS
Bruising	3	5	NS
Pulmonary tuberculosis	0	1	NS
Wound dehiscence	0	1	NS
Gouty arthritis	1	0	NS
Vas deferens division	1	0	NS

^aChi-square test.

NS, not significant; TEP, totally extraperitoneal inguinal hernioplasty.

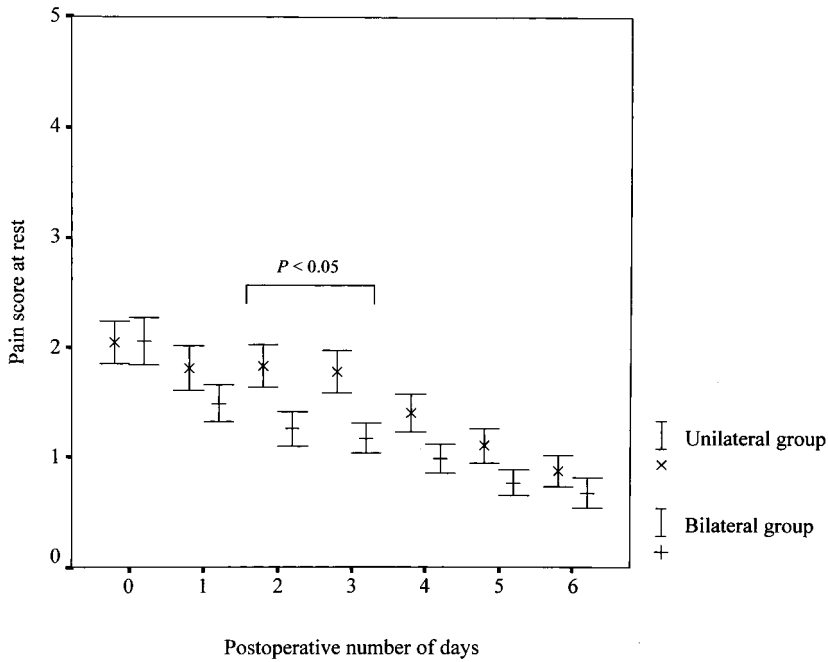


FIG. 2. Comparison between the postoperative linear analogue pain scores at rest of the unilateral TEP group and those of the bilateral TEP group ($P = NS$).

In contrast to our technique of dissecting the preperitoneal space with endoscissors, advocates of prophylactic repair frequently use an inflatable balloon for the preperitoneal dissection, which inevitably violates the contralateral preperitoneal space and makes future TEP difficult. Prophylactic repair is therefore performed when a patient has a contralateral inguinal hernia. However,

Fischer et al.¹ have pointed out that it is not yet known whether repair of the contralateral hernia prevents future complications or traumatizes the abdominal wall unnecessarily and increases the risk for surgical morbidity. At present, the prophylactic repair of an incidentally found contralateral hernia appears unjustified.

Although recent studies have demonstrated similar re-

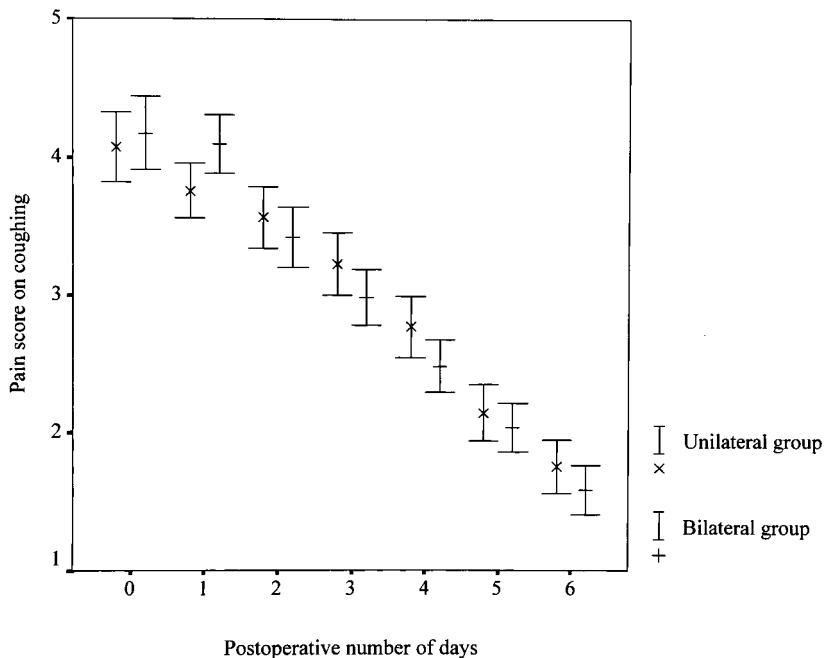


FIG. 3. Comparison between the postoperative linear analogue pain scores on coughing of the unilateral TEP group and those of the bilateral TEP group ($P = NS$).

currence rates after unilateral and bilateral open tension-free repair of inguinal hernia, Miller et al.⁴ reported a significantly higher incidence of morbidity, particularly urinary retention, in patients who underwent bilateral repair. In addition, postoperative genital edema, involving the penis and scrotum, was frequently observed after bilateral simultaneous repair of inguinal hernia, with a reported incidence ranging from 4% to 13%.⁷ The hospital stay was also significantly longer in patients who underwent bilateral simultaneous repair than in those who underwent unilateral repair. Disabling pain that limits walking sometimes occurs after simultaneous bilateral open repair. No prospective randomized trials have been conducted to prove that bilateral anterior open repair achieves the same results as unilateral open repair.

Our results illustrate comparable rates of morbidity and recovery following unilateral and bilateral TEP. To our surprise, the bilateral group had a lower pain score at rest on postoperative days 2 and 3 than the unilateral group. This finding was unanticipated because bilateral TEP involved the dissection of both preperitoneal spaces, stapling of another mesh, and the placement of an additional 5-mm port. The difference in the pain scores may be attributable to multiple comparisons or to differences in hernia pathology between the two groups.

CONCLUSION

In this study, the postoperative recovery and morbidity of patients who underwent bilateral TEP were equivalent to those of patients who underwent unilateral TEP. Bilateral TEP was not associated with increased pain after surgery. Simultaneous bilateral TEP is a safe and cost-effective approach for the management of bilateral inguinal hernias.

ACKNOWLEDGMENT

The authors wish to acknowledge the kind assistance of Tze-Ching Tan, M.D., in editing the manuscript.

REFERENCES

1. Fischer S, Cassivi S, Paul A, Troidl H. Evidence-based medicine and special aspects in bilateral inguinal hernia repair. *Hernia* 1999;3:89-95.
2. Welsh DR, Alexander MA. The Shouldice repair. *Surg Clin North Am* 1993;73:451-469.
3. Duvie SO. One-stage bilateral inguinal herniorrhaphy in the adult. *Can J Surg* 1984;27:192-193.
4. Miller AR, Van Heerden JA, Naessens JM, O'Brien PC. Simultaneous bilateral hernia repair. A case against conventional wisdom. *Ann Surg* 1991;213:272-276.
5. Stott MA, Sutton R, Royle GT. Bilateral inguinal hernias: simultaneous or sequential repair? *Postgrad Med J* 1988;64:375-378.
6. Dakkuri RA, Ludwig DJ, Traverso LW. Should bilateral inguinal hernias be repaired during one operation? *Am J Surg* 2002;183:554-557.
7. Serpell JW, Johnson C, Jarrett PE. A prospective study of bilateral inguinal hernia repair. *Ann R Coll Surg Engl* 1990;72:299-303.
8. Patino JF, Garcia-Herreros LG, Zundel N. Inguinal hernia repair. The Nyhus posterior preperitoneal repair. *Surg Clin North Am* 1998;78:1063-1074.
9. Ahmad SA, Schuricht AL. A comparison of patient recovery following unilateral and bilateral endoscopic preperitoneal herniorrhaphy. *JSLs* 1997;1:231-235.
10. Lau H, Patil NG, Lee F, Yuen WK. A prospective trial of analgesia following endoscopic totally extraperitoneal inguinal hernioplasty: Local wound infiltration versus extraperitoneal instillation of bupivacaine. *Surg Endosc* 2002;16:159-162.
11. Nyhus LM. Individualization of hernia repair: A new era. *Surgery* 1993;114:1-2.
12. Lau H, Patil NG, Lee F, Yuen WK. Two hundred endoscopic extraperitoneal inguinal hernioplasties: cost containment by reusable instruments. *Chin Med J* 2002;115:888-891.
13. Schmedt CG, Daubler P, Leibl BJ, Kraft K, Bittner R, Laparoscopic Hernia Repair Study Team. Simultaneous bilateral laparoscopic inguinal hernia repair: An analysis of 1336 consecutive cases at a single center. *Surg Endosc* 2002;16:240-244.
14. Wantz GE. Complications of inguinal hernia repair. *Surg Clin North Am* 1984;64:287-298.
15. O'Rourke A, Zell JA, Varkey-Zell TT, Barone JL, Bayona M. Laparoscopic diagnosis and repair of asymptomatic bilateral inguinal hernias. *Am J Surg* 2002;183:15-19.
16. Sayad P, Abdo Z, Cacchione R, Ferzli G. Incidence of incipient contralateral hernia during laparoscopic hernia repair. *Surg Endosc* 2000;14:543-545.

Address reprint requests to:

Hung Lau, MD

Department of Surgery

University of Hong Kong Medical Center

Tung Wah Hospital

12 Po Yan Street, Sheung Wan

Hong Kong

E-mail: lauh@hkucc.hku.hk