

## Long-term survival after intraluminal brachytherapy for inoperable hilar cholangiocarcinoma: A case report

Siu-Yin Chan, Ronnie T. Poon, Kelvin K. Ng, Chi-Leung Liu, Raymond T. Chan, Sheung-Tat Fan

Siu-Yin Chan, Ronnie T. Poon, Kelvin K. Ng, Chi-Leung Liu, Sheung-Tat Fan, Centre for the Study of Liver Disease and Department of Surgery, The University of Hong Kong, Pokfulam, Hong Kong, China  
Raymond T. Chan, Department of Clinical Oncology, The University of Hong Kong, Pokfulam, Hong Kong, China  
Correspondence to: Dr. Ronnie T. Poon, Department of Surgery, The University of Hong Kong, Queen Mary Hospital, 102 Pokfulam Road, Hong Kong, China. poontp@hkucc.hku.hk  
Telephone: +852-285-53641 Fax: +852-281-75475  
Received: 2004-07-12 Accepted: 2004-09-19

### Abstract

Surgical resection with a tumor-free margin is the only curative treatment for hilar cholangiocarcinoma (Klatskin tumor). However, over half of the patients present late with unresectable tumors. Radiotherapy using external beam irradiation or intraluminal brachytherapy (ILBT) has been used to treat unresectable hilar cholangiocarcinoma with satisfactory outcome. We reported a patient with unresectable hilar cholangiocarcinoma surviving more than 6 years after combined external beam irradiation and ILBT.

© 2005 The WJG Press and Elsevier Inc. All rights reserved.

**Key words:** Brachytherapy; Hilar cholangiocarcinoma

Chan SY, Poon RT, Ng KK, Liu CL, Chan RT, Fan ST. Long-term survival after intraluminal brachytherapy for inoperable hilar cholangiocarcinoma: A case report. *World J Gastroenterol* 2005; 11(20): 3161-3164

<http://www.wjgnet.com/1007-9327/11/3161.asp>

### INTRODUCTION

Cholangiocarcinoma is a malignant tumor arising from either the extra- or intra-hepatic bile duct. The histological types include adenocarcinoma, carcinoma *in situ*, papillary adenocarcinoma, mucinous adenocarcinoma, and squamous cell carcinoma<sup>[1]</sup>. Hilar cholangiocarcinoma (Klatskin tumor) is a specific disease entity involving malignant tumors that locate in the biliary confluence at the liver hilum. Surgical resection with an adequate tumor-free margin is the only curative treatment<sup>[2]</sup>. The reported medium survival after surgical resection ranges from 16 to 46 mo<sup>[3-5]</sup>. A 5-year survival rate ranging from 21% to 25% after curative hepatectomy for hilar cholangiocarcinoma has been reported<sup>[6,7]</sup>. However, the prognosis of most patients with hilar cholangiocarcinoma is usually poor because of

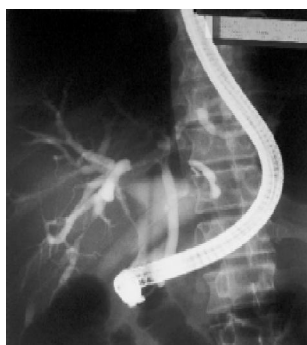
the low resectability rate, ranging from 28% to 37%<sup>[3,4,6,8]</sup>. This can be related to their locally advanced disease with extensive biliary and/or vascular involvement, presence of distant metastases, and poor pre-morbid conditions precluding a major operation. The median survival for patients with unresectable hilar cholangiocarcinoma has been reported to be 6-12 mo<sup>[3,4,6,9]</sup>.

Among the palliative therapies for unresectable hilar cholangiocarcinoma, radiotherapy can achieve satisfactory local tumor control and possible survival benefit. It can be given in the form of external beam radiotherapy (EBRT), intraluminal brachytherapy (ILBT), or a combination of both. With the advancement in computerized 3D treatment planning system, the accuracy of the delivery of EBRT to the targeted tumor has been much improved. This technique leads to tumor shrinkage and improves bile drainage, thus reducing the incidence of septic complications. Likewise, ILBT imposes a high radiation dose to the tumor volume, bypasses the radiosensitive skin and superficial structures, and therefore spares the surrounding normal structures from radiation toxicity. The reported medium survival for unresectable hilar cholangiocarcinoma is 11 mo with ILBT alone<sup>[10]</sup> and 14.5 mo with combined EBRT and ILBT<sup>[11]</sup>. Both techniques offer satisfactory symptom palliation with minimal toxicity and are technically feasible for most patients. However, long-term survival beyond 5 years is very rare after radiotherapy for unresectable cholangiocarcinoma. We reported a patient with unresectable hilar cholangiocarcinoma surviving more than 6 years after combined treatment by EBRT and ILBT, and briefly reviewed the literatures of this treatment modality.

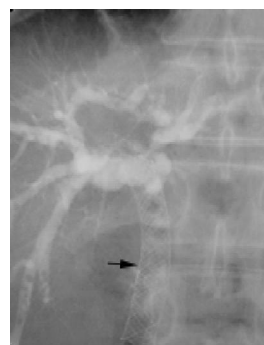
### CASE REPORT

A 49-year-old gentleman presented with painless obstructive jaundice and significant weight loss in May 1998. Liver biochemistry showed elevated bilirubin (185  $\mu\text{mol/L}$ ) and alkaline phosphatase (285 IU/L) concentration. His carcino-embryonic antigen concentration was normal. Endoscopic retrograde cholangiopancreatography (Figure 1) showed a Bismuth type IV stricture<sup>[12]</sup>. Contrast computed tomography (CT) scan of the abdomen revealed enlarged lymph nodes along the hepatoduodenal ligament (Figure 2). Subsequent hepatic and superior mesenteric angiogram showed encasement of the common hepatic artery and main portal vein by the tumor. The tumor was considered unresectable and ultrasound-guided fine needle aspiration cytology of the hilar mass confirmed the diagnosis of hilar cholangiocarcinoma.

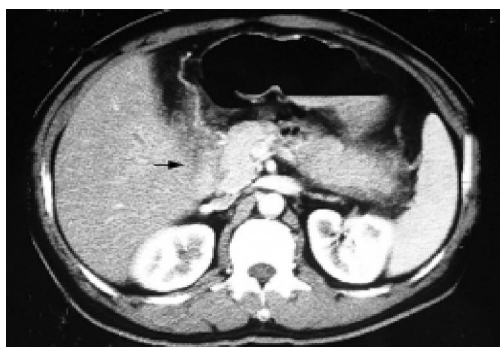
Bile duct decompression was performed by percutaneous transhepatic biliary drainage (PTBD), and the patient received combined EBRT and ILBT. A total of 40 Gy EBRT was



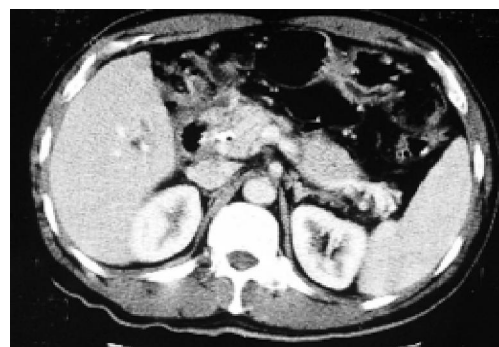**Figure 1** Endoscopic retrograde cholangiopancreatography showing bile duct stricture at liver hilum suggesting hilar cholangiocarcinoma.



**Figure 3** Metallic stent (black arrow) inside common duct on endoscopic retrograde cholangiopancreatography.



**Figure 2** Contrast CT scan showing lymph node enlargement at hepatoduodenal ligament (black arrow).



**Figure 4** Contrast CT scan showing tumor regression after combined ILBT and external beam irradiation.

given to the tumor bed in 20 divided fractions, which was followed by 10 Gy ILBT using iridium 192 ( $\text{Ir}^{192}$ ) wire. These radio-therapeutic procedures were not associated with any complication. A self-expandable metallic stent (Wallstent, Boston Scientific Ltd, USA) (Figure 3) was then inserted via the PTBD tract to bypass the stricture site, and the patency of the metallic stent lasted for 14 mo. Subsequently he required PTBD again when the metallic stent was blocked.

There was evidence of tumor regression on reassessment by CT scan in the first 2 years following the treatment (Figure 4). Subsequently there was slow disease progression with bile duct segregation and tumor infiltration to the second part of the duodenum. The patient relied on long-term PTBD for symptomatic control. Nevertheless, he has survived for more than 6 years since the initial diagnosis was made, and enjoyed a reasonable quality of life. He was able to work after the radiotherapy until the most recent 2 years of his disease course. At the time of writing the manuscript, the patient was still alive with satisfactory general condition.

## DISCUSSION

In spite of its low incidence, hilar cholangiocarcinoma is a deadly tumor because the diagnosis is commonly not made until the disease progresses to its advanced stage which is not amenable to curative resection. The median survival is less than 1 year if the tumor is unresectable<sup>[3,4,6,9]</sup>. The treatment options for unresectable advanced hilar cholangiocarcinoma are limited. Orthotopic liver transplantation has been proposed

to be a curative treatment modality for locally advanced hilar tumors with no evidence of extrahepatic tumors. However, it could be offered only to patients with locally advanced unresectable tumors without widespread metastases. The reported median survival is 25 mo<sup>[13]</sup> and 5-year survival ranges from 30% to 87%<sup>[6,14,15]</sup>. Hassoun *et al*<sup>[14]</sup>, achieved a high 5-year survival of 87% by very careful patient selection including staging laparotomy. Nonetheless, the practice of this treatment option is largely limited by the lack of organ donors and the potential risk of tumor recurrence following immunosuppressive therapy. For most patients with unresectable hilar cholangiocarcinoma, therapeutic efforts are mainly confined to palliation, which primarily involves relief and treatment of cholestasis. However, no palliative treatment is of proven value in prolonging survival.

Mortality of patients with hilar cholangiocarcinoma is usually caused by locoregional phenomena, as a result of liver failure secondary to bile duct obstruction, cholangitis, and sepsis. Bile duct decompression by endoscopic or radiological techniques is of paramount importance. This not only relieves patients' symptoms such as itching and cholangitis, but also facilitates biliary access and recovery of hepatic parenchymal function. In addition, it makes further oncological treatments of the tumor possible<sup>[9]</sup>. In fact, ILBT is regarded to be beneficial as it improves bile drainage in patients with hilar cholangiocarcinoma<sup>[10]</sup>. In case of significant biliary obstruction, prior establishment of patency of the common duct is important for a successful delivery of ILBT. This can be achieved by self-expandable metallic stent insertion, either percutaneously

**Table 1** Survival after radiotherapy for extrahepatic cholangiocarcinoma

Study	No. of patients	Pathology	Mode of radiotherapy	Medium survival (mo)
Fletcher <i>et al</i> <sup>[10]</sup> (1983)	18	Hilar cholangiocarcinoma	ILBT	11
Kuvshinoff <i>et al</i> <sup>[11]</sup> (1995)	12	Hilar cholangiocarcinoma	ILBT+EBRT	14.5
Levitt <i>et al</i> <sup>[19]</sup> (1988)	20	Cholangiocarcinoma	ILBT	10
Ede <i>et al</i> <sup>[20]</sup> (1989)	14	Cholangiocarcinoma	ILBT	10.5
Veeze-Kuijpers <i>et al</i> <sup>[21]</sup> (1990)	31	Cholangiocarcinoma	ILBT+EBRT	8
Morganti <i>et al</i> <sup>[22]</sup> (2000)	20	Cholangiocarcinoma	ILBT+EBRT	13
Gonzalez <i>et al</i> <sup>[23]</sup> (2002)	38	Cholangiocarcinoma	ILBT+EBRT	10.4

ILBT, intraluminal brachytherapy; EBRT, external beam radiotherapy.

or endoscopically via the duodenum<sup>[16,17]</sup>. ILBT prolongs the patency of the metallic stent, which has been reported to range from 6 to 8 mo<sup>[9,17]</sup>. This minimizes the chance of stent occlusion, and delays the use of external biliary drain, which is associated with significant psychological problems and physiological disturbances such as dehydration and electrolyte imbalance<sup>[17]</sup>. Our patient received ILBT before metallic stent insertion, and the patency of the stent lasted for 14 mo after brachytherapy.

With regard to ILBT, there is no randomized controlled study to prove its effectiveness in patients with hilar cholangiocarcinoma<sup>[18]</sup>. The number of patients studied was small in most of the series in the literature<sup>[10,11,19-23]</sup>. The medium survival after ILBT for extrahepatic cholangiocarcinoma has been reported to range from 4 to 13 mo<sup>[19,23]</sup>. With respect to hilar cholangiocarcinoma *per se*, the reported medium survival ranges from 11 to 14.5 mo<sup>[10,11]</sup> (Table 1). ILBT was initially planned as a boost, as part of a treatment regimen for patients with inoperable tumors. This treatment modality was first reported in 1979 by Zimmon *et al*<sup>[24]</sup>. In that study, the iridium wire source was placed through PTBD in four patients. The treatment duration lasted for 24–72 h. It provides symptomatic palliation and significant tumor control without exacerbation of cholestasis or infective complication. It is suggested that early ILBT after PTBD might extend palliation of jaundice due to its effect on the limitation of tumor extension. Ir<sup>192</sup>, with a half-life of 7 d, is the usual irradiation source for ILBT. The wire source can be put through PTBD or a nasobiliary catheter to reach the site of neoplastic stricture under fluoroscopic guidance. The wire can be placed across, parallel to or inside a stent. Au<sup>198</sup> grains, with a shorter half-life of 2.7 d, have also been used for ILBT. It was found that the medical staff is better protected from radioactivity when the Au<sup>198</sup> sources are withdrawn after brachytherapy<sup>[25]</sup>.

The optimal irradiation dose and duration of brachytherapy are unknown. Our patient received a combination of 50-Gy external irradiation. The relationship between irradiation dosage and survival has been studied by Alden and Mohiuddin<sup>[26]</sup>. The patients with cholangiocarcinoma receiving high-dose combined brachytherapy and external beam radiation of more than 55 Gy showed significantly better survival than those who received smaller doses in unresectable cases. Among patients who received high-dose radiation, 48% of them experienced an extended 2-year survival. In another study, brachytherapy was given to five patients with Klatskin tumor for up to 5 d<sup>[27]</sup>. Two ribbons containing Ir<sup>192</sup> seeds were threaded into the right and left percutaneous biliary drainage catheters in a “Y-shaped”

configuration that corresponded well to the “Y-shaped” volume of the Klatskin tumor. Despite all these survival results, long-term survivors after radiation therapy for hilar cholangiocarcinoma, as in our case, have rarely been reported.

The procedure itself is not without risk. In the absence of any standardized protocol for brachytherapy, it is meaningless to compare the overall morbidity in different studies. The reported complication rate for cholangitis, which can be fatal, ranges from 6% to 30%<sup>[11,28,29]</sup>. Complications can be classified as those related to catheter introduction and those resulting from irradiation. There is an increased risk of bacteraemia and bile duct perforation with either endoscopic or percutaneous biliary tract instrumentation. The wire source is introduced to the stricture site commonly via PTBD catheters, thus the potential risks are hemobilia, catheter dislodgement, superficial wound infection, liver abscess, and bile leakage. The complications related to ILBT itself are cholangitis and pancreatitis, as a result of blocked stent with biliary obstruction, as well as gastrointestinal tract upset with peptic ulcer or diarrhea<sup>[11,28]</sup>.

There has been no report on the benefits of offering EBRT in advance to ILBT or vice versa. However, EBRT is given first in the majority of centers. This may be attributed to its effect on tumor shrinkage that prevents cholangitis during brachytherapy treatment. It is also questionable whether the addition of chemotherapy is beneficial to patients with inoperable Klatskin tumors. Basically, the use of chemotherapy is mainly limited to clinical trials. Nomura *et al*<sup>[30]</sup>, reported a survival benefit in patients with unresectable extrahepatic bile duct cancer receiving brachytherapy combined with EBRT and repeated hepatic arterial infusion chemotherapy when compared with those receiving brachytherapy alone.

ILBT was intensely investigated 10 years ago, but it is still not commonly practiced nowadays. This case report showed that palliative combined EBRT and ILBT could be associated with long-term survival. Hence, it is worthwhile to reconsider its potential effect on local tumor control and possible survival benefits by proper randomized controlled trials. Hilar cholangiocarcinoma, once labeled as a dismal disease with poor outcome, can be associated with long-term survival as shown in our patient. In addition to improvement of life expectancy, the prolonging of symptom-free survival is an important target of the treatment as well.

## REFERENCES

- 1 **Tumours of the biliary tract.** In Robert L.Souhami, Ian Tannock (eds). Oxford Textbook of Oncology. OXFORD University Press 2002: 1641-1652

- 2 **Reed DN**, Vitale GC, Martin R, Bas H, Wieman TJ, Larson GM, Edwards M, McMasters K. Bile duct carcinoma: trends in treatment in the nineties. *Am Surg* 2000; **66**: 711-714; discussion 714-715
- 3 **Jarnagin WR**, Fong Y, DeMatteo RP, Gonen M, Burke EC, Bodniewicz BS J, Youssef BA M, Klimstra D, Blumgart LH. Staging, resectability, and outcome in 225 patients with hilar cholangiocarcinoma. *Ann Surg* 2001; **234**: 507-517; discussion 517-519
- 4 **Burke EC**, Jarnagin WR, Hochwald SN, Pisters PW, Fong Y, Blumgart LH. Hilar Cholangiocarcinoma: patterns of spread, the importance of hepatic resection for curative operation, and a presurgical clinical staging system. *Ann Surg* 1998; **228**: 385-394
- 5 **Havlik R**, Sbisa E, Tullo A, Kelly MD, Mitry RR, Jiao LR, Mansour MR, Honda K, Habib NA. Results of resection for hilar cholangiocarcinoma with analysis of prognostic factors. *Hepatogastroenterology* 2000; **47**: 927-931
- 6 **Figueras J**, Llado L, Valls C, Serrano T, Ramos E, Fabregat J, Rafecas A, Torras J, Jaurrieta E. Changing strategies in diagnosis and management of hilar cholangiocarcinoma. *Liver Transpl* 2000; **6**: 786-794
- 7 **Nimura Y**, Kamiya J, Kondo S, Nagino M, Uesaka K, Oda K, Sano T, Yamamoto H, Hayakawa N. Aggressive preoperative management and extended surgery for hilar cholangiocarcinoma: Nagoya experience. *J Hepatobiliary Pancreat Surg* 2000; **7**: 155-162
- 8 **Bathe OF**, Pacheco JT, Ossi PB, Hamilton KL, Franceschi D, Sleeman D, Levi JU, Livingstone AS. Management of hilar bile duct carcinoma. *Hepatogastroenterology* 2001; **48**: 1289-1294
- 9 **Chamberlain RS**, Blumgart LH. Hilar cholangiocarcinoma: a review and commentary. *Ann Surg Oncol* 2000; **7**: 55-66
- 10 **Fletcher MS**, Brinkley D, Dawson JL, Nunnerley H, Williams R. Treatment of hilar carcinoma by bile drainage combined with internal radiotherapy using 192iridium wire. *Br J Surg* 1983; **70**: 733-735
- 11 **Kuvshinoff BW**, Armstrong JG, Fong Y, Schupak K, Getradjman G, Heffernan N, Blumgart LH. Palliation of irresectable hilar cholangiocarcinoma with biliary drainage and radiotherapy. *Br J Surg* 1995; **82**: 1522-1525
- 12 **Bismuth H**, Corlette MB. Intrahepatic cholangioenteric anastomosis in carcinoma of the hilus of the liver. *Surg Gynecol Obstet* 1975; **140**: 170-178
- 13 **Sudan D**, DeRoover A, Chinnakotla S, Fox I, Shaw B, McCashland T, Sorrell M, Tempero M, Langnas A. Radiochemotherapy and transplantation allow long-term survival for nonresectable hilar cholangiocarcinoma. *Am J Transplant* 2002; **2**: 774-779
- 14 **Hassoun Z**, Gores GJ, Rosen CB. Preliminary experience with liver transplantation in selected patients with unresectable hilar cholangiocarcinoma. *Surg Oncol Clin N Am* 2002; **11**: 909-921
- 15 **Robles R**, Figueras J, Turrion VS, Margarit C, Moya A, Varo E, Calleja J, Valdivieso A, Garcia-Valdelcasas JC, Lopez P, Gomez M, de Vicente E, Loinaz C, Santoyo J, Casanova D, Bernardos A, Fernandez JA, Marin C, Ramirez P, Bueno FS, Jaurrieta E, Parrilla P. Liver transplantation for hilar cholangiocarcinoma: Spanish experience. *Transplant Proc* 2003; **35**: 1821-1822
- 16 **Freeman ML**, Sielaff TD. A modern approach to malignant hilar biliary obstruction. *Rev Gastroenterol Disord* 2003; **3**: 187-201
- 17 **Hii MW**, Gibson RN, Speer AG, Collier NA, Sherson N, Jardine C. Role of radiology in the treatment of malignant hilar biliary strictures 2: 10 years of single-institution experience with percutaneous treatment. *Australas Radiol* 2003; **47**: 393-403
- 18 **Khan SA**, Davidson BR, Goldin R, Pereira SP, Rosenberg WM, Taylor-Robinson SD, Thillainayagam AV, Thomas HC, Thursz MR, Wasan H. Guidelines for the diagnosis and treatment of cholangiocarcinoma: consensus document. *Gut* 2002; **51** Suppl 6: VII-VI9
- 19 **Levitt MD**, Laurence BH, Cameron F, Klemp PF. Transpapillary iridium-192 wire in the treatment of malignant bile duct obstruction. *Gut* 1988; **29**: 149-152
- 20 **Ede RJ**, Williams SJ, Hatfield AR, McIntyre S, Mair G. Endoscopic management of inoperable cholangiocarcinoma using iridium-192. *Br J Surg* 1989; **76**: 867-869
- 21 **Veeze-Kuijpers B**, Meerwaldt JH, Lameris JS, van Blankenstein M, van Putten WL, Terpstra OT. The role of radiotherapy in the treatment of bile duct carcinoma. *Int J Radiat Oncol Biol Phys* 1990; **18**: 63-67
- 22 **Morganti AG**, Trodella L, Valentini V, Montemaggi P, Costamagna G, Smaniotto D, Luzi S, Ziccarelli P, Macchia G, Perri V, Mutignani M, Cellini N. Combined modality treatment in unresectable extrahepatic biliary carcinoma. *Int J Radiat Oncol Biol Phys* 2000; **46**: 913-919
- 23 **Gonzalez Gonzalez D**, Gouma DJ, Rauws EA, van Gulik TM, Bosma A, Koedooder C. Role of radiotherapy, in particular intraluminal brachytherapy, in the treatment of proximal bile duct carcinoma. *Ann Oncol* 1999; **10** Suppl 4: 215-220
- 24 **Zimmon DS**, Bursa J, Chang J, Clemett AR. The management of hepatic duct cancer with percutaneous transhepatic biliary stent and intraluminal irradiation. *Gastroenterology* 1979; **77**: 49
- 25 **Hiratsuka J**, Imajo Y, Numaguchi K, Ohumi T, Shirabe T. Radiotherapy of bile duct carcinoma using intracatheter 198Au grains. *Radiat Med* 1991; **9**: 77-81
- 26 **Alden ME**, Mohiuddin M. The impact of radiation dose in combined external beam and intraluminal Ir-192 brachytherapy for bile duct cancer. *Int J Radiat Oncol Biol Phys* 1994; **28**: 945-951
- 27 **Kumar PP**, Good RR, McCaul GF. Intraluminal endocurietherapy of inoperable Klatskin's tumor with high-activity 192iridium. *Radiat Med* 1986; **4**: 21-26
- 28 **Lu JJ**, Bains YS, Abdel-Wahab M, Brandon AH, Wolfson AH, Raub WA, Wilkinson CM, Markoe AM. High-dose-rate remote afterloading intracavitary brachytherapy for the treatment of extrahepatic biliary duct carcinoma. *Cancer J* 2002; **8**: 74-78
- 29 **Montemaggi P**, Costamagna G, Dobelbower RR, Cellini N, Morganti AG, Mutignani M, Perri V, Brizi G, Marano P. Intraluminal brachytherapy in the treatment of pancreas and bile duct carcinoma. *Int J Radiat Oncol Biol Phys* 1995; **32**: 437-443
- 30 **Nomura M**, Yamakado K, Nomoto Y, Nakatsuka A, Ii N, Shoji K, Takeda K. Clinical efficacy of brachytherapy combined with external-beam radiotherapy and repeated arterial infusion chemotherapy in patients with unresectable extrahepatic bile duct cancer. *Int J Oncol* 2002; **20**: 325-331