

Heart and Liver R2 and R2* Measurements in Patients with Thalassaemia Major at 3T

H. Guo^{1,2}, W.-Y. Au³, J. S. Cheung^{1,2}, J. H. Jensen⁴, D. Kim⁴, P.-L. Khong⁵, Q. Chan⁶, C. Tosti⁷, H. Tang⁷, T. R. Brown⁷, W. W. Lam⁸, S.-Y. Ha⁹, G. M. Brittenham¹⁰, and E. X. Wu^{1,2}

¹Laboratory of Biomedical Imaging and Signal Processing, The University of Hong Kong, Hong Kong, China, People's Republic of, ²Department of Electrical and Electronic Engineering, The University of Hong Kong, Hong Kong, China, People's Republic of, ³Department of Medicine, The University of Hong Kong, Hong Kong, ⁴Department of Radiology, New York University School of Medicine, New York, United States, ⁵Department of Diagnostic Radiology, The University of Hong Kong, Hong Kong, ⁶Philips Electronics Hong Kong Limited, ⁷Radiology, Columbia University College of Physicians and Surgeons, New York, United States, ⁸Department of Diagnostic Radiology and Organ Imaging, Chinese University of Hong Kong, Hong Kong, ⁹Pediatrics and Adolescent Medicine, The University of Hong Kong, Hong Kong, ¹⁰Department of Pediatrics and Medicine, Columbia University College of Physicians and Surgeons, New York, United States

Introduction

Heart and liver R2 and R2* have been employed at 1.5T as indicators of tissue iron overload in patients with thalassaemia major, hereditary hemochromatosis, aplastic anemia, myelodysplasia and other disorders [1-3]. At 3T, cardiac MR is technically challenging, in part because of increased physiologic motion artifacts, SAR increase, and marked B0 and B1 inhomogeneity. Moreover, both baseline R2* and variability in R2* increase substantially at 3T, interfering with accurate measurement in patients with severe tissue iron overload [4]. As 3T scanners are increasingly adopted for routine clinical applications, investigation of the limitations of R2 and R2* measurements in studies of iron overload is imperative. This study aims to examine the feasibility of myocardial and hepatic iron quantitation at 3T. We implemented the breathhold multi-echo spin-echo (MESE) and multi-echo gradient-echo (MEGE) sequences at 3T to measure R2 and R2*, respectively. R2 and R2* measurements were compared at 3T and 1.5T in patients with thalassaemia major and healthy controls.

Method

Patients: Two normal subjects and 25 thalassaemia patients (14-73 yrs with mean age 37.8 ±15.3 yrs) with varying levels of iron overload were studied. To minimize inter-subject and intra-subject variation, all were trained in the breathhold procedure before MR acquisitions.

R2 and R2* mapping protocol: Combining partial Fourier and SENSE acquisition, a hybrid TSE/MESE sequence [5] was implemented on a 3T Philips Achieva scanner with 6-channel cardiac coil. In brief, 2 k-space lines are acquired per TR (i.e., turbo factor = 2) so that single-slice multi-echo R2 mapping could be obtained within a single breathhold (~15 cardiac cycles). The TE of the 1st echo was 5 ms, largely limited by the minimum duration of the selective 180° pulse duration (which was in turn limited by the maximum B1 of 13.5 μT and 25 kW peak RF power for body transmission). The effective echo spacing was 10 ms with FOV=370-400 mm, TR=1 cardiac cycle (750-1200ms), acquisition matrix=128x96, SENSE factor=2, partial Fourier factor=0.6, slice thickness =10 mm for 90° excitation (and 30 mm thickness for 180° excitations to minimize stimulated echo effects), crushers along all 3 directions, and ECG trigger delay set to late diastole. Double-inversion black blood technique was used for flow artifact reduction and better LV wall delineation [6,7]. The slice was positioned to cover the short-axis LV view at the mid-ventricular level, as well as part of the liver. The total echo numbers ranged from 8 to 12 (with 4-6 echo images accordingly), which were determined by the heart rate and SAR limit at 3T. This single-breathhold R2 mapping was repeated three times during each scan for averaging. To map R2*, a single-breathhold MGRE sequence was used to measure R2* at the same slice location with 25 echoes, turbo field echo factor equal to 4 and breathhold for 9 cardiac cycles. The 1st TE and echo spacing were 1.56-2 ms and 1-2 ms, respectively, depending on the patient iron overload level. All other parameters were the same as those for R2 measurement. The same patients were also scanned with a 1.5T Siemens scanner for heart R2 using a similar breathhold MESE sequence and for heart and liver R2* using a similar MGRE sequence as previously described [2,3,6].

Data analysis: ROIs were drawn in the mid-ventricular septum and liver for heart and liver measurements, respectively. R2 and R2* values were calculated by fitting the ROI signals to a mono-exponential model. For heart R2 measurement, an identical ROI was used in analyzing the 3 single breathhold acquisitions but with slight position adjustment to account for the shifts between the 3 breathholds, and the average heart R2 calculated.

Results and Discussion

Fig.1 illustrates typical single-breathhold MESE images obtained at 3T and the computed T2 map in a patient. R2* could not be measured reliably in 4 patients with severe iron overload (R2* ~500 s⁻¹); thus these patients are not included here. Figs. 2a and 2b show the relationship between R2* and R2 at 3T in the heart and liver, respectively. Good R2 and R2* correlations (as indicated by Spearman Rho analysis here) suggest that both R2 and R2* can be used as iron overload indicator at 3T. Figs. 3a shows the 3T R2* vs. 1.5T R2* in heart, exhibiting a correlation similar to that reported in an earlier work [4]. Fig. 3 b shows the correlation between 3T R2 at 1.5T R2 in heart.

Conclusion

We investigated the heart and liver R2 in thalassaemia iron overload patients for the first time at 3T, together with R2* measurements. The results demonstrate close correlations between 3T and 1.5T measurements. They indicate that myocardial and liver R2 can be measured at 3T as indicators for iron overload. For patients with severe iron overload, R2* or T2* measurements can be problematic, particularly at 3T. R2 measurement may present an alternative and reliable approach to assessment of iron deposition at 3T.

References:

[1] Brittenham GM et al. Blood 2003;101:15. [2] Lam WW et al. JMRI 2008;28:29. [3] He T et al. JCMR 2008;10:11. [4] Storey P et al. JMRI 2007;25 :540. [5] Kim D et al. 2009 ISMRM Proceedings (submitted). [6] He T et al. JMRI 2006;24:580. [7] Greenman RL et al. JMRI 2003;17:648.

Acknowledgements: GRF7794/07M, NIH R01DK066251/R01DK069373/R37DK049108, AHA0730143N and Children Thalassaemia Foundation.



Fig. 1 3T MESE images with TE=5, 15, 25, 35, 45 and 55 ms obtained with the single-breathhold sequence, together with the computed T2 map.

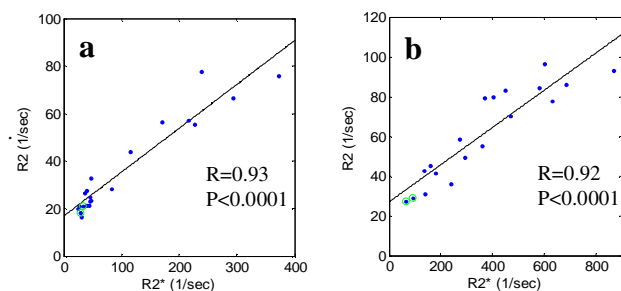


Fig. 2 (a) Heart R2 vs. R2* at 3T in septal myocardium; (b) liver R2 vs. R2* at 3T. Two normal subjects are marked by green circles.

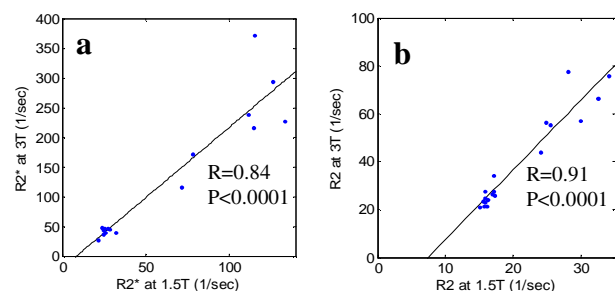


Fig. 3 (a) 3T R2* vs. 1.5T R2* in the heart; (b) 3T R2 vs. 1.5T R2* for heart in septal myocardium.