

Accumulation of p53 protein in inverted transitional cell papilloma of the urinary bladder

K W Chan, K Y Lam, G Srivastava

Abstract

Aims—To study the possible accumulation of p53 protein in inverted papilloma of the urinary bladder.

Methods—Formalin fixed, paraffin wax embedded sections from 14 cases of inverted papilloma of the urinary bladder were studied retrospectively. Accumulation of p53 was detected by immunohistochemistry using a mouse monoclonal antibody directed against p53. p53 protein reactivity was scored as follows: 0 = 10%; 1 = 10% to <30%; 2 = 30% to <50%; and 3 = >50% of cells p53 positive.

Results—The 14 sections were scored as follows: 3 in four cases; 2 in four cases; 1 in one case; and 0 in five cases. Overall, nine (64%) of the 14 cases were positive for p53 protein.

Conclusions—The accumulation of p53 protein in inverted papilloma of the urinary bladder suggests that p53 may have an important role in the neoplastic process of this tumour. However, the benign nature of inverted papillomas suggests that p53 protein accumulation is not related to tumour invasiveness and metastasis. p53 reactivity cannot be used as a marker of malignancy for urothelial neoplasia. Further studies are required to determine the role of p53 protein in the oncogenesis of urothelial neoplasms.

(J Clin Pathol: Mol Pathol 1996;49:M43-M45)

Keywords: immunohistochemistry, p53, inverted papilloma, urothelial neoplasm.

Urothelial inverted papilloma is an uncommon benign tumour that may be mistaken for papillary transitional cell carcinoma. These two tumours can be difficult to differentiate on routine histological examination. While p53 gene mutations are common in transitional cell carcinomas of urinary bladder,¹⁻⁴ their frequency in urothelial inverted papillomas is unknown. The aim of this study was to ascertain whether p53 protein is accumulated in inverted papillomas and whether it can be used to distinguish inverted papillomas from papillary transitional cell carcinoma.

The p53 gene encodes a 53 kDa nuclear phosphoprotein which acts as a tumour suppressor gene.⁵ The wild-type p53 protein is associated with the control of the normal cell cycle, DNA repair and synthesis, cell differentiation, genomic plasticity, and apoptosis. The gene is located on the short arm of chromosome 17 and it consists of 11 exons, in-

cluding five conserved regions in which most of the p53 mutations in tumours have been found.⁶ The wild-type p53 protein is almost undetectable because of its short half-life of only five to 20 minutes. Mutant p53, however, can be detected by immunohistochemistry.⁷ We studied the accumulation of p53 protein in archival formalin fixed, paraffin wax embedded tissue using a standard immunohistochemical method, incorporating the DO-7 antibody directed against p53 and heat mediated antigen retrieval, because this method is reliable and easy to use.⁸

Methods

Routinely processed paraffin wax blocks of 16 cases of urothelial inverted papilloma were retrieved from the files of the Department of Pathology, Queen Mary Hospital, Hong Kong. The original slides on which the diagnosis was made were reviewed. The clinical history as entered on the biopsy request forms was noted. Two cases were excluded as there was insufficient tissue in one and severe artefacts were present in the other.

Sections (5 µm) from the paraffin wax blocks were de-paraffinised and rehydrated. They were treated with 3% hydrogen peroxide for 10 minutes, washed in water and rinsed with Tris buffered saline (TBS) at pH 7.6. Sections were wholly immersed in 10 mM citrate buffer at pH 6.0 and irradiated in a microwave oven (Energy Beam Sciences Inc., H2500 Microwave Processor, Agawam, Massachusetts, USA) at 95°C for nine minutes. Then, 10% normal rabbit serum was added at room temperature for 10 minutes. Primary mouse monoclonal antibody directed against p53, NCL-p53-DO-7 diluted 1 in 25 (Novocastra Laboratories, Newcastle, UK), was added and the sections were incubated in a moist chamber overnight at 4°C. The antibody recognises both wild-type and mutant p53. The sections were then washed three times for three minutes each in 0.05 M TBS. Biotinylated rabbit anti-mouse immunoglobulin (diluted 1 in 100, Dako-E354, Dako, Copenhagen, Denmark) was added and incubated at 37°C for 30 minutes. The sections were again washed three times for three minutes each in 0.05 M TBS. Streptavidin-biotin complexes/horseradish peroxidase (diluted 1 in 100; Dako-K377) was added and the sections were incubated in a moist chamber for 45 minutes at 37°C. The sections were then washed three times for three minutes each in 0.05 M TBS and were developed in freshly prepared diaminobenzidine/H₂O₂ solution for six minutes at room tem-

Department of Pathology, The University of Hong Kong, Hong Kong
K W Chan
K Y Lam
G Srivastava

Correspondence to: Dr K W Chan, Department of Pathology, The University of Hong Kong, Hong Kong.

Accepted for publication 10 October 1995

Demographic data of patients, tumour size and p53 score for 14 inverted papillomas of the urinary bladder

Case No.	Size (mm)	Age (years)	Sex	p53 score
1	12	39	M	3
2	4	60	M	3
3	6	52	M	3
4	4	75	M	3
5	5	65	M	2
6	12	56	M	1
7	4	56	F	2
8	2	72	M	0
9	10	75	M	0
10	3	64	M	0
11	10	43	F	2
12	5	42	M	2
13	4	77	F	0
14	10	68	M	0

perature. The sections were washed in water, counterstained with Mayer's haematoxylin for one minute at room temperature, dehydrated, cleared, and mounted. Sections of all 14 inverted papillomas where the primary antiserum was omitted served as negative controls.

Staining of p53 was scored using a standard light microscope ($\times 400$). The percentage of

p53 positive cases was determined by counting 500 cells and the cases were divided into four categories as follows: 0 = <10% of tumour cells positive; 1 = 10% to <30% positive; 2 = 30% to 50% positive; and 3 = >50% positive.

Results

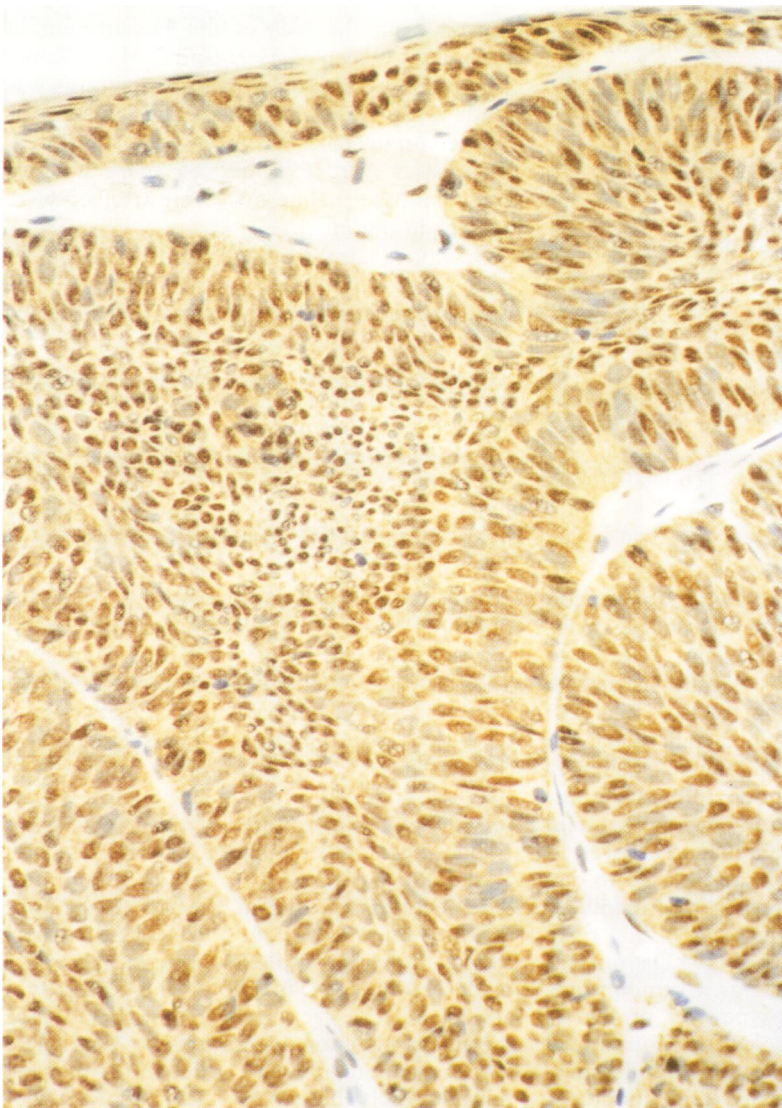
Fourteen inverted papillomas of the urinary bladder were studied. Eleven were from men and three from women (table). The mean age of the patients was 60.3 years (range 39 to 77 years). Three of the inverted papillomas (cases 2, 9 and 11) were initially reported as papillary carcinoma, either grade I or II. All 14 patients underwent complete transurethral resection of the tumour. Recurrent disease has not been documented in any of these 14 cases. Follow up ranged from nine to 102 months (mean 46 months). One patient (case 7) was diagnosed with carcinoma of cervix one year after her tumour of the bladder was detected and underwent total hysterectomy and post-operative radiotherapy. She was also receiving chemotherapy for acute promyelocytic leukaemia.

p53 immunoreactivity was observed in the nuclei, but not in the cytoplasm, of the tumour cells (figure). Less than 10% of stromal cells were p53 positive. The table lists the size of the papillomas, age and sex of the patients and p53 scores. Tumour size ranged from 2 to 12 mm. Staining of p53 protein was scored as follows: 3 in four cases; 2 in four cases; 1 in one case; and 0 in five cases. Overall, nine (64%) of 14 cases were positive for p53 protein.

Discussion

Inverted papilloma of the urothelium may be mistaken for papillary transitional cell carcinoma.⁹⁻¹² Of the 14 inverted papillomas studied here, three had been diagnosed as carcinoma. However, there was no evidence of these tumours behaving in a clinically aggressive manner and there were no metastasis or recurrence after complete transurethral resection. This underscores the fact that, on histological examination, differential diagnosis of inverted papilloma and carcinoma is not always easy. Other methods—for example, flow cytometry to determine DNA ploidy, may help in the differential diagnosis.¹²

About half of all cases of cancer are associated with mutant p53 protein. Some premalignant lesions—for example, colorectal adenomas, also show nuclear accumulation of p53 protein in up to 42% of cases.¹³ Benign lesions are seldom investigated for their p53 status. Pignatelli *et al*¹³ did not detect specific staining for p53 in the four normal large bowel mucosal and the five colorectal metaplastic polyps they examined. Other studies have shown that accumulation of p53 protein is common in transitional cell carcinoma,¹⁻⁴ and carcinoma in situ and dysplasia¹⁴ of the urinary bladder. The reported incidence varies from 20 to 71% depending on the tumour stage. To the best of our knowledge, the p53 status in benign tumours of the urinary bladder has not been reported previously. Our results show that ac-



p53 nuclear positivity in an inverted transitional cell papilloma of the urinary bladder ($\times 300$; case 1; p53 score = 3).

cumulation of p53 protein is prevalent in inverted papillomas of the urinary bladder, with an incidence comparable with that in bladder carcinomas. This simple investigation, however, cannot be used to differentiate this benign tumour from carcinoma. The results reported here are in accordance with the supposition that the p53 gene is mainly concerned in the control of cellular proliferation⁵ and it has little or no direct effect on tumour invasiveness and metastasis. Other studies, however, have shown that accumulation of p53 in bladder cancers is highly associated with tumour grade and stage,¹² and with recurrence and death, and thus may be useful in determining prognosis.^{14 15}

Gene mutation is not solely responsible for accumulation of p53. Interaction with viral proteins^{5 6} and possibly cellular proteins¹⁶ can lead to stabilisation of the wild-type protein, allowing it to be detected by immunohistochemistry. Overexpression may also result from inducer activity following genotoxic damage.¹⁷ A prospective study on fresh tumour tissue is warranted to identify the exact mechanism responsible for the accumulation of p53 in individual cases.

In conclusion, accumulation of the p53 protein was common in inverted papillomas of the urinary bladder, but cannot be used as a marker of malignancy.

This study is supported by a research grant (CRCG 335/046/0048) of The University of Hong Kong.

1 Moch H, Sauter G, Moore D, Mihatsch MJ, Gudat F, Waldman F. p53 and erbB-2 protein overexpression are associated with early invasion and metastasis in bladder cancer. *Virchows Arch A Pathol Anat Histopathol* 1993;423:329-34.

- 2 Esrig D, Spruck CH, Nichols PW, Chaiwun B, Strwen K, Groshen S, *et al.* P53 nuclear protein accumulation correlates with mutations in the p53 gene, tumor grade, and stage in bladder cancer. *Am J Pathol* 1993;143:1389-97.
- 3 Mellon K, Wilkinson S, Vickers J, Robinson MC, Shenton BK, Neal DE. Abnormalities in p53 and DNA content in transitional cell carcinoma of the bladder. *Br J Urol* 1994;73:522-5.
- 4 Schmitz-Drager BJ, van-Roeyen CR, Grimm MO, Gerhartz CD, Decken K, Schulz WA, *et al.* P53 accumulation in precursor lesions and early stages of bladder cancer. *World J Urol* 1994;12:79-83.
- 5 Levine AJ, Momand J, Finlay CA. The p53 tumour suppressor gene. *Nature* 1991;351:453-6.
- 6 Lane DP, Benchimol S. p53: oncogene or anti-oncogene? *Genes Dev* 1990;4:1-8.
- 7 Hall PA, Lane DP. Editorial. p53 in tumour pathology: can we trust immunohistochemistry?—revisited! *J Pathol* 1994;172:1-4.
- 8 Tenaud C, Negoescu A, Labat-Moleur F, Legros Y, Soussi T, Brambilla E. p53 immunolabeling in archival paraffin-embedded tissues: Optimal protocol based on microwave heating for eight antibodies on lung carcinomas. *Mod Pathol* 1994;7:853-9.
- 9 Talbert ML, Young RH. Carcinomas of the urinary bladder with deceptively benign-appearing foci. A report of three cases. *Am J Surg Pathol* 1989;13:374-81.
- 10 Mulkens TH, Vereycken HA, Van-Nueten JC, Govaerts GC, De Schepper AM, Van Camp KO, *et al.* Bilateral ureteral inverted papillomas in association with bladder carcinoma: a case report and review of the literature. *Urol Radiol* 1990;12:154-6.
- 11 Grainger R, Gikas PW, Grossman HB. Urothelial carcinoma occurring within an inverted papilloma of the ureter. *J Urol* 1990;143:802-4.
- 12 Kunimi K, Uchibayashi T, Egawa M. A case of inverted papilloma of the ureter: Is the DNA ploidy pattern associated with occurrence of transitional cell carcinoma of the bladder? *Int Urol Nephrol* 1994;26:17-22.
- 13 Pignatelli M, Stamp GWH, Kafiri G, Lane D, Bodmer WF. Overexpression of p53 nuclear oncoprotein in colorectal adenomas. *Int J Cancer* 1992;50:683-8.
- 14 Sarkis AS, Dalbagni G, Cordon Cardo C, Melamed J, Zhang ZF, Sheinfeld SC, *et al.* Association of p53 nuclear overexpression and tumor progression in carcinoma in situ of the bladder. *J Urol* 1994;152:388-92.
- 15 Esrig D, Elamajian D, Groshen S, Freeman JA, Stein JP, Chen SC, *et al.* Accumulation of nuclear p53 and tumor progression in bladder cancer. *N Engl J Med* 1994;331:1259-64.
- 16 Barnes DM, Hanby Am, Gillett CE, Mohammed S, Hodgson S, Bobrow LG, *et al.* Abnormal expression of wild type p53 protein in normal cells of a cancer family patient. *Lancet* 1992;340:259-63.
- 17 Hall PA, McKee PH, Menage HD, Dover R, Lane DP. High levels of p53 protein in UV irradiated normal human skin. *Oncogene* 1993;8:203-7.