

A woman with persistent vaginal bleeding after suction evacuation of the uterus

WK Ng, ANY Cheung, KL Liu, WC Leung, S Lee, MT Chau, LC Wong

Presentation of case

Dr Leung*: The patient was a 43-year-old housewife who was initially admitted to the Queen Elizabeth Hospital on 6 December 1996 because of persistent vaginal bleeding, following suction evacuation of the uterus. The operation was performed at the end of November 1996 in mainland China for a missed abortion at around 6 weeks' gestation. She gave a poor obstetric history (Gravida 9, Para 3, Abortus 6); she had had five spontaneous abortions, an ectopic pregnancy and a subsequent right salpingectomy, and two preterm stillbirths. In 1987, she had a full-term, normal, spontaneous vaginal delivery, and gave birth to a baby girl that weighed 3 kg and had mild mental retardation.

Dr Liu†: May I ask the medical students if they have any questions about her history?

Student: Firstly, the patient was 43 years old which is an advanced maternal age—the chance of having an abnormal pregnancy is high. Her first trimester abortion could have been due to a chromosomal abnormality in the foetus. Secondly, she had had five spontaneous abortions in the past, so the chance of a subsequent spontaneous abortion was high. She also gave a past history of an ectopic pregnancy. So, we would like to ask about her menstrual history, if any pregnancy test had been done, and if any subsequent investigations were performed to rule out the possibility of another ectopic pregnancy.

Dr Liu: Well, Dr Leung is going to give you the diagnosis.

This submission was from the Queen Mary Hospital, The University of Hong Kong, Pokfulam, Hong Kong

Correspondence to: Dr WK Ng, Department of Pathology, Pamela Youde Nethersole Eastern Hospital, 3 Lok Man Road, Chai Wan, Hong Kong

Dr WK Ng was the coordinator and main author; he was not one of the discussants

*†Department of Obstetrics and Gynaecology

Dr Leung: The patient had an antenatal check-up in mainland China and the pregnancy was confirmed at about 6 weeks' gestation. Previously, she was having regular, 28-day menstrual cycles. An ultrasonographic examination was performed in mainland China and revealed a missed abortion. Suction evacuation was thus performed. After admission to the Queen Elizabeth Hospital, because of persistent vaginal bleeding, suction evacuation was also performed since the preliminary diagnosis was "retained gestational products". Pathological examination of the evacuate showed the presence of a hydatidiform mole. The human chorionic gonadotropin (hCG) level remained high and stationary, in the range of 10^5 to 10^6 IU/L. As a result, the patient was referred to the Queen Mary Hospital at the end of December 1996 for the management of the gestational trophoblastic disease. A physical examination given at that time showed that her general condition was stable. Examinations of the chest, heart and abdomen gave results which were within the normal limits. The uterus was enlarged to the size of 8 weeks' gestation and there was no adnexal mass.

Investigations and differential diagnosis

Dr Liu: What types of investigation would you perform on such a patient?

Student: I would perform an ultrasonographic examination of the uterus to look for any vesicles or abnormalities. I would also monitor the serum hCG level. Because some hydatidiform moles may metastasize to distant organs such as the lungs and the brain, I would do a chest X-ray and a lumbar puncture to measure the hCG level in the cerebrospinal fluid. The general condition of the patient should also be assessed. Therefore, routine investigations including a complete blood picture, a clotting profile, and liver and renal function tests should be performed.

Dr Liu: Dr Leung is going to tell us what we had done.

Dr Leung: As suggested, the following investigations were performed: determination of the serum hCG level and the complete blood picture, liver and renal function tests, thyroid function test, blood grouping, determination of the clotting profile, chest X-ray, computerised tomography of the lungs, ultrasonographic examination of the liver and pelvis, hepatic and pelvic arteriography, and measurement of the hCG level in the cerebrospinal fluid.

Dr Liu: Dr Lee is going to explain why we did all these investigations.

Dr Lee[‡]: There is a whole list of investigations that we can order. However, we do not order all of them for all patients. We do some of them in all patients and we do all of them in some patients. For all patients, we would do a complete blood picture, liver and renal function tests, a determination of the serum hCG to monitor the disease, a chest X-ray to look for pulmonary metastasis, and blood grouping so as to have some blood in reserve. For some patients who have persistent trophoblastic disease after suction evacuation of the uterus, we may need to further look for metastasis, and possibly consider starting chemotherapy. In these patients, we would do a thyroid function test, a clotting profile, hepatic and pelvic arteriography, and ultrasonography of the liver and pelvis. We would also measure the hCG level in the cerebrospinal fluid, and assay for the presence of the hepatitis B surface antigen in the serum. Computerised tomography of the lungs and brain would be optional.

Dr Liu: Dr Leung is going to tell us what the results of these investigations were.

Dr Leung: The chest X-ray was normal and there was no evidence of pulmonary metastasis. The ultrasound examination of the pelvis revealed a heterogeneous echogenic lesion of dimensions 2.7 x 6.5 x 6.9 cm in the uterus, and an increased Doppler flow. Both ovaries appeared unremarkable. The ultrasound examination of the liver revealed an echogenic lesion of dimensions 3.6 x 2.9 x 2.3 cm at the right lobe, which possibly indicated metastasis. The pelvic and hepatic arteriograms revealed an enlarged uterus with abnormal vascularity, and a vascular lesion of 5 cm diameter at the right lobe of liver. The differential diagnosis lay between haemangioma and metastatic focus. Computerised tomography of the lungs and liver showed fine nodular opacities of 0.2 to 0.3

cm in diameter at the upper lobe of right lung, suggestive of lung secondaries. A hypodense lesion of 4 cm diameter was seen in the right lobe of liver, which again suggested a differential diagnosis between haemangioma and metastasis.

This patient belonged to the stage IV B category according to the International Federation of Gynecology and Obstetrics (FIGO) system.¹ She was in the stage IV category because there was a suggestion of lung and liver metastases. The substage was B, as there was one risk factor present, namely the serum hCG level was more than 10⁵ IU/L. According to the World Health Organization (WHO) prognostic scoring system,¹ this patient also belonged to the high-risk group (scoring 12) since her age was over 39 years, the serum hCG level was greater than 10⁵ IU/L, her blood group was B, the size of the largest tumour was more than 5 cm in diameter, lung and liver metastases were likely, one to four metastases were identified, and there was no previous history of chemotherapy. The first course of chemotherapy was started on 4 January 1997. This was a regimen of multi-agent chemotherapy which included the use of hydroxyurea, vincristine, methotrexate, actinomycin D and cyclophosphamide (the CHAMOC regimen). The second course of CHAMOC was started on 25 January 1997.

Clinical progress and management

Dr Liu: Dr Lee is going to talk about the general management of gestational trophoblastic disease.

Dr Lee: The general management of patients with gestational trophoblastic disease begins with the evacuation of uterus by suction, i.e. aspiration. There is, however, a risk of excessive bleeding, so we must take precautions. The patient must have a wide-bore intravenous line set up with some blood reserved for transfusion, and oxytocin must be available. After suction evacuation, the patient needs regular follow-up by the serial monitoring of the serum hCG level. A percentage of patients requires chemotherapy: the percentage varies from centre to centre, depending on the selection criteria. The figure in our centre ranges from 10% to 20%. The patients are also required to use contraception for 1 year, so that a rise in serum hCG will not be due to pregnancy; this would otherwise confuse the picture of disease monitoring. In cases of persistent trophoblastic disease, we may need to, consider chemotherapy according to the FIGO staging and WHO prognostic scoring. Patients with a poor prognostic score may need more intensive chemotherapy in order to achieve remission. We have to

[‡]Department of Obstetrics and Gynaecology

decide whether to give single or multiple agents with reference to the prognostic score. The usual agents given include methotrexate, actinomycin D and etoposide.

Dr Liu: After the chemotherapy, how are you going to monitor the progress?

Student: We would monitor the serum hCG weekly in the first 2 months, twice weekly for about half a year, and then a monthly follow-up.

Dr Liu: Would Dr Leung like to tell us what happened in the present case?

Dr Leung: Although we had given two courses of chemotherapy to the patient, the serial hCG level remained stationary, in the range of 10^5 to 10^6 IU/L. Clinically, the uterus was enlarged to the size of about 14 weeks' gestation. An ultrasonogram of the pelvis showed that the uterus was enlarged and had multiple tiny anechoic cysts inside the endometrial cavity. An ultrasonographic examination of the liver revealed an echogenic lesion of 4.5 cm diameter in the right lobe, which suggested metastasis because of its enlargement. Magnetic resonance imaging was subsequently performed and showed a cavernous haemangioma of 3.6 cm diameter, but no evidence of metastatic lesion.

Dr Liu: Given all this information, what should be done next?

Student: This patient had persistent trophoblastic disease with a high prognostic score. The chance of resistance to chemotherapy was high. Therefore, besides giving multi-agent chemotherapy, we might need to consider surgical management, i.e. hysterectomy.

Dr Liu: What else should be done before hysterectomy?

Student: Perhaps we might need to change the chemotherapeutic agents first.

Dr Liu: Would Dr Leung tell us more please?

Dr Leung: In view of the persistent elevated serum hCG level, the poor response to multi-agent chemotherapy, the clinically enlarged uterus, and the presence of multiple echogenicities inside the endometrial cavity, suction evacuation was performed on 21 February 1997. A histological examination again showed the presence of a complete hydatidiform mole. The serum hCG level decreased initially after the

procedure but then remained stationary. The patient complained of increased vaginal bleeding. Clinically, the uterus was still enlarged to the size of about 10 weeks' gestation. We repeated an ultrasonographic examination of the pelvis and found a complex mass of 5 cm diameter at the left fundus of the uterus, and a focal increase in vascularity.

Dr Liu: What should be done next?

Student: Since this was a drug-resistant lesion, I would consider performing a hysterectomy.

Dr Leung: A total abdominal hysterectomy was indeed performed on 25 March 1997. During the operation, it was observed that the uterus was enlarged to the size of 12 weeks' gestation. The endometrial cavity was filled with necrotic material and there was a gross suggestion of myometrial invasion. The pathological examination revealed an invasive hydatidiform mole. The serum hCG level after the hysterectomy decreased satisfactorily. She was followed up in our clinic and her recent hCG level was less than 5 IU/L.

Dr Liu: Dr Lee is going to give you a summary of the management.

Dr Lee: In summary, she had suction evacuation performed on 9 December 1996 and a molar pregnancy was diagnosed. The serum hCG level was persistently elevated 4 weeks afterwards and there was persistent vaginal bleeding. So, I am sure you agree with me that chemotherapy was indicated. As her disease belonged to FIGO stage IV B and her WHO prognostic score was 12, multi-agent chemotherapy was needed. The hCG regression, however, was unsatisfactory after the drug treatment; usually, we would expect the serum hCG level to drop to about one tenth of the previous level after one course of chemotherapy. An ultrasound examination of the uterus indicated residual gestational trophoblastic disease. After another suction evacuation, the hCG level still remained high. We were left with two options: either changing the chemotherapeutic agents, or performing total abdominal hysterectomy. In this case, the latter was chosen because we were not certain whether or not further chemotherapy would have been useful. Moreover, the decision was partly the patient's request. Besides her poor obstetric history, she was already 43 years old; she would be 2 years older after completing the chemotherapy, and the subsequent post-treatment monitoring would last another year. The chance of having another normal pregnancy afterwards was therefore not high. In general,

surgery is indicated in patients with gestational trophoblastic disease who either have a drug-resistant tumour as in this case, an isolated secondary, or an emergency condition (e.g. hysterectomy to control uterine bleeding, or resection of bleeding tumour sites).

Radiological and pathological findings

Dr Liu: We now proceed to a radiological discussion by Dr Chau.

Dr Chau^{||}: An initial pelvic ultrasound examination showed multiple complex lesions (both solid and cystic in nature) inside the uterus; these were diagnostic of a molar pregnancy (Fig 1).² Colour Doppler sonography is useful in assessing the vascularity of gestational trophoblastic tissue. An invasive mole is usually vascular due to myometrial invasion. In contrast, a non-invasive mole is often avascular and cystic structures predominate. An ultrasonographic examination of her liver showed a well-defined echogenic mass in the right lobe. In general, the commonest cause for this kind of lesion in asymptomatic patients is haemangioma, but a liver secondary during gestational trophoblastic disease may also appear similar. Thus, ultrasonography alone cannot differentiate the two. The pelvic ultrasound after the suction evacuation revealed vesicular structures inside the uterus which extended close to the uterine surface—highly suggestive of extensive myometrial invasion. Special Doppler of the uterine

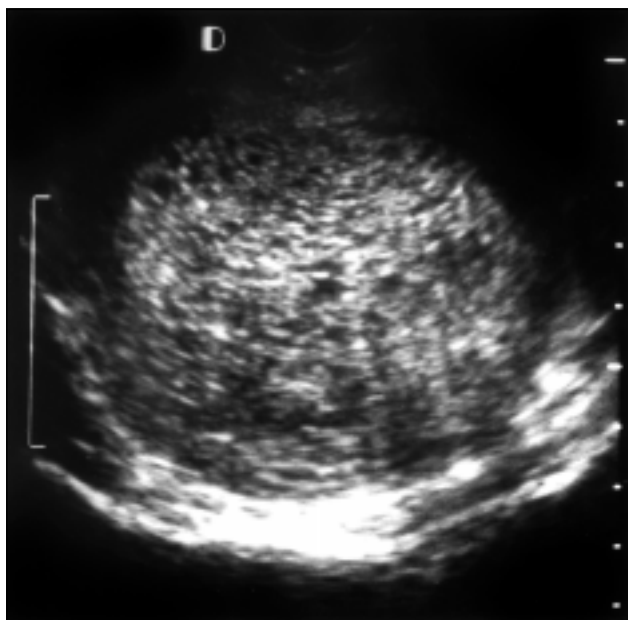


Fig 1. Pelvic ultrasonogram showing multiple complex lesions, both solid and cystic in nature, in the uterus

artery, which gives a quantitative measurement of the uterine flow, showed a markedly decreased pulsatility index (PI) value of 0.46, compared with a mean PI value of about 3 in the normal, non-gravid uterus.³ Our study showed that the mean PI value in gestational trophoblastic disease was 1.5. The decrease in the PI value, increase in diastolic flow and the disappearance of diastolic notch in this case suggested a highly active gestational trophoblastic disease in the uterus. Tumoural flow was also seen close to the uterine surface. The closer the trophoblastic tissue is to the uterine surface, the higher the risk of uterine rupture.

Dr Liu: Dr Cheung is going to discuss the pathological findings in this patient.

Dr Cheung[¶]: After the second suction evacuation, we received about 10 mL of vesicular structures admixed with blood clots. Histological examination showed the presence of a complete hydatidiform mole which was composed of abnormal, round hydropic villi with an obvious circumferential trophoblastic proliferation, and a prominent, central cistern formation (Fig 2). Foetal tissue was not identified. In contrast, for a partial mole, the degree of trophoblastic proliferation is usually less prominent, the abnormal villi are admixed with normal-sized villi, trophoblastic inclusions are more frequently present, and foetal red blood cells or even an embryo may be present. The hysterectomy specimen weighed 138 g and on sectioning, a polypoid necrotic tumour was found adhering to the uterine fundus (Figs 3 and 4): this had already been detected by ultrasound. There were also haemorrhagic nodules inside the myometrium, which were suggestive of invasion. The serosa of the uterus was, however, not perforated. A histological

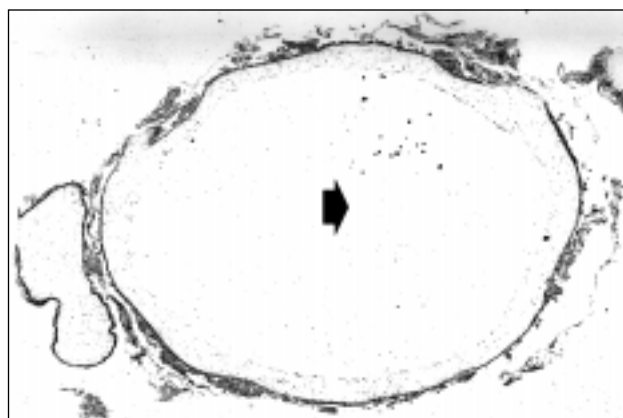


Fig 2. Histological examination of the uterine evacuate showing complete hydatidiform mole with circumferential trophoblastic proliferation and central cistern formation (arrow) [H&E, x 150]

^{||}Department of Diagnostic Radiology

[¶]Department of Pathology

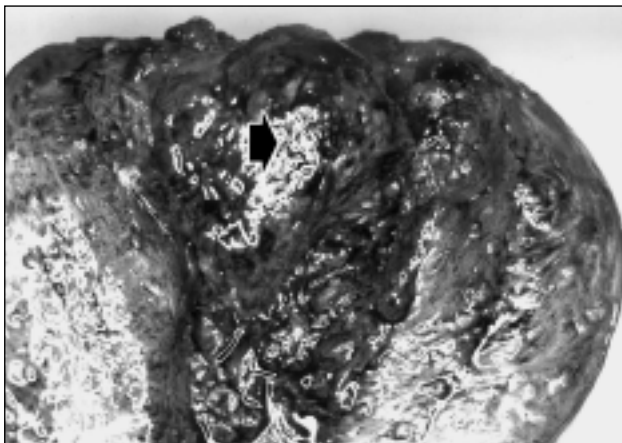


Fig 3. Gross picture of the hysterectomy specimen showing a polypoid necrotic tumour adhering to the uterine fundus. The specimen had been cut open anteriorly.

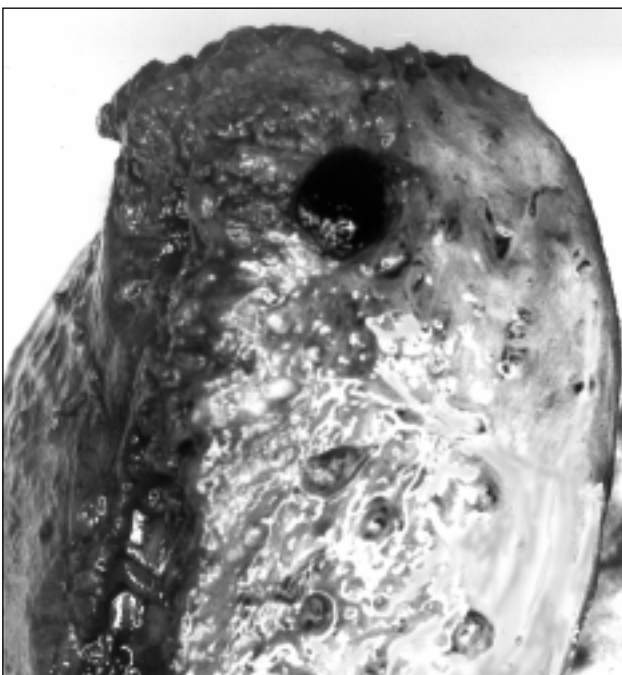

Fig 4. Side-view of myometrium showing the haemorrhagic focus of invasive mole

examination confirmed the presence of myometrial invasion by the abnormal villi which were admixed with fibrin, intermediate trophoblasts and blood (Fig 5). Because of this, the diagnosis of an invasive hydatidiform mole was made. Just to remind ourselves that ‘invasive hydatidiform mole’ is a pathological diagnosis which can be made only after studying a hysterectomy specimen.⁴

Dr Liu: Any comments from the floor?

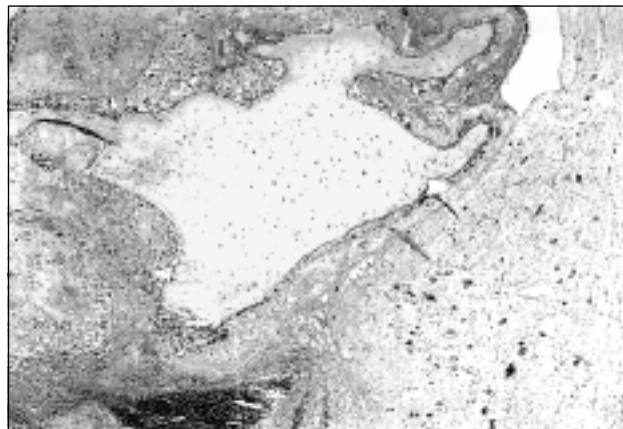


Fig 5. Histological examination of the uterus showing molar tissue invading into the myometrium (H&E, x 150)

Prof Wong[§]: This was not a typical case of an invasive mole. Most patients with an invasive mole belong to the low-risk group and respond well to chemotherapy. This case was atypical because right from the start, it was a very chemoresistant tumour. Besides, for patients with a heavy tumour load, it takes more than 3 months for the mole to regress. However, if there is a lot of molar tissue, chemotherapy may pose a danger of septicaemia, as the necrotic tissue following drug treatment may form a nidus for infection.

Anatomical diagnosis

Invasive hydatidiform mole

Acknowledgements

The authors would like to thank the other participants of the meeting.

References

1. Society of Gynecologic Oncologists. SGO handbook: staging of gynecologic malignancies. Chicago: Society of Gynecologic Oncologists, 1994.
2. Fleischer AC, James AE Jr, Krause DA, Millis JB. Sonographic patterns in trophoblastic diseases. Radiology 1978;126: 215-20.
3. Chan FY, Pun TC, Chau MT, Lam C, Ngan HY, Wong RL. The role of Doppler sonography in assessment of malignant trophoblastic disease. Eur J Obstet Gynecol Reprod Biol 1996;68:123-8.
4. Mazur MT, Kurman RJ. Gestational trophoblastic disease and related lesions. In: Kurman RJ, editor. Blaustein’s pathology of the female genital tract. New York: Springer-Verlag, 1994: 1049-96.

[§]Department of Obstetrics and Gynaecology