

## Sudden postpartum collapse

WK Ng, HSW Lam, RJW Lo, WN Tong, CP Lee, PKH Ho, P Dickens, ANY Cheung

### Presentation of case

Dr HSW Lam<sup>\*</sup>: The patient was a 32-year-old Filipino woman who was primigravida and had enjoyed good health in the past. She was a non-smoker and non-drinker and this was her first pregnancy. She had her first antenatal booking at the 15th week of gestation. An ultrasound examination at the 16th week showed a single intrauterine pregnancy with foetal pulsation. An ovarian cyst measuring 6 x 5 x 4 cm was found in the pouch of Douglas. No other abnormality was found. The antenatal course was complicated by an episode of preterm labour at the 31st week, which was successfully stopped using tocolytics. At the 39th week of gestation, she was admitted with fresh vaginal bleeding; no associated abdominal pain was present. A physical examination after admission showed her height and weight to measure 159 cm and 67 kg, respectively. Her blood pressure was 120/80 mmHg and her pulse rate was 80 beats per minute and regular. There was no pallor and her general condition was good. Abdominal examination showed a term-sized uterus which was soft and not irritable. A single foetus in cephalic presentation was found. The foetal head was not yet completely engaged. Speculum examination revealed a small amount of fresh blood at the cervical os with no active bleeding. Clinical diagnosis at that time was antenatal haemorrhage of unknown origin.

Combined induction of labour was performed the next day. After eight hours of syntocinon induction, sudden persistent foetal bradycardia was detected; heavy vaginal bleeding of approximately 150 ml was also noted. The cervix at that time was dilated 2 cm.

An emergency Caesarean section was performed because of the diagnosis of foetal distress and marginal placental separation. The operation was smooth and a female baby weighing 3.9 kg with Apgar score of eight at one minute and 10 at five minutes was delivered. The lower part of the placenta was found to have separated from the uterine lining, and no obvious retroplacental clot was noted; there was also evidence of pelvic endometriosis. Total blood loss during the operation was approximately 700 ml and the operation lasted for approximately 40 minutes. Postoperative blood pressure was 110/70 mmHg and her pulse rate was approximately 90 beats per minute. The patient was then transferred to the postnatal ward. However, two hours after the operation, she was found to have tachypnoea with unrecordable blood pressure. An emergency resuscitation was performed.

Dr CP Lee<sup>†</sup>: Would you like to show us the ECG recording showing the foetal bradycardia before the operation?

Dr Lam: The upper graph (Fig 1) is the foetal heart tracing which shows that the foetal heart rate was normal just prior to the time of foetal distress. The lower graph (Fig 1) shows the uterine contraction which was quite frequent and strong and occurred every two minutes. Because there was sudden persistent foetal distress, the patient was brought to the operating theatre for an emergency Caesarean section.

### Differential diagnosis

Dr Lee: What was the differential diagnosis at the time of collapse?

Dr Lam: For patients who collapse suddenly after delivery or operation, there are several possible differential diagnoses. The differential diagnosis of postpartum collapse can be divided into those with obstetrical and nonobstetrical causes. Obstetrical causes may include obstetrical haemorrhage, eclampsia, pulmonary thromboembolism, amniotic fluid embolism, uterine rupture, and uterine inversion.

This O&G pathology meeting is from the Queen Mary Hospital, The University of Hong Kong, Pokfulam, Hong Kong

\*,<sup>†</sup> Department of Obstetrics and Gynaecology

‡ Department of Anaesthesiology

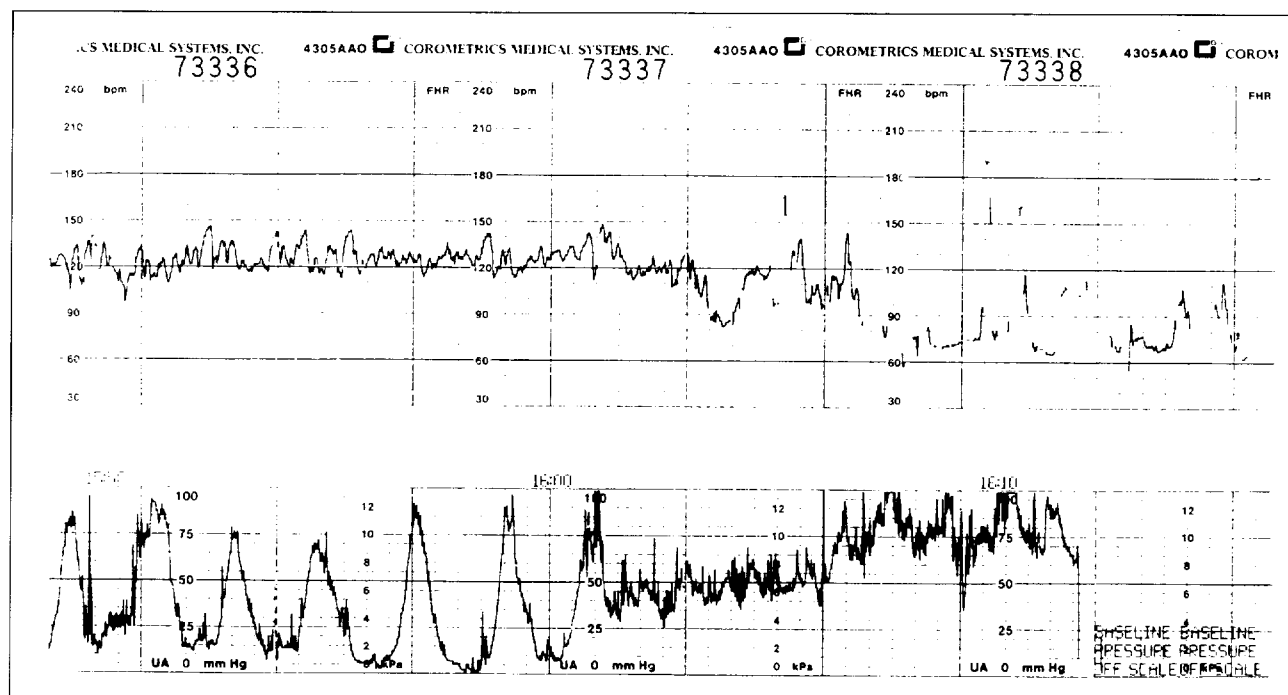
§ Department of Pathology

|| Department of Anaesthesiology

¶ Department of Obstetrics and Gynaecology

\*\* Department of Pathology

†† Department of Obstetrics and Gynaecology



**Fig 1. Tracings of foetal heart rate (upper graph) and uterine contraction (lower graph)**

Nonobstetrical causes may be due to anaesthetic toxicity, aspiration pneumonia, cardiac arrhythmia, or myocardial infarction—which is rare in a healthy woman. It may also be caused by a cerebrovascular accident or peritoneal haemorrhage due to a ruptured aneurysm such as a splenic artery aneurysm.

Dr Lee: Can our anaesthetist Dr Tong enlighten us as to the anaesthetic causes of postpartum collapse?

Dr WN Tong<sup>‡</sup>: Essentially, the patient had a sudden onset of respiratory distress two hours after undergoing a lower segment Caesarean section. Although the patient recovered rapidly after the Caesarean section, two hours later she experienced a sudden onset of respiratory distress which was associated with cyanosis and finally progressed to cardiac arrest. We need to know if there were any anaesthetic complications that may have been related. Let us go through the anaesthetic procedure first. The patient underwent general anaesthesia for Caesarean section. The premedication was 0.3 M sodium citrate, 30 ml orally, mainly acting as a prophylaxis against acid aspiration which is a common cause of anaesthetic mortality. After sodium citrate premedication, the patient received preoxygenisation. Cricoid pressure was applied in order to prevent aspiration. She then underwent rapid sequence induction with an intravenous injection of 250 mg thiopentone, followed by 100 mg suxamethonium. After induction, she was intubated with a size 7 endotracheal tube. Intermittent positive pressure ventilation (IPPV) was

carried out. Anaesthesia was maintained with nitrous oxide, oxygen, and enflurane. She was paralysed by 6 mg vecuronium. After delivery, she was given a dose of 50 mg intravenous pethidine for analgesia. The duration of operation was approximately 40 minutes. Total blood loss was approximately 700 ml which was replaced with 450 ml intravenous normal saline intraoperatively. After the operation, the neuromuscular blockade was reversed by 2.5 mg neostigmine and 1.2 mg atropine. She was extubated when fully awake and discharged from the recovery room after 35 minutes, with stable vital signs and good muscle power. She also received patient-controlled analgesia with intravenous pethidine for postoperative analgesia.

Following are the possible causes of her cardiac arrest. Since the patient presented with a sudden onset of respiratory distress complicated by cardiac arrest, the possibility of pulmonary embolism is likely. Pulmonary embolism may include thromboembolism, amniotic fluid embolism, or air embolism. Thromboembolism is not very likely because it usually occurs several days after the operation. Amniotic fluid embolism can occur during the operation or shortly afterwards. Hence, an amniotic fluid embolism is a likely possibility. There were no reasons for air embolism in this patient.

The second possible cause is aspiration pneumonitis. Although the patient had received 30 ml 0.3 M sodium citrate for acid aspiration prophylaxis,<sup>1</sup>

there could still have been a chance of aspiration pneumonitis because sodium citrate alone does not always raise the gastric pH above 2.5. As the duration of action of sodium citrate is approximately 30 minutes, she was still at risk of aspiration pneumonitis during extubation. Aspiration pneumonitis may present with respiratory distress, hypoxia, and pulmonary oedema. However, it usually has a more gradual clinical course. Because of the sudden onset of respiratory distress, aspiration as a cause is less likely. Also, for aspiration pneumonitis, bronchospasm is common; however, bronchospasm was not seen in this patient.

Anaphylaxis is also possible. Anaphylaxis or anaphylactoid reaction usually occurs immediately after the inoculation of foreign material and presents with rash, bronchospasm, and cardiovascular collapse. However, in this patient there was no rash or bronchospasm and the presentation was delayed. Hence, anaphylaxis is a less likely cause. Acute tension pneumothorax may complicate positive pressure ventilation and may lead to mediastinal compression and subsequent cardiovascular compromise. Patients with emphysema, lung cyst, or bulla may be particularly prone to pneumothorax after IPPV. Concerning residual neuromuscular blockade, the patient received a single dose of vecuronium—the action of which usually lasts for 30 to 45 minutes and the neuromuscular blockade was reversed with a normal dose of reversal agent. Her muscle power recovered adequately in the recovery room. Hence, it is unlikely that a residual effect occurred two hours after the operation. Since she was receiving patient-controlled analgesia, one may wonder whether she may have had an overdose of pethidine. However, the onset of drug overdose is usually more gradual and commonly presents with a reduction in respiratory rate or apnoea, sedation, and hypoxia, rather than respiratory distress.

Alternatively, sudden respiratory distress can be due to acute pulmonary oedema. Undiagnosed valvular heart disease is one such cause. She had no history of cardiac problems. Another possible cause is cerebrovascular accident which can be due to a ruptured berry aneurysm. During the operation, the berry aneurysm may rupture due to the stress of the operation and anaesthesia, particularly during intubation and extubation. However, there should be accompanying neurological symptoms such as headache and vomiting, and focal neurological signs should be found postoperatively. However, the patient was well in the immediate postoperative period and no neurological signs were detected. Cerebrovascular accident may

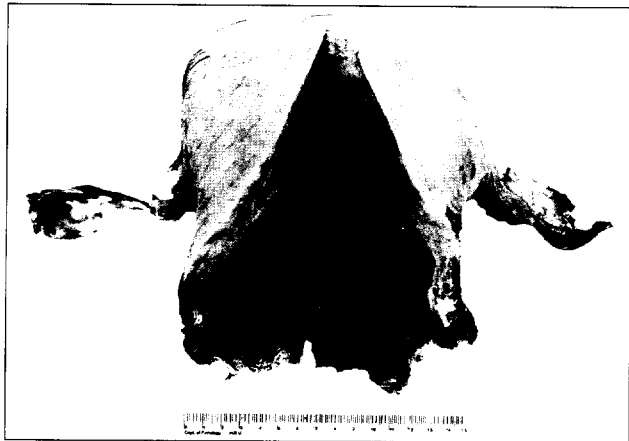
lead to cerebellar herniation with subsequent compression of the brain stem, which leads to apnoea instead of respiratory distress. Hence, this is not a likely cause. With postpartum haemorrhage, the patient may develop abdominal distension, but this usually does not cause many respiratory symptoms. From our experience, it is likely that there were some forms of embolism occurring in this patient, leading to cardiac arrest.

Dr Lam: The patient was actively resuscitated for two hours. Physical examination showed that the uterus was contracted and that there was no active bleeding or abdominal distension. The patient was finally certified dead two hours later.

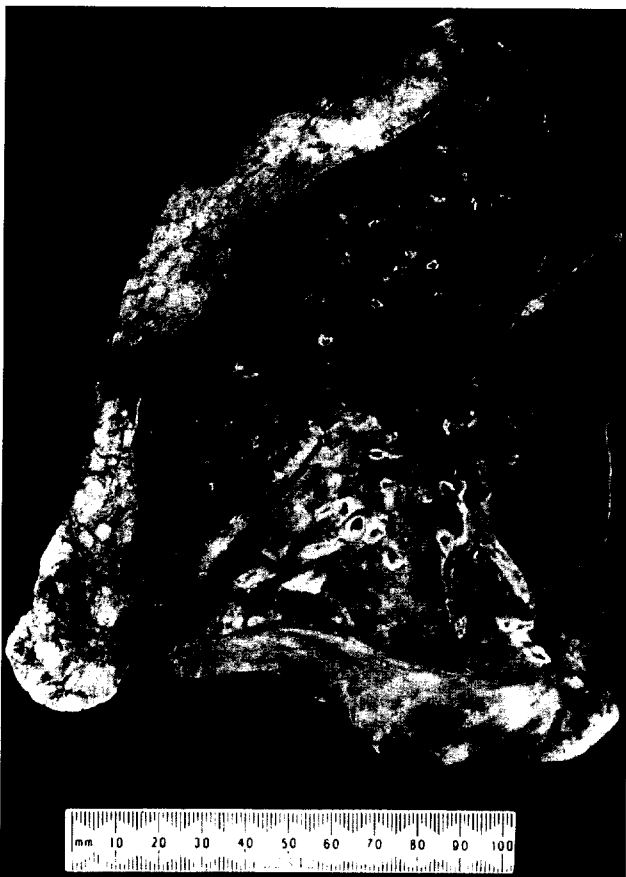### Postmortem findings

Dr Lee: A postmortem examination was performed. Would our pathologist Dr Ng tell us the postmortem findings?

Dr WK Ng<sup>8</sup>: The autopsy was performed four days after death. The main postmortem findings were in the respiratory system. The uterus was distended with approximately 150 ml of blood clots (Fig 2). There was no gross evidence of massive haemorrhage or uterine rupture. Histological sections taken from the uterus around the endometrial cavity showed decidual tissue with scattered trophoblasts, compatible with recent pregnancy. A high-power view of the uterine vessels showed a small amount of eosinophilic keratin squames present inside the vessel lumina. The left and right lungs weighed 370 g and 470 g, respectively, and showed no gross evidence of aspiration or consolidation (Fig 3). No pulmonary thromboembolism was found. There are two ways to look for air embolism during postmortem. Firstly, we can inspect the inferior vena cava for air bubbles before dissecting the venous system. Secondly, we can open the pericardial sac, infuse water into it, and cut the ventricles under water to see if any air bubbles come out or if there is an air-bubble studded blood clot in the ventricle. No evidence of air embolism was identified in this patient. However, keratin squames could be found inside some of the pulmonary vessel lumina (Fig 4). The finding of keratin squames inside the pulmonary vessels in a postmortem woman is consistent with amniotic fluid embolism.<sup>2</sup> A special stain can confirm the presence of keratin. This is Attwood's stain, which is a combination of alcian blue and phloxine tartrazine. Alcian blue stains up mucin as a bluish colour and phloxine tartrazine stains up keratin as a reddish colour. In summary, the cause of death in this patient was




**Fig 2. Gross appearance of the postmortem uterus. Note the absence of massive haemorrhage or uterine rupture.**



**Fig 3. Gross appearance of the postmortem lung. Note the absence of consolidation or congestion.**

amniotic fluid embolism. There was no evidence of massive haemorrhage, uterine rupture, or embolism.

Dr Lee: I would like to ask whether the presence of keratin squames inside pulmonary vessels is compatible with, or diagnostic of amniotic fluid embolism.



**Fig 4. Histological section of the lung showing the presence of keratin squames inside some of the pulmonary vessel lumina (arrow) (H & E, x 150)**

Dr Ng: It is diagnostic of amniotic fluid embolism.<sup>2</sup>

Dr Lee: Is it possible to find such keratin squames in a woman after a normal delivery without amniotic fluid embolism?

Dr Ng: No. The presence of keratin squames inside pulmonary vessels is considered diagnostic of amniotic fluid embolism. On the other hand, trophoblasts can be identified in pulmonary vessels after a normal pregnancy.

### **Pathophysiology and management**

Dr Lee: Can Dr. Lam tell us the possible risk factors for amniotic fluid embolism, and if they were present in this patient?

Dr Lam: There are several predisposing factors for amniotic fluid embolism. In this patient, the baby was quite big, weighing 3.9 kg. Also, the incidence of amniotic fluid embolism is higher in operative delivery; and in this patient, the baby was delivered by Caesarean section. There may be more chance of uterine vessel damage, thus increasing the possibility of amniotic fluid entering into the mother's systemic circulation. The patient underwent labour induction by syntocinon, which may also be a factor. However, amniotic fluid embolism is believed to be more common in multiparous women and in older mothers. Contrary to this, this was the patient's first pregnancy and she was still quite young.

Dr Lee: Would the pathologists comment on the mechanism of amniotic fluid embolism causing respiratory problems?

Dr Ng: The reason for the respiratory distress is not because of total mechanical occlusion of the pulmonary vessels by amniotic fluid components. Instead, their presence may induce acute vasoconstriction of the small pulmonary vessels. The mechanism by which acute vasoconstriction occurs is still unknown.

Dr Lee: Could Dr Lo tell us about the resuscitation of patients who have amniotic fluid embolism?

Dr RJW Lo<sup>1</sup>: There are not too many cases of amniotic fluid embolism worldwide. The foetus may still be undelivered when it occurs and the overall mortality is approximately 86%. Fifty per cent of patients with amniotic fluid embolism die within the first hour of onset of illness, mainly due to circulatory failure. Twenty-five per cent of deaths may be attributed to coagulopathy. The remainder are related to pulmonary complications. In terms of management of these patients, we have to understand the pathophysiology of this condition. The pathology is initiated by the entry of amniotic fluid and/or particulate gestational material into the maternal circulation. This can either directly or indirectly cause changes in the circulatory and respiratory systems. As already mentioned by our pathology colleague, there is an intense pulmonary vasoconstriction. There is also some degree of vascular obstruction. Both may lead to pulmonary hypertension and subsequently hypoxaemia, right heart strain, and eventually, to heart failure. Various direct and indirect mechanisms have been proposed to explain this vasoconstriction. The circulatory failure and the left heart failure that may ensue may result in secondary elevation of pulmonary pressure. The direct and indirect injury to the lung may eventually lead to adult respiratory distress syndrome and noncardiogenic pulmonary oedema with hypoxaemia. As mentioned before, coagulopathy may occur which is due to thromboplastic and fibrinolytic activities in the blood initiated by the amniotic fluid present in the circulation. Another factor that we need to consider is the anaphylactoid response to the amniotic fluid elements.

The treatment for amniotic fluid embolism is mainly supportive. The complications are circulatory, respiratory, and haematological. We have to support these organ systems in order to keep the patient alive. Firstly, cardiovascular support is needed with optimisation of the circulatory volume and close haemodynamic monitoring. We have to treat the heart failure with inotropic support. We also try to keep the pulmonary pressure low in order to decrease fluid leakage into the alveolar spaces and interstitium, thus minimising the pulmo-

nary oedema. The pulmonary capillary wedge pressure is able to show the pulmonary pressure and monitor the degree of pulmonary hypertension. Respiratory support aims to maintain oxygenisation, since most patients with respiratory distress present with hypoxaemia. The circulatory abnormality and adult respiratory distress syndrome give rise to hypoxaemia. The breathing mechanics may be altered by pulmonary oedema and changes in the lung parenchyma. Therefore, we have to support the breathing mechanics by airway pressure manoeuvres to maintain the functional residual capacity. Patients with severe pulmonary oedema may have collapsed alveoli. Continuous positive airway pressure ventilation may be used to distend and maintain aeration of the alveoli. If the breathing effort is inadequate, mechanical ventilation may be needed. Haematologically, one has to correct the coagulopathy with component therapy as appropriate. Cryoprecipitate (containing fibronectin) may be beneficial, but the mechanism is unknown. Careful heparin therapy may be used to control disseminated intravascular coagulation. The support of haematologists is very important before this therapy can be successful. This is a short summary of how we can manage such patients. Of course, initially, we have to provide basic life support, CPR, and so on.

Dr Lee: I have a question for Dr Lo. How can we optimise the circulatory volume in actual practice?

Dr Lo: If there is any instability in the circulation, one has to look at parameters such as left atrial pressure using a Swan-Ganz catheter, and central venous pressure. These are indicators as to how the circulatory system is performing. If the performance of the circulation is not satisfactory, we have to respond to the corresponding defects that the patient has. Hypovolaemia is reflected by low central venous pressure and low left atrial pressure. In this instance, one has to improve the circulation by giving more fluid. Hence, the adequacy of the fluid is important. Because of the ventricular dysfunction, the pressure itself may not be the sole criterion. We also need to monitor cardiac output. Because of the decreased compliance, the pressure may be high yet the fluid status may be poor.

Dr Lee: In these patients, because of pulmonary vascular constriction, would there be a high central venous pressure?

Dr Lo: Initially, yes. There would be a high central venous pressure, probably presenting as engorged neck veins. But as the condition progresses, the haemodynamic of the pulmonary vasculature

changes. There may be a loss of fluid into the lung parenchyma. Once the patient loses intravascular volume, the pressure may be normal. Hence, one has to be very careful about the pressure because there are so many factors affecting the pressure itself. If the central venous pressure is low, the heart is of course working against a very low preload. Then, you need to augment that.

Dr Lee: So, you think that the pulmonary artery wedge pressure is necessary for these patients?

Dr Lo: I think that the pulmonary artery wedge pressure is essential in the management, if the patients survive the initial resuscitation.

Dr GWK Tang<sup>!</sup>: Most of these patients die within the first hour before further management is possible. Suppose for this particular patient, you were at the scene, what would you advise us to do?

Dr Lo: Resuscitation is common for many types of embolisation. I think the main issue is functional obstruction of the pulmonary vasculature and pulmonary resistance is very high. Hence, this is the key issue we have to address when we resuscitate such patients. This is similar to thromboembolism where the pulmonary resistance is high, as some parts of the circulation are obstructed. In amniotic fluid embolism, most parts of the pulmonary circulation are intensely vasoconstricted, leading to a high pulmonary resistance. The effect on the right ventricle is not different. Apart from the basic life support, such as maintaining the ventilation, we have to maintain the cardiac output. The patients often have right heart failure, whether there is thromboembolism or amniotic fluid embolism. Right heart failure will reduce the cardiac output. Once we make the clinical diagnosis, we should commence inotropic therapy. Pulmonary vascular resistance must also be reduced. The simplest and most commonly used drug for this purpose is adrenaline. There has been some suggestion that isoprenaline is better because of the lack of vasoconstrictive property. Hence, these are the two drugs that you must consider using early on in order to treat the right heart failure and also to dilate the pulmonary vasculature.

## Discussion

Dr ANY Cheung<sup>\*\*</sup>: As we have previously had a patient with 'amniotic fluid embolism' who survived, I would like to know the criteria for the diagnosis of amniotic fluid embolism in that case.

Dr Lee: I think Dr Ho was the surgeon at that time. Could he comment on that?

Dr PKH Ho<sup>††</sup>: For that particular patient, I do not think that there was any pathological diagnosis. Basically, it was a clinical diagnosis. That patient had certain risk factors for amniotic fluid embolism, as already mentioned by Dr Lam. She also had polyhydramnios and a big baby. She had an elective Caesarean section for these reasons. There was no excessive blood loss during the operation. However, after delivery of the baby, she suddenly collapsed, with no recordable blood pressure and hypoxaemia.

Dr Lee: I think that patient subsequently developed coagulopathy.

Dr Ho: Yes. That patient was subsequently transferred to Queen Mary Hospital for further management. The coagulopathy was relatively mild. The circulation was not that poorly controlled. Presumably, the amount of embolism had been small and the clinical outcome was favourable. In contrast, in the present case, the amount of embolism may have been bigger, so the clinical outcome was less favourable. I also want to mention tension pneumothorax. Firstly, many patients can develop pneumothorax spontaneously. Secondly, the patients have had positive pressure ventilation. This is another risk factor. They may also present as central venous congestion, dyspnoea, and abnormal gas exchange. This should always be borne in mind when resuscitating these patients.

Dr Tong: For the patient who survived the embolism, the diagnosis was made intraoperatively. We routinely monitor the end-tidal carbon dioxide concentration during the operation. For patients who have some form of embolism, the first sign is that the end-tidal carbon dioxide drops (because of a sudden increase in physiological dead space), followed by hypertension and hypoxia. So, at that moment, the clinical diagnosis would be pulmonary embolism, either amniotic fluid or air embolism. For those patients who have finally got a pulmonary artery catheter inserted, we can actually get some pulmonary capillary blood for cytology.<sup>3,4</sup> The pathologists may be able to find some foetal squames in the specimen for confirmation of the diagnosis. I would like to ask the pathologists' opinion about this pulmonary capillary blood cytology.

Dr Cheung: Over the past decade, there have been occasional reports about taking central venous blood

for cytology in order to make the diagnosis of amniotic fluid embolism in a live patient. Others have tried to screen for squamous cells in blood aspirated from the right heart or pulmonary artery of both pregnant and non-pregnant female patients who have undergone pulmonary arterial catheterisation for other medical indications.<sup>5,6</sup> The presence of squamous cells was documented in all cases. Their presence in the pulmonary circulation is possibly due to contamination from sites of venous access. Consequently, there is still controversy as to whether the presence of keratin squames in the central venous blood is reliable for the diagnosis. The diagnosis is, of course, more straightforward in postmortem cases. Even in such postmortem cases, the most important point is adequate sampling of the lungs. For example, in this case, approximately 30 blocks were taken from the lungs before we could demonstrate squames in the pulmonary circulation. I have also encountered two cases of amniotic fluid embolism, as suggested by the clinical picture of coagulopathy and shock. Emergency hysterectomy was done and the patients survived. We found keratin squames and foetal hair inside the veins of the cervix.<sup>7</sup> If a hysterectomy is performed, it is worthwhile to examine the cervical veins thoroughly. Also, it supports the theory about how amniotic fluid enters the systemic circulation. In these patients, there was no actual rupture of the uterus. It is believed that the amniotic fluid may go through the veins in the myometrium or the endocervix, especially when the baby crowns, which results in cervical compression. The amniotic fluid is then pushed into the dilated or even mildly lacerated endocervical veins.

Dr Lee: For hysterectomy specimens, say, from women with postpartum haemorrhage, is it possible to find these hair and squames in the cervical veins?

Dr Cheung: I think this is the sort of study that we should do but have not carried out. I have reviewed the literature and could not find any relevant study. It is worthwhile to look for squames in postpartum patients with hysterectomy done for other purposes such as carcinoma of the cervix.

Dr Tong: In recent years, there has been some suggestion that the clinical syndrome may be related to the content of amniotic fluid introduced. Some patients may be asymptomatic while others may have severe symptoms. What is the pathologists' view on this?

Dr Cheung: As mentioned by Dr Ng, the consensus is that the most reliable criterion for a diagnosis of amniotic fluid embolism is the identification of squames in the pulmonary vasculature. But it is very difficult to correlate the volume of amniotic fluid embolised with the survival rate. That is why I am interested to know how, in the survivors, the diagnosis of amniotic fluid embolism was made. Possibly, we need more of these cases before we can introduce other diagnostic criteria.

### **Anatomical diagnosis:**

#### *Amniotic fluid embolism*

### **Acknowledgement**

We thank the other participants of the discussion.

### **References**

1. Gillet GB, Watson JD, Langford RM. Ranitidine and single-dose antacid therapy as prophylaxis against acid aspiration syndrome in obstetric practice. *Anaesthesia* 1984;39:638-44.
2. Fox H. Pathology of maternal death. In: Fox H, editor. *Obstetrical and gynaecological pathology*. New York: Churchill Livingstone, 1987:1324-5.
3. Masson RG, Ruggieri J. Pulmonary microvascular cytology: a new diagnostic application of the pulmonary artery catheter. *Chest* 1985;88:908-14.
4. Masson RG, Ruggieri J, Siddiqui MM. Amniotic fluid embolism: definitive diagnosis in a survivor. *Am Rev Respir Dis* 1979;120:187-92.
5. Clark SL, Pavlova Z, Geenspoon J, Horenstein J, Phelan JP. Squamous cells in the maternal pulmonary circulation. *Am J Obstet Gynecol* 1986;154:104-6.
6. Giampaolo C, Schneider V, Kowalski BH, Bellaver LA. The cytologic diagnosis of amniotic fluid embolism: a critical reappraisal. *Diagn Cytopathol* 1987;3:126-8.
7. Cheung AN, Luk SC. The importance of extensive sampling and examination of cervix in suspected cases of amniotic fluid embolism. *Arch Gynecol Obstet* 1994;255:101-5.

HKMJ 1995;1:341-347