

Microvascular free flaps for reconstruction

W. Y. Ip and S. P. Chow

Abstract

The development of microvascular free flaps has significantly affected our reconstructive principles. In many situations, it has become the procedure of choice. Thus, defects caused by trauma, tumour resection, infection and irradiation or related to congenital anomalies can be adequately covered by microvascular free flaps. Free flaps have also evolved from skin to tissues such as muscle, bone, toes, and other composite flaps, and the factors affecting their choice include patient's needs, defect characteristics, donor site morbidity, and surgeon's experience. Recent advances in surgical techniques, thrombolytic drugs for flap salvage, prefabrication technique, synergistic use of tissue expander and osteogenesis by callus distraction will contribute to the future development of microvascular free flap.

Keywords: Microvascular; Free flap; Reconstruction

Introduction

Since John Wood¹ managed the severe burn deformity of forearm and hand with the first groin flap in a 8-year old girl in 1863, the concept of reconstructive surgery has been evolving all the time. The introduction of microvascular free flap in the past 25 years has profoundly affected our reconstructive principles and in many instances has influenced some well established aspects of wound care, tumour resectibility and salvage of mutilated parts.

After the first successful free groin flap by Daniel in 1968,² microvascular free flap³ has gradually evolved from being a procedure of last resort to become a first choice reconstructive procedure. For instances, defects caused by trauma,⁴ tumour resection, infection, irradiation or related to congenital anomalies is traditionally covered by skin grafts, local flaps or distant pedicle flaps. Microvascular free flap has gradually added to our options⁵ of wound coverage. With improvement in their survival rates, attention has been directed to cosmesis and functional results also. In the past 25 years, many different tissues have been successfully transferred employing microvascular technique. This has advanced from single tissue to composite tissues. The following clas-

sification⁶ gives an overview of the free flaps used nowadays (Table 1).

Indications for microvascular free flap

First of all, the surgeon should have mastered the various reconstructive procedures which range from simple skin graft to local flaps, distant pedicle flaps, and then to free flaps.

Free flap reconstruction is indicated when the result of traditional procedures is expected to be less satisfactory. For instance, a defect exposing raw bone, cartilage or tendon cannot revascularize a skin graft. A local flap should be considered next. A local flap has the advantage of providing skin coverage with similar tissue texture and where the donor site can be closed, not leaving an extensive scar. Local flap, however, is limited in size and availability of tissue. It also inflicts additional injury on a traumatized limb. A distant pedicle flap can bring in more tissue but has the disadvantages of uncomfortable positioning, joint stiffness and may have inseting as well as contour problems. When successfully insetted, it is still a parasite that seeks nutrition from the underlying scarred bed. Therefore, a free flap becomes another option.

A free flap has its own pedicle and brings new blood supply to the relatively avascular beds. It is available in virtually any size and thickness and can be designed to fit the defect with precision. It also permits elevation of the limb and early mobilization.

Department of Orthopaedic Surgery, The University of Hong Kong, Queen Mary Hospital, Pokfulam, Hong Kong

W. Y. Ip, FRCS(Edin)

S. P. Chow, MS, FRCSE(Edin)

Correspondence to: Dr W. Y. Ip

Table 1. Classification of free flap

1. Single free tissue transfer
a. Free flap
i. Free cutaneous flap — a free flap consisting of skin and subcutaneous tissue supplied by a direct cutaneous artery.
ii. Free fasciocutaneous flap — a free flap consisting of fascia, subcutaneous tissue and skin supplied by septocutaneous perforator.
iii. Free myocutaneous flap — a free flap consisting of skin, subcutaneous tissue and muscle with the latter serving as a non-functional unit to protect the essential musculocutaneous arteries
b. Free bone transfer
c. Free muscle transfer
d. Free nerve transfer
e. Free fascia transfer
f. Free intestine transfer
g. Free periosteum transfer
2. Composite free tissue transfer
a. Free osteocutaneous transfer — incorporation of bone to provide skeletal replacement and skin to restore skin coverage in a single unified free tissue transfer.
b. Free musculocutaneous transfer — incorporation of muscle as a functional unit to provide motor function and skin to restore skin coverage
c. Free neurovascular flap
d. Free toe to hand transfer
e. Other composite flap, may include bone, muscle tendon nerve, toe wrap etc.

Contraindication

Free flap is contraindicated when a patient has high anaesthetic risks or has insufficient residual functions such as those caused by poor sensation and stiff joints. Age,^{7, 8} however, is not a limiting factor as recent study shows that the flap survival rate of the aged is similar to that of the young. However, most tissues are less tolerant to prolonged ischaemia with increasing age. Diabetes mellitus,⁹ a disease with microangiopathic change, may be a contraindication. However, in animal studies, moderate ischaemic challenges do not compromise free flap survival and thus its transfer.

Choice of free flap^{10, 11}

Factors affecting the choice of flaps include:

1. Size, thickness, and requirements of the recipient bed.
2. Skill and experience of the surgeon and his team.
3. Patient acceptability of donor site deformity.

Numerous flaps have been designed for free flap

transfer, but only the more versatile and dependable ones have stood the test of time. Flaps with good pedicle length, easy accessibility, and flexibility in design gradually become popular. The following are some commonly used ones:

*Groin flap*¹²

It is a skin flap supplied by the superficial circumflex iliac artery as the axial blood supply. There is also communication between the deep and the superficial circumflex iliac vessels which adds to the viability of the flap and supports flap size up to 20 x 30 cm². It is also possible to incorporate part of the iliac crest bone. There is minimal donor site morbidity (Fig. 1). However, it gradually loses its popularity because of the relative short vascular pedicle and the vessels are rather small for anastomosis. The skin flap usually is too thick and does not allow good skin match for limb reconstruction.

*Chinese flap (radial forearm flap)*¹³

It is a fasciocutaneous flap supplied by perforators from the radial artery. It is easy to harvest, has a long pedicle, and provides a large area of skin for transfer. Vascularized nerve, tendon and bone can be included to form a composite flap. However, the donor site closure is a problem and skin graft may be required. Only when a small piece of skin is transferred, then the donor site can be closed primarily.

*Dorsalis pedis flap*¹⁴

This skin flap is in the first toe web space based on the first dorsal metatarsal artery. It is extremely thin and can be a sensate flap with two point discrimination of 10 to 15 mm. The metatarsal bone or extensor tendons can be included. Its size, however, is restricted to 10 x

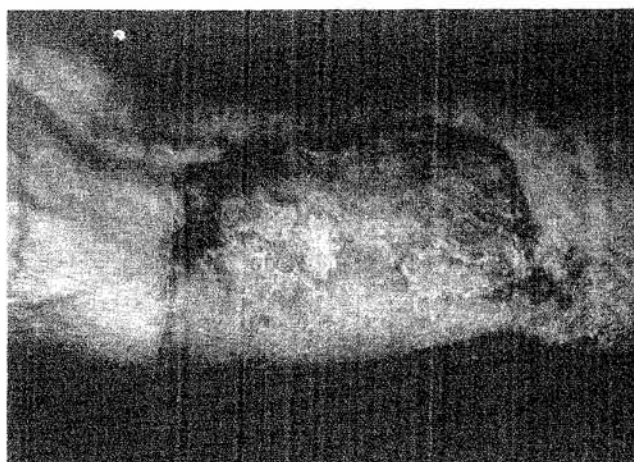


Fig. 1. Free groin flap.

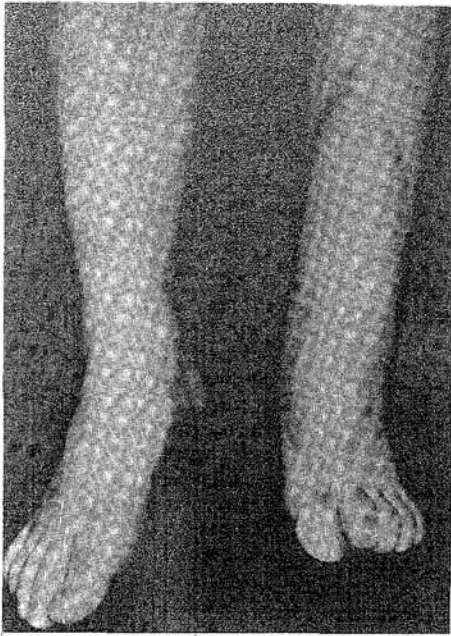


Fig. 2 Latissimus dorsi free flap for coverage of anterior shin wound.

10 cm² and there is significant donor site morbidity. This flap is most suitable for resurfacing the hand.

Latissimus dorsi flap

This myocutaneous flap is supplied by the thoracodorsal artery. A big skin island of 30 x 40 cm² can be harvested. Its pedicle is 8 to 10 cm long and the vessel size 2.5 mm in diameter. Smaller flap can also be designed employing the segmental technique. Its drawbacks include its thickness and conspicuous donor site scar. When it is used to cover extremity wounds, defatting may be required later (Figs. 2 and 3). It is the flap of choice to cover large defects.

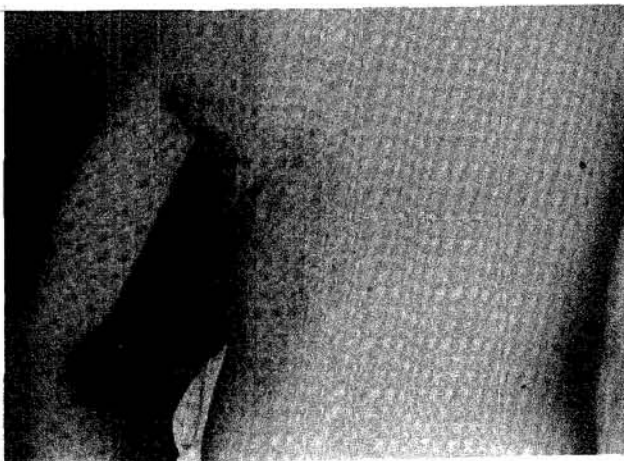


Fig. 3 Latissimus dorsi free flap for coverage of anterior shin wound. Donor site: the scar is conspicuous but there is no functional loss.

*Lateral arm flap*¹⁵

This fasciocutaneous flap is based on the posterior radial collateral branch of the profunda brachii artery. Its pedicle length is 8 to 11 cm and the flap size can go up to 5 x 19 cm². Bone, tendon and nerve can be incorporated to form a composite flap (Fig. 4). Its disadvantage is again related to donor site closure problem and a conspicuous scar usually results.

Gracilis muscle flap

It can be used as a functional muscle transfer. The motor nerve to the gracilis muscle is sutured to the recipient nerve which supplies the affected muscle for functional restoration. Other muscle frequently used as free muscle transfer include the pectoralis minor, extensor digitorum brevis, serratus anterior and latissimus dorsi.

Other composite flaps

The 'wrap around flap' which consists of the soft tissue of the great toe, with digital nerve and vessel pedicle wrapping around a piece of iliac crest graft, has been used to reconstruct thumbs with success (Fig. 5).

Complications¹⁶

Early complications include both arterial and venous thrombosis at the anastomatic site. Most failure occurs within the first 24 hours but can occur up to 10 days. The most common cause of failure when free flaps are transferred to traumatic extremities or irradiated areas is the inadvertent use of a damaged recipient artery. It is better to resect the diseased portion of the artery and insert a vein graft rather than to join the flap vessel to a compromised artery.

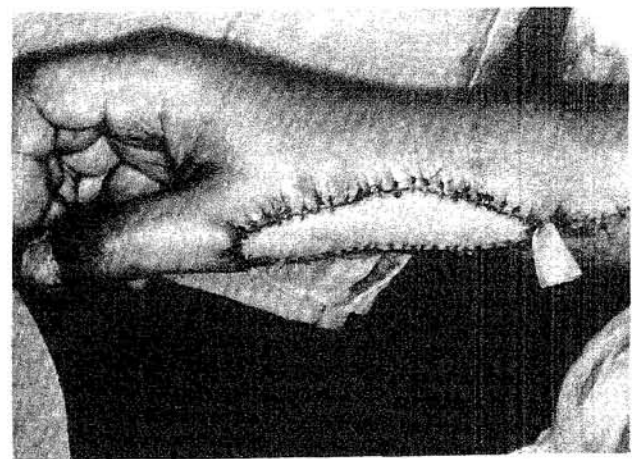


Fig. 4. Lateral arm flap for coverage of forearm defect.

The inappropriate design and choice of flap may result in insufficient defect coverage and inadequate replacement of damaged tissue. A poorly designed free flap will not fulfil the purpose of functional restoration and good cosmesis.

Donor site morbidity may be significant. If the tissue harvested is excessive, then donor wound closure may not be possible and secondary reconstruction of donor site by skin grafting is required. Motor weakness, fracture, sensory deficit may result if synergistic muscle is deficient, or when too large a portion of bone is harvested or when a sensory nerve is divided. Flap with minimal donor site morbidity should always be chosen (Table 2).

The future

Advances in surgical technique would improve flap survival. Vascular anastomatic rings¹⁷ may replace micro-sutures because of its simplicity, convenience and safety. Surgeons with little training can complete microvascular anastomosis and operation time can be reduced. In animal models, laser assisted microvascular anastomosis¹⁸ appears to be an alternative to conventional suture anastomosis.

Flap salvage by thrombolysis¹⁹ with local infusion of tissue plasminogen activator²⁰ or vasodilator calcitonin gene-related peptide has been shown to be promising in animal studies.

Prefabrication²¹⁻²⁴ provides a means to create donor tissues and are not limited by the natural vascular territories. Methods of prefabrication include implantation of greater omentum, blood vessels or muscle flap to the tissue as a carrier. An alternative method is

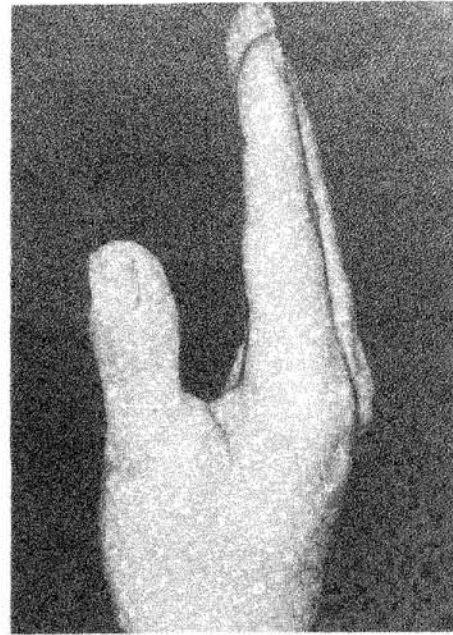


Fig. 5. Wrap around flap for thumb reconstruction.

to create an arteriovenous shunt, which will produce sufficient neovascularization to support a free flap.

Tissue expanders^{25, 26} has been used as an adjuvant to microvascular free flap. The expanded free flaps are large and thin, having a capsule which enables them to be safely sutured under tension. It is particularly useful in children.²⁷

For substitution of extensive bony defects, composite flap with bone has been used with good result. A promising alternative is osteogenesis produced by callus distraction.²⁸

Conclusion

Microvascular free flap has become a routine, safe procedure in reconstructive surgery. With advancement in surgical technique and optimal choice of free flaps, operation time and hospital stay would be further reduced.

References

1. Khoo BC, Wood J. The first groin flap. *Br J Plast Surg* 1977; 30: 9-13.
2. Daniel RK. Mandibular reconstruction with free tissue transfers. *Ann Plast Surg* 1978; 1: 346-71.
3. Khouri RH. Free flap surgery. The second decade. *Clin Plast Surg* 1992; 19: 757-61.
4. Piza H, Rath T, Hausmaniger, Walza RL. Wound closure at the trunk by microvascular free flap transfer. *Microsurgery* 1993; 14: 260-5.
5. Reigstrad A, Hetland KR, Bye K, Rokkum M. Free flaps in the reconstruction of hand and distal forearm injuries. *J Hand Surg (Br)* 1992; 17: 185-8.

Table 2. Advantages and disadvantages

Advantages of free flap:

1. Single operation, reducing the number of surgical procedures, anaesthetic risk and duration of hospitalization.
2. Greater patient comfort with simple positioning.
3. Early mobilisation of injured part.
4. Introduction of vascularized tissue with permanent blood supply resulting in faster wound healing.
5. Optional inclusion of a vascularized bone graft, functional muscle and tendon or potential innervation and composite flap for precise matching of defect.
6. 1 closure of donor site in most cases.

Disadvantages:

1. Difficult, tedious and long operation.
2. Vascular difficulties during operation.
3. Post-operative vascular complication resulting in flap failure.
4. Donor site morbidity.

6. Daniel RK, May JW. Free flaps : an overview. *Clin Orthop* 1978; 133: 122-31.
7. Cooley BC, Gould JS. Influence of age on free flap tolerance to ischaemia: an experimental study in rats. *Ann Plast Surg* 1993; 30: 57-9.
8. Bonawitz SC, Schnarrs RH, Rosenthal AI, Rogers GK, Neuton ED. Free tissue transfer in elderly patients. *Plast Reconstr Surg* 1991; 87: 1074-9.
9. Colley BC, Hanel DP, Lan M, Li X, Gould JS. The influence of diabetes on free flap transfer: the effect of ischaemia on flap survival. *Ann Plast Surg* 1992; 21: 65-9.
10. Chen SH, Wei FC, Chen HC, Chuang CC, Noordhoff MS. Emergency free flap transfer for reconstruction of acute complex extremity wound. *Plast Reconstr Surg* 1992; 89: 882-8.
11. Arnez ZM. Immediate reconstruction of the lower extremity — an update. *Clin Plast Surg* 1991; 18: 449-57.
12. Chuang DC, Jeng SF, Chiu HT, Chen HC, Wei FC. Experience of 73 free groin flaps. *Br J Plast Surg* 1992; 45: 81-5.
13. Bardsley AF, Sautar PS, Elliot D, Batchelor AG. Reducing morbidity in the radial forearm flap donor site. *Plast Reconstr Surg* 1990; 86: 287-92.
14. Inigo F, Gargollo C. Secondary coverage of the hand using a dorsalis pedis plus first web space free flap. *J Reconstr Microsurg* 1992; 8: 461-5.
15. Wenig BL. The lateral arm free flap for head and neck reconstruction. *Otolaryngol Head Neck Surg* 1993; 109: 116-9.
16. Hallock GG. Complications of the free-flap donor site from a community hospital perspective. *J Reconstr Microsurg* 1991; 7: 331-4.
17. Gang Z, Ling YC, Qun Q. Experience using microvascular anastomotic rings for the transplantation of 20 free flaps. *Plast Reconstr Surg* 1989; 84: 822-6.
18. Wenig BL. A comparison of suture versus laser-assisted microvascular anastomosis (LAMA) in the pig buttock flap model. *Laryngoscope* 1993; 103: 1002-12.
19. Fudem GM, Walton RL. Microvascular thrombolysis to salvage a free flap using human recombinant tissue plasminogen activator. *J Reconstr Microsurg* 1989; 5: 231-4.
20. Romano JE, Biel MA. Maintaining long-term vessel patency in microvascular surgery using tissue-type plasminogen activator. *Otolaryngol Head Neck Surg* 1991; 105: 391-5.
21. Earle AS, Feng LJ, Jordan RB. Lone saphenous vein graft as an aid to microsurgical reconstruction of the trunk. *J Reconstr Microsurg* 1990; 6: 165-9.
22. Takato T, Zuker RM, Turley CB. Prefabrication of skin flaps using vein grafts: an experimental study in rabbits. *Br J Plast Surg* 1991; 44: 593-8.
23. Schmidt A, Hernde E, Muhlbauer W. Increasing the vascular pedicle length in a free flap using a 2-stage preliminary ectopic transfer. *Ann Plast Surg* 1991; 27: 97-102.
24. Ozbek MR, Kutlu N, Khouri RK, Gultan SM, Yormuk E. Prefabricated microvascular shoulder free flap for forehead reconstruction. *Handchir Mikrochir Plast Chir* 1993; 25: 139-43.
25. Mayou BJ, Gault DT, Crock JG. Tissue expanded free flap. *Br J Plast Surg* 1992; 45: 413-7.
26. DeHaan MR, Hammond DC, Mann RJ. Controlled tissue expansion of a groin flap for upper extremity reconstruction. *Plast Reconstr Surg* 1990; 86: 979-82.
27. Moghari A, Emami A, Sheen R, O'Brien M. Lower limb reconstruction in children using expanded free flaps. *Br J Plast Surg* 1989; 42: 649-52.
28. Fleischmann W, Sugar G, Kiuzl L. Treatment of bone and soft tissue defects in infected nonunion. *Acta Orthop Belg* 1992; 58 (suppl): 227-35.