

## Progressive shoulder arthropathy

W C G Peh, K M C Cheung

### Clinical history

An 84 year old Chinese woman presented with a one year history of increasingly severe right shoulder pain, associated with joint stiffness. There were no symptoms related to the rest of the upper limb or neck. On examination, a soft tissue mass was palpable over the anterior aspect of the right shoulder. The mass measured about 6 cm in diameter, was generally ill-defined, soft in consistency, non-tender and cold to touch. Right shoulder movements were severely restricted in all directions because of severe pain. The other peripheral joints had satisfactory ranges of motion. Her general condition was otherwise satisfactory, with no other systemic abnormality evident.

Department of  
Diagnostic Radiology,  
The University of  
Hong Kong,  
Queen Mary Hospital,  
Hong Kong  
W C G Peh

Department of  
Orthopaedic Surgery  
K M C Cheung

Correspondence to:  
Dr Wilfred C G Peh,  
Department of  
Diagnostic Radiology,  
The University of  
Hong Kong,  
Queen Mary Hospital,  
Hong Kong.

\*Department of  
Diagnostic Imaging,  
The Robert Jones and Agnes  
Hunt Orthopaedic Hospital,  
Oswestry,  
Shropshire SY10 7AG,  
United Kingdom.

Accepted for publication  
17 November 1994

### Imaging findings and clinical course

Plain radiograph of the right shoulder showed patchy periarticular osteoporosis. There was a lytic area in the lower humeral head, suggestive of a large erosion or cyst. Small bony densities were present in the soft tissues just inferior to the glenohumeral joint (fig 1). As the initial working diagnosis was osteoarthritis of the shoulder, the patient was managed with physiotherapy and mobilisation. Aspiration was not performed at this time. No steroids were administered. However, her shoulder pain became progressively worse despite this conservative treatment. Repeat radiograph two months later demonstrated further destructive

changes of the humeral head, with involvement of the bony glenoid. There was increase in the amount of bony debris surrounding the shoulder joint (fig 2). Her erythrocyte sedimentation rate was increased (115 mm/1st h). Computed tomography (CT) confirmed destruction of the articulating surfaces of the glenohumeral joint, with erosions of the adjacent humeral head and lateral scapula. Multiple bony fragments were present within the joint space. The deltoid and subscapularis muscles were enlarged and swollen. They contained hypodense areas which showed peripheral ring like enhancement after contrast injection. The space within the remnant glenohumeral joint was occupied by similarly enhancing soft tissue and fluid (fig 3).

### Differential diagnosis

Until proven otherwise, any monoarticular lesion should be regarded to be of infective origin and investigated appropriately. Causes of monoarthritis such as trauma, gout and other crystal induced arthritis, and rheumatoid arthritis (rare) could be excluded on the basis of the clinical features, particularly with lack of systemic involvement. Osteoporosis is mild or absent in gout. In calcium pyrophosphate deposition disease (CPPD), there is degenerative rather than active destruction of the joint, and articular cartilage calcification may be seen. Apatite associated joint destruction, also known as the Milwaukee shoulder, produces glenohumeral changes similar to those of CPPD and additionally occurs in combination with complete rotator cuff tear, which may give rise to proximal humeral head migration. Diagnosis of both CPPD and apatite associated arthritis depends upon analysis of aspirated synovial fluid.

Besides typically having a bilateral and symmetrical distribution, rheumatoid arthritis manifests with early and significant joint space loss. Radiographic features of osteoarthritis are joint space narrowing, subchondral sclerosis and osteophytes. Synovial osteochondromatosis characteristically produces calcified loose bodies and well defined pressure erosions on plain radiographs, while in pigmented villonodular synovitis there is absence of osteoporosis, joint space preservation, and intra-articular nodular soft tissue causing extrinsic bony erosions on radiography and CT.

An atrophic type of neuropathic (or Charcot) joint may present with a large,

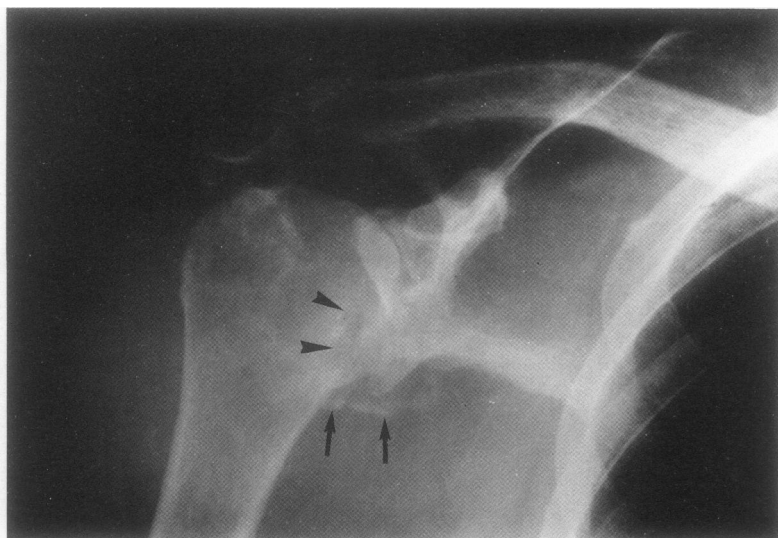


Figure 1 Right shoulder radiograph shows a lytic area in the humeral head (arrowheads). Joint space is preserved, with collection of bony densities inferior to the joint (arrows). There is patchy periarticular osteoporosis.

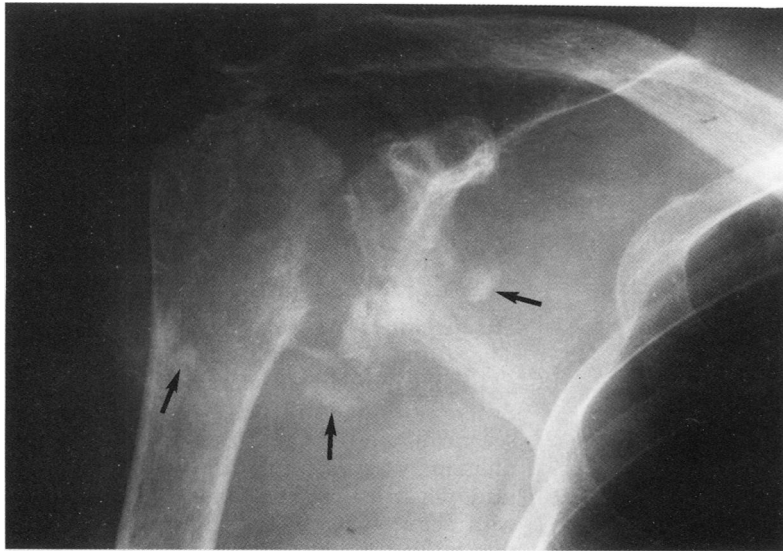


Figure 2 Repeat radiograph after two months shows marked destruction of the articulating humeral head and glenoid fossa. The amount of intra-articular debris has increased (arrows).

clinically 'cool' effusion and rapid development of instability. However, in the shoulder, neuroarthropathy is almost always indicative of underlying syringomyelia. Radiographically,

fragmentation and resorption resulting in destruction are often confined to the humeral head, with sparing of the glenoid. There is usually no associated osteopenia or articular erosion. In osteonecrosis, careful clinical assessment is required to elicit a possible predisposing cause. While poorly defined increased density or 'snowcapping' of the humeral head may be encountered, features such as subchondral lucencies, meniscus sign, humeral head collapse and joint destruction occur less frequently, compared with the hip joint. Although the clinical and radiographic features could fit those of a synovioma, the CT findings did not support this diagnosis.

Progressive destructive joint changes make septic arthritis the most likely diagnosis, particularly with CT demonstration of intramuscular abscesses and intra-articular inflammatory mass and effusion. The lack of both local inflammatory signs and systemic toxicity, despite the florid imaging abnormalities, is against a pyogenic organism as the cause of septic arthritis. Moreover, pyogenic arthritis typically results in early joint space loss and preservation of bone density before bony destruction. The table summarises principal causes of destructive large joint monoarthritis.

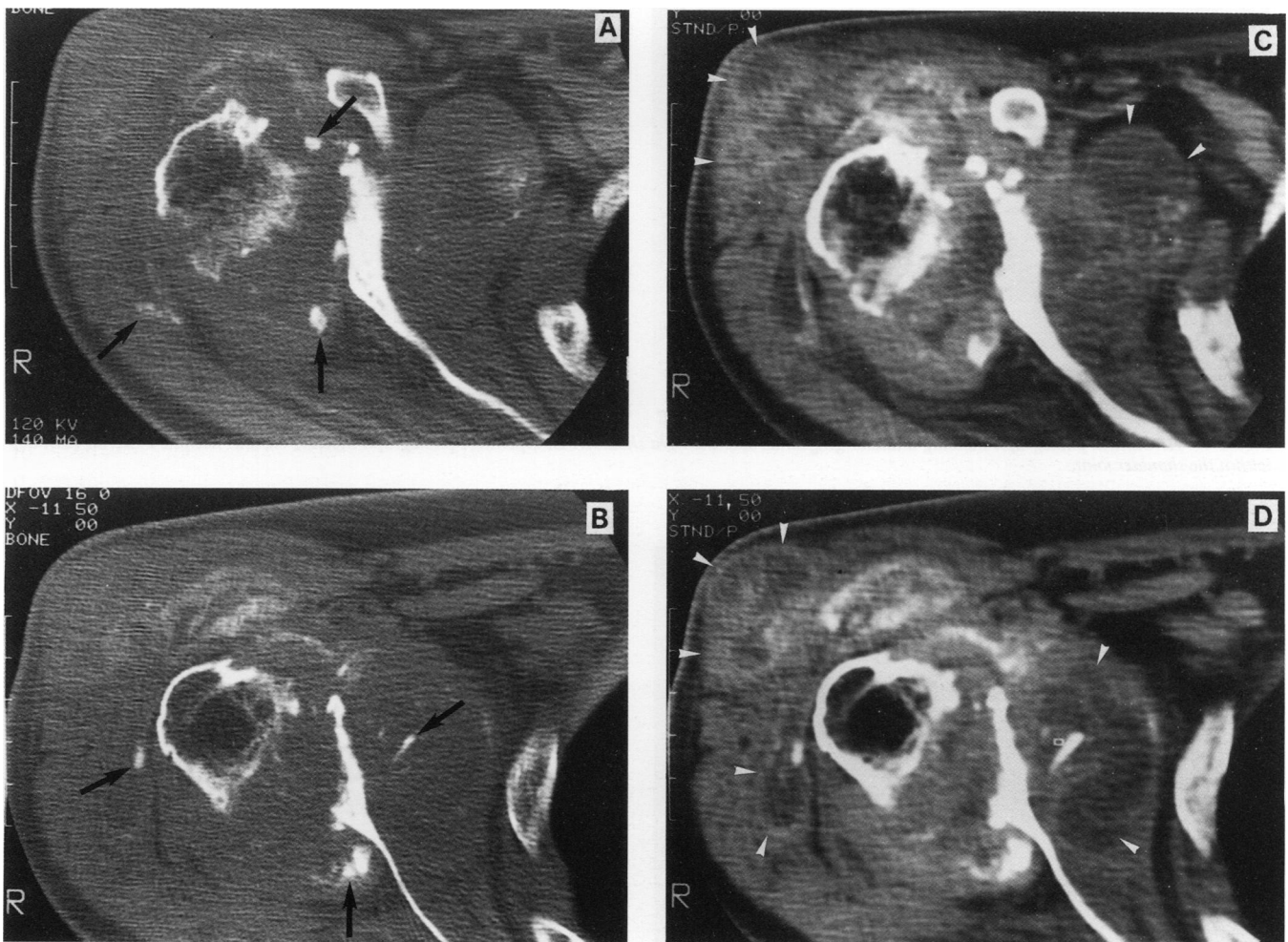


Figure 3 Axial CT images (bone window), at the levels of (A) the base of the coracoid process and (B) the mid-glenoid fossa, show marked destruction of the glenohumeral joint with multiple small bony fragments (arrows). Enhanced CT images (soft tissue window) at corresponding levels (C and D), show multiple ring shaped enhancing lesions within the swollen deltoid and subscapularis muscles (arrowheads). An inflammatory mass is seen in the glenohumeral joint.

*Principal causes of progressive destructive large joint monoarthritis*

1. Septic arthritis
  - (a) Tuberculosis
  - (b) Pyogenic
2. Apatite associated destructive arthritis (or Milwaukee shoulder)
3. Calcium pyrophosphate deposition disease
4. Synovioma
5. Atrophic neuropathic (or Charcot) joint
6. Osteonecrosis ( $\pm$  pre-existing osteoarthritis)
7. Gout (rare)
8. Rheumatoid arthritis (rare)

### Diagnosis

The diagnosis was tuberculous arthritis.

Aspiration of the right shoulder joint yielded blood stained fluid, culture of which subsequently grew *Mycobacterium tuberculosis*. The patient was started on antituberculosis therapy consisting of isoniazid, pyrazinamide, ofloxacin and ethambutol. However, the patient developed a persistent discharging sinus over the antero-lateral aspect of the right shoulder (fig 4A). At operation, this was found to communicate with an abscess within the deltoid muscle and with the shoulder joint, which contained greyish caseous necrotic material (fig 4B). Excision of the sinus tract and abscess drainage was performed. Magnetic resonance imaging (MRI)

subsequently demonstrated that the deltoid muscle abscesses had largely resolved but there remained active inflammatory tissue within the shoulder joint and subdeltoid space (fig 5). The patient continued to receive anti-tuberculous drugs for a total of six months. At last follow up, eight months after presentation, she had regained a moderate range of right shoulder motion.

### Discussion

The incidence of bone and joint tuberculosis (TB) in the United Kingdom and North America is low and has been declining for several decades.<sup>1,2</sup> Compared with other extra-pulmonary sites, articular involvement is rare, occurring in fewer than 1% of patients with active tuberculosis.<sup>3</sup> Since the onset of the human immunodeficiency virus (HIV) epidemic, there has been much interest and concern over possible TB-HIV interaction.<sup>4</sup> There is evidence to suggest that up to 30% of people with previous TB, if infected with HIV, will develop active disease as a result of reactivation of latent infection.<sup>5</sup>

Tuberculous arthritis is a potentially disabling condition which, if untreated, may lead to complete destruction of the joint. Delay

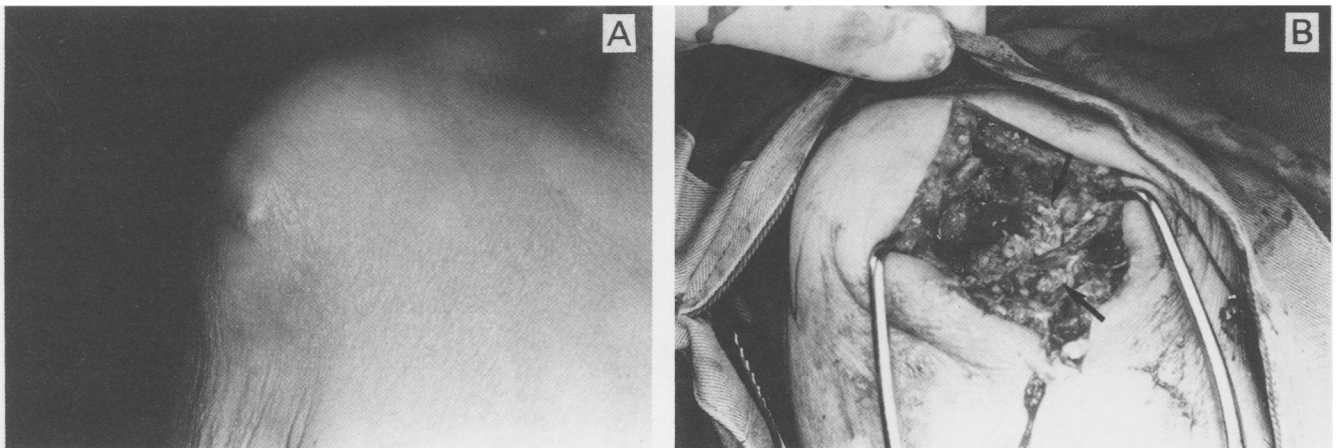


Figure 4 A: Clinical photograph showing a discharging sinus over the right shoulder. B: Operative photograph showing caseous necrotic material (arrows) within the shoulder joint.

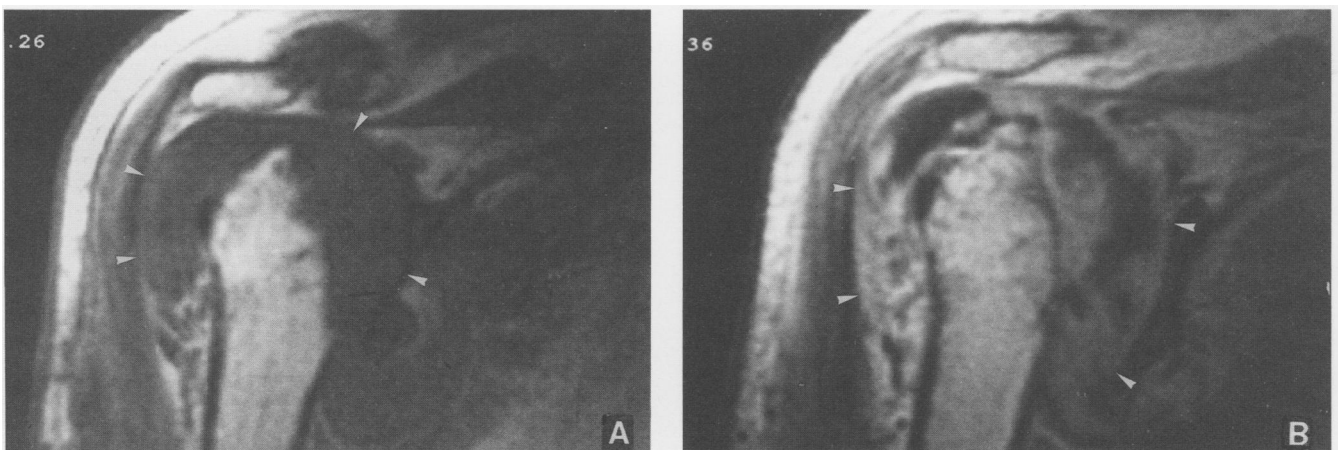


Figure 5 Coronal MRI through the mid-remnant humeral head. A: T1 weighted image showing that the glenohumeral and subdeltoid spaces contain a largely isointense mass (arrowheads), with small hypointense areas within. B: Post-gadolinium DTPA T1 weighted image showing marked contrast enhancement, mainly located peripherally, indicating active inflammatory tissue (arrowheads).

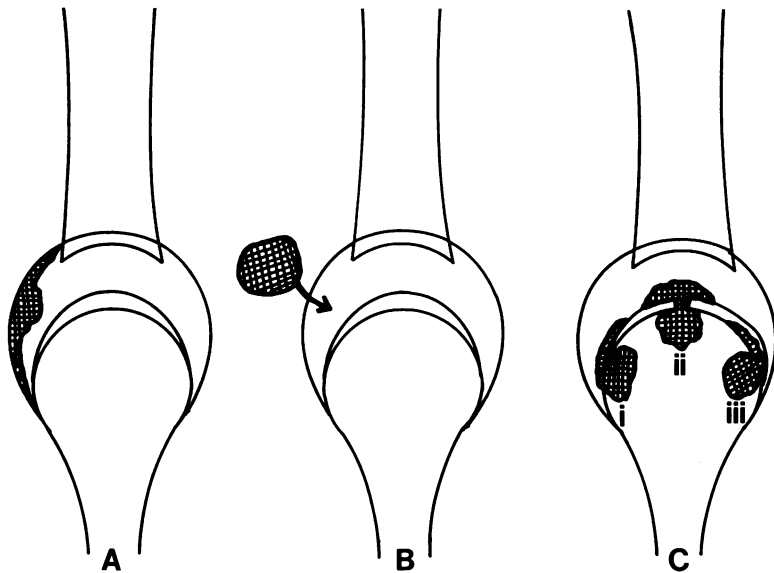


Figure 6 Mechanism and routes of tuberculous arthritis. A: Primary involvement of synovium. B: Fistula from adjacent organ or soft tissue. C: Spread from osteomyelitic focus: i = cartilage surface spread; ii = mushrooming through cartilage; iii = subchondral spread.

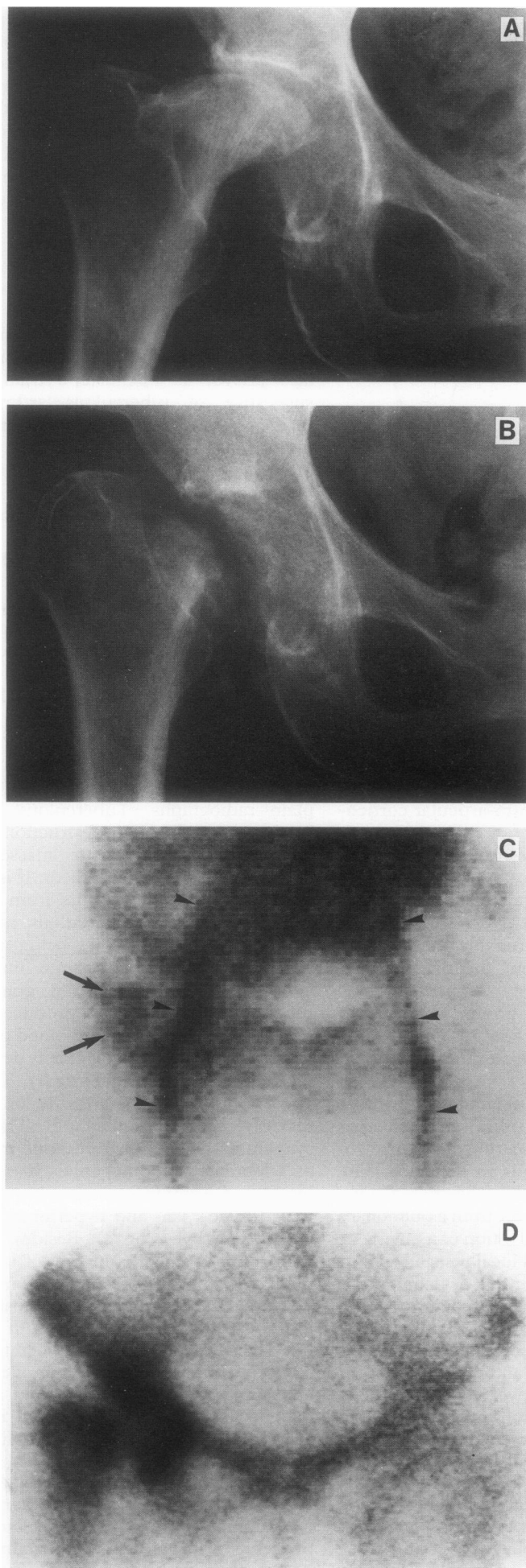
in diagnosis is frequent, as the clinical manifestations are often mild. Patients typically present with insidious onset of joint pain and swelling, with minimal signs of inflammation. Monoarticular disease predominates, although oligoarticular involvement is not uncommon. Weight bearing joints, such as the hip and knee, are most frequently affected. Physical findings which may be present are joint deformity, swelling and discharging sinus. Predisposing factors include trauma, intra-articular corticosteroid injection, narcotic addiction and, possibly, systemic illnesses.<sup>2-9</sup> In the United Kingdom, the incidence of bone and joint TB in immigrants from the Indian subcontinent is much greater than that in the indigenous population; however, probably because of reduced clinical suspicion, the diagnoses in latter group are invariably delayed in comparison with the Indian group.<sup>1</sup> Absence of pulmonary TB in more than 50% of patients with articular infection adds to the difficulty in diagnosis.<sup>2,3,8</sup>

In most subjects, tuberculous arthritis develops through spread from adjacent osteomyelitis. Alternatively, primary synovial involvement may occur, especially in the knee. The common pathway remains haematogenous spread of disease, presumably from a pulmonary focus. There may be reactivation of a quiescent focus following decreased local resistance, as a result of causes such as trauma or debilitation; the hip joint is one such recognised site.<sup>2</sup> Another pathway for articular contamination is fistula formation from tuberculous infection of organs such as the bowel and bladder, or from soft tissue abscesses. Conversely, tuberculous arthritis may spread to involve adjacent structures. Intra-articular tissue responds to the presence of tuberculosis bacilli by producing a well vascularised granulomatous lesion, which microscopically contains necrotic and fibrin like material, collections of leucocytes and mononuclear phagocytes, and areas of caseation. Epithelioid cells and tubercles

may be seen in the caseated areas. The granulation tissue may extend along the free cartilaginous surface, spread between cartilage and subchondral bone (particularly in close fitting articulating joints such as the hip and ankle), and occasionally, mushroom from a subchondral site, through gaps in the cartilage, into the joint cavity.<sup>9</sup> Figure 6 illustrates various mechanisms of articular infection.

In early disease, radiographs may be normal. Areas of decalcification of bone away from the joint surfaces and corner erosions then develop, especially in weight bearing joints such as the hip, knee, and ankle. This combination of periarticular osteoporosis, marginal erosions and relative joint space preservation, also known as Pheemister's triad, is highly suggestive of tuberculous arthritis.<sup>10</sup> The incidence and degree of bony proliferation, periostitis and intra-articular bony ankylosis are less than with pyogenic arthritis. Later, bone loss may occur as a result of destruction by granulation tissue. Sequestra may form and are seen as collections of dense bone fragments, adjacent to the articular edges.<sup>9</sup> Large areas of necrosis may occur in the subchondral bone on opposing sides of a weight bearing joint, resulting in gradual bony sequestration, forming so-called 'kissing sequestra'.<sup>10</sup> In advanced disease, massive destruction, subluxation, deformity and eventually, fibrous ankylosis, may result.<sup>9</sup>

CT is a useful tool in the evaluation of musculoskeletal TB, demonstrating more extensive involvement than could be seen on plain radiographs. Tuberculous lesions are seen as areas of osseous destruction, associated with adjacent soft tissue masses showing characteristic rim enhancement. It is postulated that this appearance occurs from developing vascularity of the tuberculous mass.<sup>11</sup> The application of scintigraphy, being sensitive but non-specific, is probably quite limited in this condition. The vascularised granulomatous tuberculous mass may produce increased uptake during dynamic and blood pool phases, with adjacent bony involvement demonstrated on delayed static images (fig 7). The appearance of tuberculous arthritis on MRI has recently been described.<sup>12,13</sup> The involved synovium and granulation tissue may be seen as a lobulated inhomogenous mass, of mixed hypo- and isointensities on T1 weighted, and mixed hypo-, iso- and hyperintensities on T2 weighted images (fig 8). Besides the inflammatory mass which is largely of low to intermediate T1 and high T2 signal, joint fluid (low T1 and high T2 signal), haemosiderin, and loose cartilaginous bodies (both producing low signal on T1 and T2 weighted images) also contribute to the inhomogenous MRI appearance.<sup>12,13</sup> As demonstrated in our first patient (fig 5), the utilisation of intravenous gadolinium-DTPA is helpful in delineating the extent of viable inflammatory tissue in tuberculous infection.<sup>14</sup> Obviously, conditions such as pigmented villonodular synovitis, haemophilia, synovial osteochondromatosis, pyogenic arthritis and post-traumatic loose bodies with associated joint effusion could

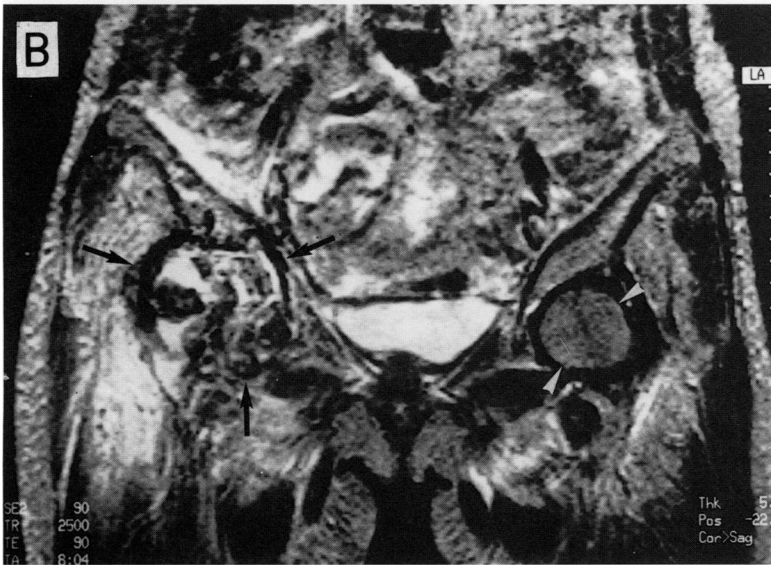
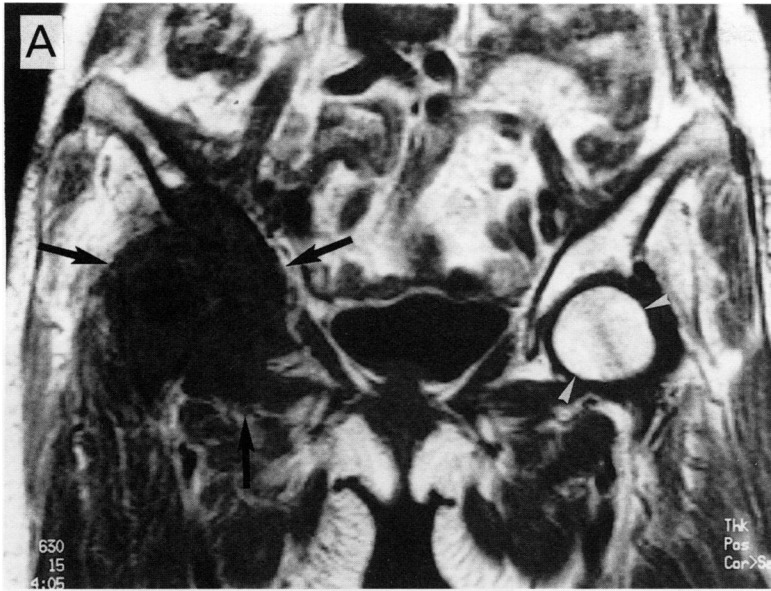


**Figure 7** Tuberculous arthritis of the right hip in a 68 year old woman. **A:** Initial radiograph showing long standing femoral head flattening and deformity, consistent with osteonecrosis. **B:** Radiograph taken four weeks later, showing destruction of the femoro acetabular articulation. **<sup>99m</sup>Tc-MDP scintigram shows (C)** increased blood pool uptake over the right hip on early static images, corresponding to the inflammatory mass (arrows), with linear areas representing iliac and femoral vessels (arrowheads); and **(D)** increased uptake at the acetabulum and remnant femoral neck on delayed (three hour) images, corresponding to infected bony margins.

produce similar MRI appearances.<sup>12</sup> However, an attempt at the diagnosis should only be made after careful review of the clinical and plain radiographic features. If this basic principle of MRI interpretation is observed, many of the differential diagnoses can be excluded.

The definitive diagnosis of tuberculous arthritis is based on identification of *Mycobacterium tuberculosis* organism from either the synovial fluid or the synovium itself, or on histological evidence of granulomas on synovial biopsy,<sup>9</sup> all of which give good diagnostic yields. Chemotherapy is the treatment of choice for all cases of tuberculous arthritis, being effective in arresting the disease progression. The British Thoracic Society has recommended that the drug treatment of adult patients with extrapulmonary TB should be shared with a chest physician and that of children shared with a paediatrician.<sup>15</sup> Surgery, including arthroplasty, may be indicated in selected patients to correct persisting deformities or provide relief to disabling arthropathy. In these cases, the importance of appropriate and adequate preoperative anti-tuberculous chemotherapy is emphasised.<sup>7 16</sup>

- Hodgson S P, Ormerod L P. Ten-year experience of bone and joint tuberculosis in Blackburn 1978-1987. *J R Coll Surg Edin* 1990; 35: 259-62.
- Enarson D A, Fujii M, Nakielna E M, Grzybowski S. Bone and joint tuberculosis: a continuing problem. *Can Med Assoc J* 1979; 120: 139-45.
- Davidson P T, Horowitz I. Skeletal tuberculosis—a review with patient presentations and discussions. *Am J Med* 1970; 48: 77-84.
- Subcommittee of the Joint Tuberculosis Committee of the British Thoracic Society. Guidelines on the management of tuberculosis and HIV infection in the United Kingdom. *BMJ* 1992; 304: 1231-3.
- Selwyn P A, Hartel D, Lewis V A, et al. A prospective study of the risk of tuberculosis among intravenous drug users with human immunodeficiency virus infection. *N Engl J Med* 1989; 320: 545-50.
- Berney S, Goldstein M, Bishko F. Clinical and diagnostic features of tuberculous arthritis. *Am J Med* 1972; 53: 36-42.
- Martini M, Ouahes M. Bone and joint tuberculosis: a review of 652 cases. *Orthopedics* 1988; 11: 861-6.
- Rathakrishnan V, Mohd T H. Osteo-articular tuberculosis. A radiological study in a Malaysian hospital. *Skeletal Radiol* 1989; 18: 267-72.
- Resnick D, Niwayama G. Tuberculous arthritis. In: Resnick D, Niwayama G, eds. *Diagnosis of bone and joint disorders*, 2nd edn. Philadelphia: W B Saunders, 1988: 2678-85.
- Phemister D B, Hatcher C H. Correlation of pathological and roentgenological findings in the diagnosis of tuberculous arthritis. *Am J Roentgenol* 1933; 29: 736-52.
- Coppola J, Müller N L, Connell D G. Computed tomography of musculoskeletal tuberculosis. *J Can Assoc Radiol* 1987; 38: 199-203.
- Schultz E, Richterman I, Dorfman H D. Case report 739. Tuberculous arthritis of knee. *Skeletal Radiol* 1992; 21: 330-4.
- Araki Y, Tsukaguchi I, Shino K, Nakamura H. Tuberculous arthritis of the knee: MR findings [letter]. *Am J Roentgenol* 1993; 160: 664.



- 14 de Roos A, van Meerten E L P, Bloem J L, Bluemm R G. MRI of tuberculous spondylitis. *Am J Roentgenol* 1986; 146: 79-82.
- 15 Ormerod L P for the Joint Tuberculosis Committee. Chemotherapy and management of tuberculosis in the United Kingdom: recommendations of the Joint Tuberculosis Committee of the British Thoracic Society. *Thorax* 1990; 45: 403-8.
- 16 Kim Y Y, Ko C U, Ahn J Y, Yoon Y S, Kwak B M. Charnley low friction arthroplasty in tuberculosis of the hip. An eight to 13-year follow-up. *J Bone Joint Surg Br* 1988; 70: 756-60.

Figure 8 MRI of the same patient as in figure 7. Coronal (A) T1 and (B) T2 weighted images of the pelvis demonstrate the tuberculous granulomatous lesion as a large mass of mixed heterogeneity occupying and eroding the margins of the right hip joint (arrows). Left femoral head is normal (arrowheads). Axial (C) T1 (upper) and T2 weighted (lower) images at the level of the intact left femoral head (arrowheads) show extent of the large right sided inflammatory mass (arrows).

