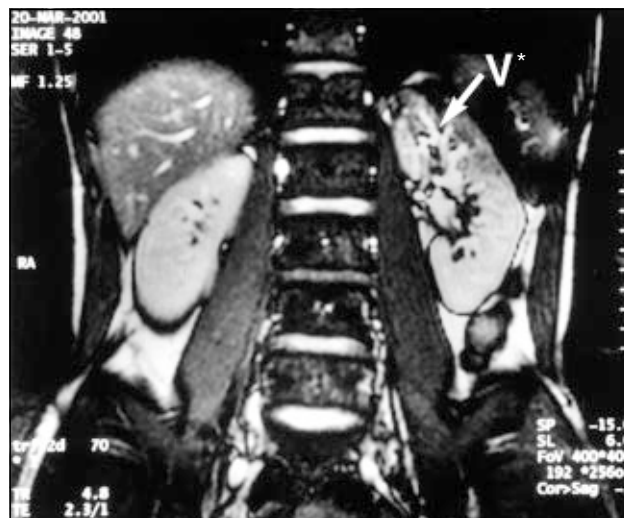

Nutcracker phenomenon presenting as left varicocele

A 27-year-old man with good past health presented with a left varicocele. He had no urinary symptoms and urine microscopy did not show haematuria. Subsequent ultrasound scan showed a grossly distended left renal vein. The cross-sectional view of magnetic resonance imaging (MRI) showed compression of the left renal vein between the superior mesenteric artery and the aorta, before the vein joins the inferior vena cava (Fig 1). This compression caused the marked dilatation of the distal left renal vein with associated venous hypertension (nutcracker phenomenon). The coronal view showed dilated vasculature over the upper pole of the left kidney (Fig 2), which was caused by the venous hypertension. The patient subsequently underwent laparoscopic varicocelectomy and conservative treatment was adopted for the left renal vein compression.

The nutcracker phenomenon was first described by de Schepper¹ in 1972. Compression of the left renal vein between the superior mesenteric artery and the aorta causes left renal vein hypertension,¹ and this led to a left varicocele in this patient. The resulting renal vein hypertension is also a cause of haematuria, thought to be due to hypertension-induced anomalous calyceal-venous communications.² The pathophysiology of this condition is not fully understood, but it may be more prevalent in thin people with a decreased amount of perirenal and pararenal adipose tissue or in those with a prominent lumbar lordotic curve that causes forward displacement of the aorta.³ Abnormal branching of the superior mesenteric artery from the aorta has also been attributed to be the underlying pathology.^{4,5} Apart from MRI or computed tomography, selective left renal vein phlebography and renal vein pressure measurement are helpful for establishing the diagnosis.^{4,5} For asymptomatic patients



* V vasculature

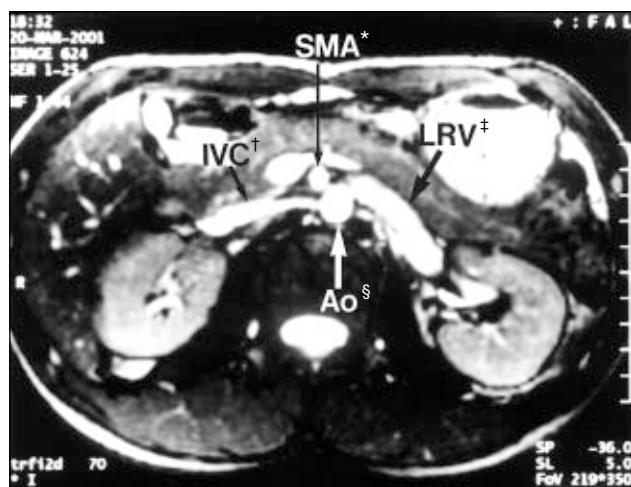
Fig 2. Magnetic resonance imaging coronal view showing dilated vasculature over the upper pole of the left kidney

with no haematuria, the treatment is conservative. For patients with gross haematuria, various surgical treatments including left renal vein transposition,⁴ left renal auto-transplantation,⁵ or endovascular stenting of the left renal vein,⁶ have been described. Besides left renal vein compression, similar pathophysiology may lead to duodenal obstruction at the third portion of the duodenum, known as superior mesenteric artery syndrome.⁷

ACW Ting, FRCS, FHKAM (Surgery)
 SWK Cheng, FRCS, FHKAM (Surgery)
 Division of Vascular Surgery, Department of Surgery
 The University of Hong Kong
 Queen Mary Hospital
 102 Pokfulam Road
 Hong Kong

References

1. de Schepper A. "Nutcracker" phenomenon of the renal vein and venous pathology of the left kidney [in Dutch]. *J Belge Radiol* 1972;55:507-11.
2. Beinart C, Sniderman KW, Saddekni S, Weiner M, Vaughan ED Jr, Sos TA. Left renal vein hypertension: a cause of occult hematuria. *Radiology* 1982;145:647-50.
3. Wendel RG, Crawford ED, Hehman KN. The "nutcracker" phenomenon: an unusual cause for renal varicosities and hematuria. *J Urol* 1980;123:761-3.
4. Hohenfellner M, Steinbach F, Schultz-Lampel D, et al. The nutcracker syndrome: new aspects of pathophysiology, diagnosis and treatment. *J Urol* 1991;146:685-8.
5. Shokeir AA, el-Diasty TA, Ghoneim MA. The nutcracker syndrome: new methods of diagnosis and treatment. *Br J Urol* 1994;74:139-43.
6. Segawa N, Azuma H, Iwamoto Y, et al. Expandable metallic stent placement for nutcracker phenomenon. *Urology* 1999;53:631-3.
7. Baltazar U, Dunn J, Floresguerra C, Schmidt L, Browder W. Superior mesenteric artery syndrome: an uncommon cause of intestinal obstruction. *South Med J* 2000;93:606-8.



* SMA superior mesenteric artery ‡ LRV left renal vein
 † IVC inferior vena cava § Ao aorta

Fig 1. Magnetic resonance imaging cross-sectional view showing compression of the left renal vein between the superior mesenteric artery and the aorta