

H Lau 劉 雄
F Lee 李 燦 榮
NG Patil 彭 達

Laparoscopic repair of incisional hernia

切口疝的腹腔鏡修補

.....
A 75-year-old man developed an incisional hernia over the upper abdomen following a wedge resection of a gastric stromal tumour in 1996. This is the first published report of a successful repair of an incisional hernia via a laparoscopic intraperitoneal on-lay technique using GORE-TEX DualMesh material in Hong Kong. Compared with conventional open repair of incisional hernia, long incisions and wound tension are avoided using the laparoscopic approach. This translates into a reduced risk of wound-related complications and facilitates recovery. In selected cases, minimally invasive surgery is a safe technique for the repair of incisional hernias.

一名 75 歲病人在 1996 年進行胃基質瘤楔入切除術後，在上腹部出現了一個切口疝。本文是首個在香港發表的使用 GORE-TEX DualMesh 材料的腹腔鏡內腹膜高嵌體技術成功修補切口疝的報告。與傳統的打開修補切口疝的技術相比，使用腹腔鏡方法避免了長切口和傷口的緊張狀態，也即是減少了與傷口有關併發症的危險，且能促進痊癒。在所選的病例中，最小切口的外科手術是用於修補切口疝的一項安全技術。

Introduction

Incisional hernia is one of the most common surgical pathologies and has been a challenge to surgeons for years.¹ This clinical complication occurs in 2% to 10% of abdominal operations. Early experience of endoscopic repair of incisional hernia has been hampered by the complications of adhesions and enterocutaneous fistula formation related to the choice of graft material.^{2,3} The recent introduction of a GORE-TEX DualMesh material (GORE-TEX DualMesh Biomaterial, WL Gore & Associates, Flagstaff, Arizona, US), which evokes minimal inflammation has given a new dimension to the endoscopic repair of incisional hernia.⁴ We report on a patient who underwent laparoscopic repair of incisional hernia using GORE-TEX DualMesh in Tung Wah Hospital.

Case report

A 70-year-old man underwent partial gastric resection in 1996 for a gastric stromal tumour. The operation was followed by the development of an incisional hernia over the left lateral end of the rooftop incision. The hernia had been increasing slowly in size and caused intermittent discomfort. With regard to his medical history, the patient had ischaemic heart disease, renal calculi, and benign prostatic hyperplasia. His body weight was 61 kg.

The operation was performed with the patient in a supine position using general anaesthesia. The first subumbilical 10-mm trocar port was placed by open dissection technique. A 30° telescope was then introduced after insufflation of the peritoneal cavity with carbon dioxide to a pressure

Key words:

Herniorrhaphy;
Laparoscopy;
Surgery

關鍵詞：

疝縫合術；
腹腔鏡檢查；
外科手術

HKMJ 2001;7:319-21

Department of Surgery, University of Hong Kong Medical Centre, Tung Wah Hospital, 12 Po Yan Street, Sheung Wan, Hong Kong
H Lau, FRACS, FHKAM (Surgery)
F Lee, FRACS, FHKAM (Surgery)
NG Patil, FRCS (Edin), FHKAM (Surgery)

Correspondence to: Dr H Lau

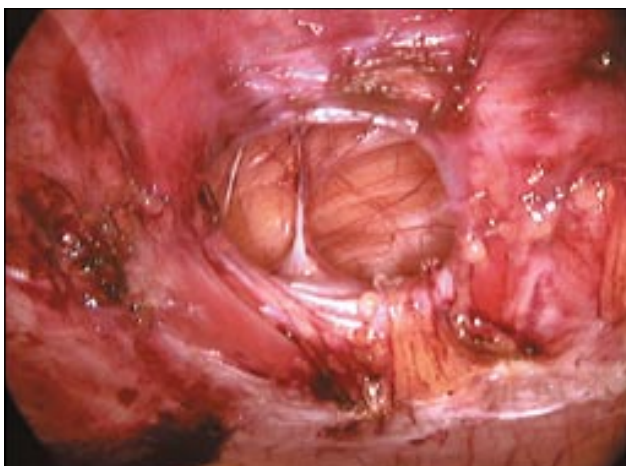


Fig 1. Incisional hernial defect with contents reduced

of 12 mm Hg. Two additional 5-mm trocars were inserted into the right side of the abdomen under direct visualisation. The contents of the hernia sac were reduced into the peritoneal cavity after lysis of adhesions. The edges of the hernia defect were ascertained by direct vision and palpation (Fig 1). The location was drawn on the abdomen and the size of the hernial defect was 4 x 4 cm. The GORE-TEX DualMesh was cut to a size that would overlap the defect by at least 3 cm in all directions. Non-absorbable sutures were placed at 5-cm intervals along the edge of the mesh. The mesh was then inserted into the peritoneal cavity. Small stab skin incisions 2 mm in length were made with a scalpel along the circumference of the mesh, which had been marked on the abdominal wall. An endoscopic suture passer was inserted through the abdominal wall into the peritoneal cavity. This was used to grasp the sutures of the mesh under direct vision and pull them through the abdominal wall. The sutures were then tied extra-corporeally and subcutaneously buried. The gaps between the sutures were closed by tacking the mesh to the peritoneum and transversalis fascia at 1-cm intervals to avoid bowel obstruction (Fig 2). The operative time was 1 hour 20 minutes.

The postoperative course was uneventful. The visual analogue pain scores at rest were six and four on postoperative days 1 and 2, respectively. The patient resumed a normal diet and ambulated comfortably on the first day after operation. He was discharged on postoperative day 2. During follow-up at 1 month, the patient was well and asymptomatic. There was no clinical evidence of recurrence.

Discussion

The technique for repair of incisional hernia has evolved in the 20th century. Primary closure of

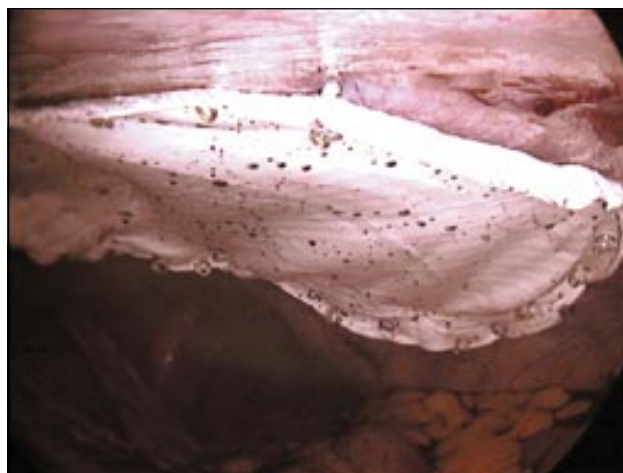

Fig 2. Completed repair with the GORE-TEX DualMesh being anchored in place by transabdominal sutures and spiral tackers

incisional hernia is associated with a high incidence of recurrence ranging from 30% to 50%, which is mainly related to the wound tension.¹ Prosthetic repair, which allows a tension-free closure of the defect, is thus advocated, particularly in the presence of a large hernial defect. Mesh repair of incisional hernia has been shown to reduce the recurrence rate to less than 10%.¹ Placement of a mesh, however, requires extensive dissection of the fascial planes with increased risk of wound complications.

With the advances in the technology of minimally invasive surgery in the 1990s, laparoscopic repair of incisional hernia has been gaining in popularity.⁵ The main benefits of minimally invasive surgery include diminished postoperative pain, reduced risk of wound complications, faster recovery, and a rapid return to normal activity. Compared with the open technique, the laparoscopic approach can clearly delineate the extent of the anatomical defect and allows a posterior repair of the hernia.⁶ As the trocars are placed away from the site of the hernia, the risk of bowel injury is also reduced.

Mesh material has been shown to be the most important factor contributing to the long-term complications of prosthetic incisional hernia repair.² Mersilene mesh had a significantly higher incidence of enterocutaneous fistula compared with other mesh materials and it should no longer be used for the prosthetic repair of abdominal hernias. Polypropylene mesh is also associated with a high incidence of adhesions and bowel erosions if it is placed intraperitoneally.⁷ GORE-TEX DualMesh has two different surfaces: the visceral surface has a low porosity that evokes minimal inflammation and limits tissue attachment; whereas the parietal surface is made of

high porosity expanded polytetrafluoroethylene, allowing fibrous adhesions and ingrowth.⁸ GORE-TEX DualMesh is the best contemporary choice of material for laparoscopic repair of incisional hernia.

Park et al⁹ reported a lower perioperative complication rate and a shorter hospital stay in patients who underwent laparoscopic repairs (n=56), compared with those who had conventional open repairs (n=49). In addition to these advantages, decreased hospital costs were noted by Holzman et al.¹⁰ A recurrence rate of 0.8% among 112 patients who underwent laparoscopic repair of incisional hernias with a mean follow-up of 2.8 years, was reported by Franklin et al.¹¹ A follow-up period of at least 3 years was recommended to evaluate the recurrence rate of incisional hernias.¹² Early outcomes of minimally invasive repair appeared to be superior to that of conventional open repair.¹³ No prospective randomised study, however, has been conducted to compare the results of laparoscopic and open repair of incisional hernia. The long-term benefits of laparoscopic repair of incisional hernia remain to be proven by future trials.

The laparoscopic approach is a promising novel technique for the repair of incisional hernia. Patients who have an incisional hernia larger than 4 cm in diameter are suitable surgical candidates.⁸ Laparoscopic lysis of adhesions is the most challenging step of the entire operation, as inadvertent enterotomy will lead to conversion to open repair. To ensure a good surgical outcome, this procedure should be performed by surgeons who have sufficient experience in laparoscopic surgery.

This is the first report of laparoscopic repair of incisional hernia using GORE-TEX DualMesh in Hong Kong. We believe this approach confers significant benefits to selected patients. With experience, the laparoscopic approach is a safe alternative to conventional open repair of incisional hernia.

Acknowledgement

The authors wish to acknowledge the kind assistance of Dr TC Tan, Department of Neurosurgery, Queen Elizabeth Hospital, Hong Kong, for editing the manuscript.

References

1. Santora TA, Roslyn JJ. Incisional hernia. *Surg Clin North Am* 1993;73:557-70.
2. Leber GE, Garb JL, Alexander AI, Reed WP. Long-term complications associated with prosthetic repair of incisional hernias. *Arch Surg* 1998;133:378-82.
3. Gillion JF, Begin GF, Marecos C, Fourtanier G. Expanded polytetrafluoroethylene patches used in the intraperitoneal or extraperitoneal position for repair of incisional hernias of the anterolateral abdominal wall. *Am J Surg* 1997;174:16-9.
4. Tsimoyiannis EC, Tassis A, Glantzounis G, Jabarin M, Siakas P, Tzourou H. Laparoscopic intraperitoneal onlay mesh repair of incisional hernia. *Surg Laparosc Endosc* 1998;8:360-2.
5. Heniford BT, Park A, Ramshaw BJ, Voeller G. Laparoscopic ventral and incisional hernia repair in 407 patients. *J Am Coll Surg* 2000;190:645-50.
6. Toy FK, Bailey RW, Carey S, et al. Prospective, multicenter study of laparoscopic ventral hernioplasty. Preliminary results. *Surg Endosc* 1998;12:955-9.
7. Christoforoni PM, Kim YB, Preys Z, Lay RY, Montz FJ. Adhesion formation after incisional hernia repair: a randomized porcine trial. *Am Surg* 1996;62:935-8.
8. Costanza MJ, Heniford BT, Arca MJ, Mayes JT, Gagner M. Laparoscopic repair of recurrent ventral hernias. *Am Surg* 1998;64:1126-7.
9. Park A, Birch DW, Lovrics P. Laparoscopic and open incisional hernia repair: a comparison study. *Surgery* 1998;124:816-22.
10. Holzman MD, Purut CM, Reintgen K, Eubanks S, Pappas TN. Laparoscopic ventral and incisional hernioplasty. *Surg Endosc* 1997;11:32-5.
11. Franklin ME, Dorman JP, Glass JL, Balli JE, Gonzalez JJ. Laparoscopic ventral and incisional hernia repair. *Surg Laparosc Endosc* 1998;8:294-9.
12. Hesselink VJ, Luijendijk RW, de Wilt JH, Heide R, Jeekel J. An evaluation of risk factors in incisional hernia recurrence. *Surg Gynecol Obstet* 1993;176:228-34.
13. Sanders LM, Flint LM, Ferrara JJ. Initial experience with laparoscopic repair of incisional hernias. *Am J Surg* 1999;177:227-31.