

# Carotid endarterectomy for carotid stenosis: audit at a tertiary referral centre

H Lau, SWK Cheng

Prospective randomised controlled trials performed in North America and Europe have demonstrated that the risk of future stroke or death is substantially reduced by performing carotid endarterectomy in symptomatic patients who have severe carotid stenosis. An audit was conducted to analyse the results of carotid endarterectomy performed during a 3-year period, at a tertiary referral vascular centre in Hong Kong. A total of 35 patients who had significant carotid stenosis underwent 36 carotid endarterectomies from October 1994 to September 1997. All patients recovered uneventfully without neurological complications or mortality. The audit showed that the current results of carotid endarterectomy at this institution fulfilled the criteria advised by the Stroke Council of the American Heart Association in 1995. Therefore, carotid endarterectomy is a validated therapeutic option for carotid stenosis in Hong Kong.

*HKMJ 1999;5:387-90*

*Key words: Carotid stenosis/surgery; Cerebrovascular disorders; Endarterectomy, carotid; Medical audit*

## Introduction

Stroke is a serious health problem in most developed countries. It is a major cause of disability and death in the elderly. The treatment of patients with stroke has become a substantial financial burden to society. Performing carotid endarterectomy is one of the most effective strategies of preventing ischaemic cerebrovascular disease.<sup>1</sup>

Prospective randomised controlled trials performed in North America and Europe have demonstrated the benefits of carotid endarterectomy in symptomatic patients with severe carotid stenosis.<sup>2,3</sup> However, the major risks of this procedure are stroke and stroke-related death. The real benefit of this procedure therefore relies on a balance between the outcome and the risks of the operation. Patients will benefit from this procedure as long as the perioperative morbidity and mortality rates are kept within the defined limits. To confer the benefit of carotid endarterectomy, it is imperative for the operating surgeon to demonstrate an acceptable surgical complication rate. The purpose of this study was to audit the results of carotid

endarterectomy at the Queen Mary Hospital during a 3-year period.

## Methods

From October 1994 to September 1997, a total of 35 patients with haemodynamically significant carotid stenosis ( $\geq 70\%$ ) underwent 36 carotid endarterectomies at the Division of Vascular Surgery at the Queen Mary Hospital. One patient underwent staged bilateral carotid endarterectomy. A retrospective analysis of the patient records was performed. Demographic data, including risk factors and associated medical diseases, were documented. The indications for surgery, and the early and long-term outcomes of surgical intervention were reviewed.

### *Preoperative evaluation*

Non-invasive colour doppler carotid duplex scanning was performed to confirm the diagnosis that was made at the time of presentation (Fig 1). In patients who presented with focal symptoms, computed tomography of the brain was used to rule out intracranial pathology. Arch aortography and bilateral carotid and vertebral arteriography were performed to assess the degree of stenosis and delineate the extent of disease (Fig 2). A preoperative cardiovascular evaluation was performed for all patients. The identification and modification of risk factors, such as the cessation of smoking and the optimal control of diabetes mellitus, cardiac disease, hypertension, and hyperlipidaemia,

---

Division of Vascular Surgery, Department of Surgery, The University of Hong Kong, Queen Mary Hospital, Pokfulam, Hong Kong

H Lau, MMed (Surgery) (Singapore), FRCS (Edin)  
SWK Cheng, MS, FRCS (Edin)

Correspondence to: Dr SWK Cheng

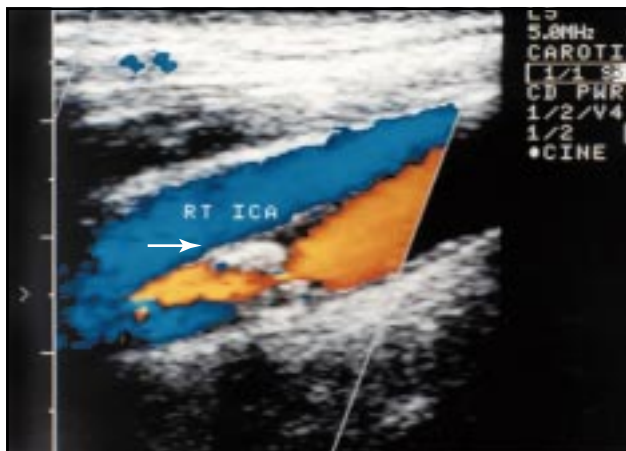


Fig 1. Colour doppler carotid duplex scan showing a high-velocity stenosis (arrow)

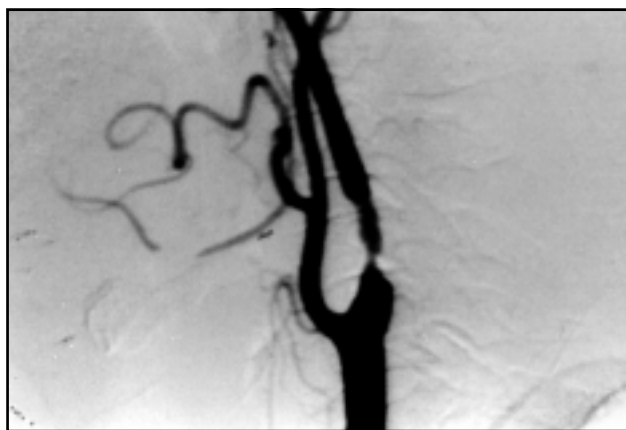

Fig 2. Carotid arteriogram showing a significant stenotic lesion of the internal carotid artery

were achieved in all patients prior to the operation. Aspirin 150 mg/d was prescribed for all patients.

### **Operative techniques**

While the patient was receiving general anaesthesia, an oblique cervical incision was made anterior to the sternocleidomastoid muscle. After the carotid sheath and carotid bifurcation were exposed, the vagus and hypoglossal nerves were identified and protected. Systemic heparin was then given and arterial clamps were applied. An arteriotomy was made at the site of the occlusion and a Javid inlay shunt was inserted whenever it was feasible to do so (Fig 3). The atherosclerotic plaque was then dissected from the internal carotid artery. The endarterectomy was completed by extracting the plaque from the external carotid artery (Fig 4). The arteriotomy was closed using a continuous suture of 6-0 monofilament polypropylene. Intra-operative duplex scanning was performed prior to wound closure to detect any intimal flaps or flow disturbances of the carotid arteries. The neurological status of the patient was closely monitored in the postoperative period.

### **Follow-up**

The duration of follow-up was calculated from the date of the operation to the date of the latest follow-up visit. After the first 1-month visit, all patients received regular follow-up at the Vascular Clinic of the Department of Surgery at the Queen Mary Hospital every 3 months. Aspirin 150 mg/d was routinely prescribed. Any recurrence of neurological symptoms was documented. Follow-up carotid duplex scanning was performed every 6 months to detect any recurrent stenoses.

### **Results**

#### **Demographic data**

The mean age of the study population was 70 years (range, 58-86 years) and the male to female ratio was 6:1. The patients had a history of one or more of the following medical diseases: hypertension (n=24), ischaemic heart disease (n=17), diabetes mellitus (n=12), and hyperlipidaemia (n=7). Of the 35 patients, 29 (83%) were currently or formerly chronic smokers, 17 (49%) had a history of stroke, and 19 (54%) had experienced



Fig 3. Intra-operative photograph showing the carotid arteriotomy with a Javid inlay shunt in situ after endarterectomy

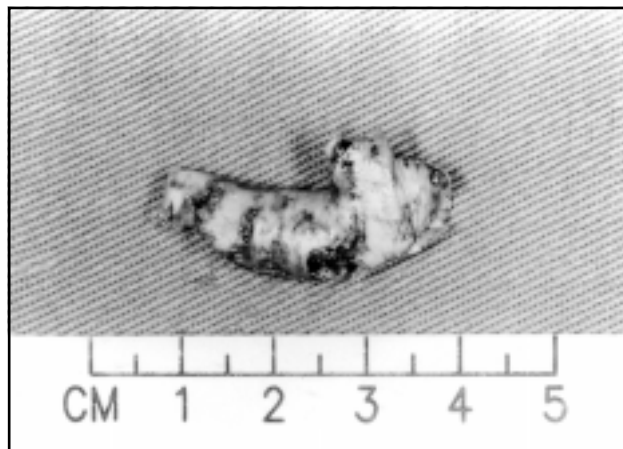


Fig 4. Carotid atherosclerotic plaque removed from the origin of the internal carotid artery

transient ischaemic attacks. The mean degree of carotid stenosis was 85% (standard deviation [SD], 12%).

### **Operative results**

The indications for surgical intervention were transient ischaemic attacks (n=12), minor stroke (n=17), and asymptomatic patients with high-grade stenosis (n=7). The mean duration of the operation was 2 hours 10 minutes (SD, 16 minutes). The mean blood loss was 40 mL (SD, 50 mL). An intra-operative shunt was used for 28 (80%) patients. After the operation, two patients had wound haematoma, and cardiac arrhythmia developed in one patient on the first postoperative day; the morbidity rate was 8%. All patients recovered uneventfully and without any neurological deficit. There was no operative or hospital mortality. The mean duration of postoperative hospital stay was 6 days (range, 3-13 days).

### **Results at follow-up**

The median duration of follow-up was 18 months (range, 6-40 months). One patient defaulted follow-up at 6 months. Two (6%) patients had recurrent stenosis, as detected by surveillance carotid duplex scanning. Of these two patients, one remained asymptomatic and declined further operation. The other patient experienced transient ischaemic attacks and underwent carotid endarterectomy with vein patch angioplasty in October 1997. He recovered uneventfully from the operation. All patients remained alive and well, and no further transient ischaemic attacks or stroke were reported at the last follow-up in February 1998.

### **Discussion**

Carotid endarterectomy has been shown to be an effective therapy for symptomatic high-grade ( $\geq 70\%$ ) carotid artery stenosis in a number of randomised controlled trials performed in North America and Europe.<sup>2-5</sup> The North American Symptomatic Carotid Endarterectomy Trial Collaborators found that the cumulative risk of the recurrence of stroke at 2 years was 26% in 331 medically treated patients and 9% in 328 surgically treated patients<sup>2</sup>—an absolute risk reduction of 17%. The European Carotid Surgery Trialists' Collaborative Group<sup>3</sup> reported similar results. In 778 patients with severe carotid stenosis (70%-99%), a six-fold reduction of the rate of stroke recurrence at 3 years was observed in the surgically treated patients compared with control patients taking aspirin.<sup>3</sup>

Many patients who have generalised atherosclerotic arterial occlusive disease will die of cardiac attacks instead of stroke. Enhancing the quality of life rather

than just prolonging survival is a major consideration in the long-term treatment of patients who are at risk of stroke. Carotid endarterectomy is a prophylactic operation that is designed to reduce the risk of disabling or fatal stroke occurring in the future. The removal of the stenotic lesion prevents hypoperfusion and embolism.

Patients who undergo carotid endarterectomy usually have minor or no symptoms. The justification of performing this procedure, however, relies on a balance between the benefits and the risks of the operation. It is imperative to keep the operative risk—particularly that of perioperative stroke and death—to a minimum.<sup>6</sup> Operative risk depends not only on the surgeon's skill and the quality of perioperative care, but also the patient's general health status and the indications for surgery.<sup>7</sup> The risk of perioperative stroke is lowest in asymptomatic patients and highest in patients who have a history of stroke.<sup>8</sup>

There has been controversy about who should perform a carotid endarterectomy. The identification of problems by performing regular audits will help improve the results of surgery and the quality of care within an institution. The audit should be objective, unbiased, and accurate—especially with regard to surgical morbidity and mortality—and be made publicly available. In North America, only those surgeons and institutions that were able to provide proof of an acceptable standard of surgical competence were allowed to participate in the carotid endarterectomy trial.<sup>2</sup> In 1995, the Stroke Council of the American Heart Association reviewed available reports and recommended the upper acceptable limits of surgeons' combined perioperative stroke and mortality rates for various indications for carotid endarterectomy.<sup>7</sup> The limits were 3% for asymptomatic patients, 5% for patients who had experienced transient ischaemic attack, 7% for patients with previous stroke, and 10% for patients undergoing surgery for recurrent stenosis. The benefit conferred by surgery will diminish once the perioperative complication rate exceeds the acceptable limits.

During the 3 years of this study, there was no post-operative neurological complication or mortality after carotid endarterectomy at the Queen Mary Hospital. During the postoperative period, only two patients had mild wound bruising and one patient experienced cardiac arrhythmia on the first postoperative day. During follow-up, two patients were shown to have recurrent stenosis; although these two patients remained well, one of them had a restenosis within 1 year. The current combined perioperative stroke

and mortality rate of this audit falls within the acceptable range proposed by the Stroke Council of the American Heart Association.<sup>7</sup>

The relatively small proportion (33%) of patients who underwent surgery for transient ischaemic attacks in this study indicates that carotid stenosis may have been underdiagnosed in Hong Kong. The past lack of awareness of this condition among physicians, the formidable complication (ie stroke), and the previous paucity of surgical expertise are possible reasons for the underdiagnosis. Owing to the increasing influence of western lifestyles, the incidence of atherosclerotic arterial occlusive disease, including carotid stenosis, has been increasing in Hong Kong.<sup>9</sup> The timely identification of at-risk patients plays an important role in primary health care. Patients with carotid stenosis should be referred for further assessment and treatment.<sup>10,11</sup>

Carotid angioplasty and stenting are regarded as investigative procedures and are preferably limited to clinical trials only.<sup>12,13</sup> Most reports have shown that carotid angioplasty and stenting have a higher complication rate than carotid endarterectomy.<sup>14,15</sup> The efficacy of the former procedure has not been tested by a randomised trial, but in difficult cases and medically unfit patients, endovascular intervention is a feasible option.

In conclusion, carotid endarterectomy is a viable treatment for carotid stenosis in Hong Kong. Patients with a significant carotid lesion ( $\geq 70\%$ ) are potential candidates for carotid endarterectomy.

### Acknowledgements

We wish to thank Mrs WLH Wong, who performed the carotid duplex scanning, and staff at the Francis YH Tien Vascular Disease Centre of the Queen Mary Hospital for their invaluable assistance with the data collection.

### References

1. Eikelboom BC. Carotid endarterectomy: confidence restored. *Br J Surg* 1993;80:821-2.
2. North American Symptomatic Carotid Endarterectomy Trial Collaborators. Beneficial effect of carotid endarterectomy in symptomatic patients with high-grade carotid stenosis. *N Engl J Med* 1991;325:445-53.
3. European Carotid Surgery Trialists' Collaborative Group. MRC European Carotid Surgery Trial: interim results for symptomatic patients with severe (70-99%) or with mild (0-29%) carotid stenosis. *Lancet* 1991;337:1235-43.
4. Mayberg MR, Wilson SE, Yatsu F, et al. Carotid endarterectomy and prevention of cerebral ischemia in symptomatic carotid stenosis. Veterans Affairs Cooperative Studies Program 309 Trialist Group. *JAMA* 1991;266:3289-94.
5. Executive Committee for the Asymptomatic Carotid Atherosclerosis Study. Endarterectomy for asymptomatic carotid artery stenosis. *JAMA* 1995;273:1421-8.
6. Moore WS, Mohr JP, Najafi H, Robertson JT, Stoney RJ, Toole JF. Carotid endarterectomy: practice guidelines. Report of the Ad Hoc Committee to the Joint Council of the Society for Vascular Surgery and the North American Chapter of the International Society for Cardiovascular Surgery. *J Vasc Surg* 1992;15:469-79.
7. Moore WS, Barnett HJ, Beebe HG, et al. Guidelines for carotid endarterectomy. A multidisciplinary consensus statement from the Ad Hoc Committee, American Heart Association. *Circulation* 1995;91:566-79.
8. The European Carotid Surgery Trialists Collaborative Group. Risk of stroke in the distribution of an asymptomatic carotid artery. *Lancet* 1995;345:209-12.
9. Cheng SW, Wong J. Development of vascular surgery in Hong Kong. *Asian J Surg* 1996;19:6-10.
10. Humphrey PR. Management of transient ischaemic attacks and stroke. *Postgrad Med J* 1995;71:577-84.
11. Taylor DC. 2. Current noninvasive diagnosis of carotid artery stenosis: indications and limitations. *Can J Surg* 1994;37:114-23.
12. Grotta J. Elective stenting of extracranial carotid arteries [editorial]. *Circulation* 1997;95:303-5.
13. Lau JW, Yeung CK. Carotid stenting and angioplasty [letter]. *HKMJ* 1999;5:208-9.
14. Yadav JS, Roubin GS, Iyer S, et al. Elective stenting of the extracranial carotid arteries. *Circulation* 1997;95:376-81.
15. Society for Vascular Surgery. International Society for Cardiovascular Surgery, North American Chapter. Statement regarding carotid angioplasty and stenting. *J Vasc Surg* 1996; 24:900.