

# Helicobacter pylori and associated duodenal ulcer

C K Yeung, K H Fu, K Y Yuen, W F Ng, T M Tsang, F J Branicki, H Saing

## Abstract

Twenty three children with coexistent duodenal ulcer and *Helicobacter pylori* infection were treated with either two weeks of amoxicillin (25 mg/kg/day) in addition to six weeks of cimetidine, or cimetidine alone. Endoscopy with antral and duodenal biopsies for urease test, microaerophilic culture, and histological studies were performed at entry, six weeks, 12 weeks, and at six months. Children with persistent *H pylori* infection at six weeks were given a further two weeks' course of amoxicillin. *H pylori* persisted in all children not receiving amoxicillin treatment but cleared in six of the 13 children (46%) treated with amoxicillin. With failure of *H pylori* clearance at six months, only two out of six (33%) ulcers had healed and 50% of patients had experienced ulcer recurrence. In contrast, when *H pylori* remained cleared all ulcers healed and no ulcer recurred. Persistent *H pylori* infection was associated with persistent gastritis and duodenitis despite endoscopic evidence of ulcer healing. Detection and eradication of *H pylori* deserves particular attention in the routine management of duodenal ulceration in children.

The association between the presence of *Helicobacter pylori* in antral mucosa and histological gastritis has now been well established both in adults<sup>1 2</sup> and children.<sup>3 4</sup> It has also been shown in adults that *H pylori* infection plays an important part in the healing and relapse of duodenal ulcer.<sup>5</sup> Similar studies are, however, lacking in children and the above association between *H pylori* infection and duodenal ulceration in the paediatric population still requires clarification. This report documents a prospective study to evaluate the clinical, endoscopic, microbiological, and histological features of duodenal ulcer associated with *H pylori* in children after amoxicillin treatment.

## Patients and methods

Twenty three children (mean age 11.2 years, range 4-16) diagnosed endoscopically to have duodenal ulcer with coexistent isolation of *H pylori* from the gastric and/or duodenal mucosa were entered into the study. There were 15 boys and eight girls. Ten children had a history of upper gastrointestinal bleeding, and in 13 upper endoscopy had been undertaken for recurrent upper abdominal pain of three or more months' duration. Patients in whom gastric or duodenal biopsy was contraindicated and those who had

recently completed an antibiotic course before endoscopy were excluded from the study. Written informed consent was obtained from parents before inclusion.

## ENDOSCOPY AND BIOPSY

Endoscopic examinations were performed using a paediatric forward viewing gastroscope (Olympus GIF XP or GIF P2). Acute duodenal ulcers with no endoscopic evidence of chronicity (that is, deep lesions with fold convergency and bulb deformity) were included in the study but superficial mucosal erosions and ulceration secondary to steroids, stress, etc, were excluded. Two gastric mucosal biopsy specimens were taken from the antrum at 1-2 cm from the pylorus. The first specimen was divided into two portions. One portion was immediately ground in the endoscopy room for the rapid urease test using 1 ml of freshly prepared 10% urea solution,<sup>6</sup> and the other was despatched immediately for microbiological smear and culture. The second biopsy specimen was fixed in formol saline for histological section. Two mucosal biopsy specimens were also taken from the duodenal cap adjacent to the ulcer and were processed in a similar manner to the gastric biopsy specimens.

## HISTOLOGY

Histological sections of the specimens were stained with haematoxylin and eosin for grading of gastritis and duodenitis, and with Warthin-Starry stain to demonstrate the bacteria. Antral gastritis was graded according to the criteria of Whitehead *et al*,<sup>7</sup> depending on the presence or absence of polymorphonuclear leucocytes and the intensity of inflammatory cell infiltration. Active chronic gastritis (polymorphonuclear leucocytes present) was graded with scores from 0-3 (absent, mild, moderate, severe). A score of 0-3 was also assigned for duodenitis according to the classification described by Wyatt *et al* (table 1).<sup>8</sup>

## MICROBIOLOGY

A portion of the specimen was examined by Gram stain and it was then inoculated after grinding onto a brain heart infusion agar with vancomycin, nalidixic acid, and amphotericin B within three hours of collection. The plates were incubated at 37°C in a microaerophilic environment and examined at the fourth and seventh day before being discarded.

All laboratory investigations were conducted

University of  
Hong Kong,  
Queen Mary Hospital,  
Hong Kong,  
Department of Surgery  
C K Yeung  
T M Tsang  
F J Branicki  
H Saing

Department of Pathology  
K H Fu  
W F Ng

Department of  
Microbiology  
K Y Yuen

Correspondence to:  
Dr C K Yeung,  
Division of  
Paediatric Surgery,  
Department of Surgery,  
University of Hong Kong,  
Queen Mary Hospital,  
Hong Kong.

Accepted 24 May 1990

Table 1 Grading of duodenitis

Grade	Degree of duodenitis	Histological features
0	Normal	Normal duodenal architecture
1	Insignificant duodenitis	Architectural changes only with no definite increase in inflammatory cells
2	Chronic duodenitis	Definite increase in mononuclear cells in the lamina propria with evidence of epithelial degeneration
3	Active duodenitis	Changes of chronic duodenitis plus presence of intraepithelial neutrophils

without prior knowledge of endoscopy findings, treatment regimen or *H pylori* state. A patient was defined as *H pylori* positive if the bacteria were identified either by histological examination or culture, and *H pylori* negative if the bacteria were not detected.

TREATMENT REGIMEN

A decision regarding treatment was made immediately after endoscopy according to the result of the urease test. *H pylori* was assumed to be present when a biopsy specimen showed a positive urease test as indicated by a definite colour change from yellow to pink within five minutes. Patients with a positive result were then randomly assigned to receive either two weeks of amoxicillin (25 mg/kg/day in three divided doses) in addition to a six week therapeutic course of cimetidine (20 mg/kg/day in three divided doses), or cimetidine alone. All patients with a positive urease test had *H pylori* infection confirmed subsequently on histological examination or culture, and no patient was removed from the study with a false positive urease result.

Endoscopy with antral and duodenal biopsies for urease test, microaerophilic culture, and histological studies were repeated immediately after six weeks' treatment and again at 12 weeks. All patients with *H pylori* detected again at six weeks received a further two week course of amoxicillin. In addition, patients with unhealed or partially healed ulcers were given

further six week courses of cimetidine until complete healing was achieved. Maintenance treatment with nocturnal dosage of cimetidine, 10 mg/kg, was given only to patients who required more than one therapeutic course of cimetidine for complete ulcer healing. Follow up endoscopy and biopsy were repeated again at six months after entry.

STATISTICAL ANALYSIS

Data analyses were performed using the  $\chi^2$  test with Yates's correction and the Wilcoxon test, *p* values of <0.05 were considered to be significant.

Results

EFFICACY OF TREATMENT FOR H PYLORI ERADICATION

All 23 children completed 12 weeks of treatment, although three were lost to follow up at six months. For the first six weeks of treatment, 13 children received two weeks of amoxicillin with cimetidine, whereas the remaining 10 children were given cimetidine alone (fig 1). Endoscopy and biopsy after six weeks treatment showed that six of 13 children (46%) who received amoxicillin became *H pylori* negative. In contrast, all 10 children not receiving amoxicillin remained positive (*p*<0.02).

The 17 children who remained positive at the end of six weeks were given a further two week course of amoxicillin. Seven of these 17 (41%) became negative and 10 remained positive for *H pylori* on endoscopy at 12 weeks. Of six children with initial clearance at six weeks, three remained negative and three were found to have a relapse of *H pylori* infection.

Twenty children were available for follow up at six months. Four of 10 children with clearance of *H pylori* at 12 weeks had a relapse of infection and only six remained negative after initial clearance. Of 10 children with *H pylori* infection at 12 weeks, only one child had spontaneous clearance of *H pylori* and nine remained positive. Six of these nine children were persistently infected throughout the study period without clearance of *H pylori*.

ULCER HEALING AND SYMPTOMATIC RELIEF (TABLE 2)

After the first six week treatment period, four of six children who were then negative had healed their ulcers whereas only seven of 17 (41%) children still positive had endoscopic ulcer healing (*p*>0.2). On repeat endoscopy at 12 weeks, ulcer healing had taken place in eight of 10 children in the negative group compared with only seven of 13 children (54%) in the positive group (*p*>0.15). On follow up at six months all six children who remained negative after initial

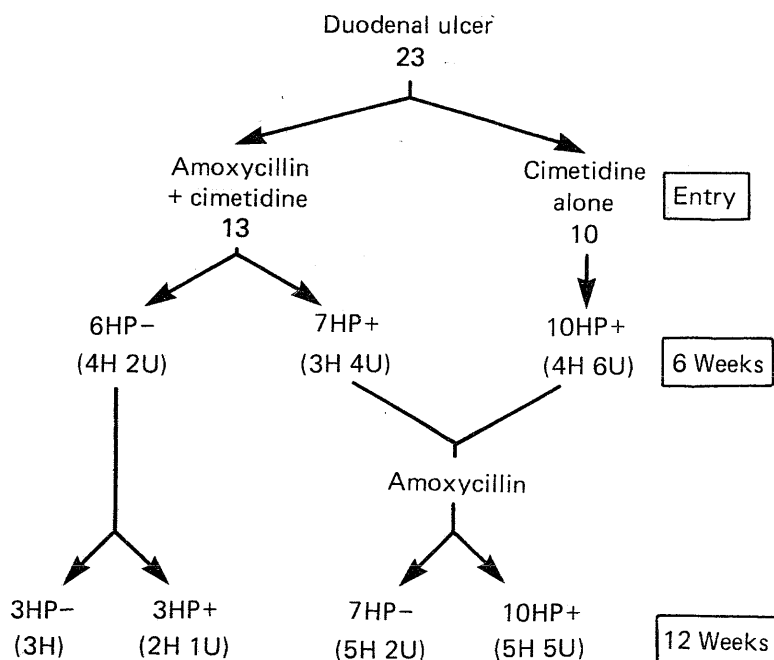


Figure 1 Treatment regimen, *H pylori* state, and ulcer healing (H=ulcer healed, U=ulcer unhealed, HP-=*H pylori* negative, HP+=*H pylori* positive).

Table 2 Clinical, endoscopic, and histological changes with clearance of *H pylori* after amoxycillin treatment

	At entry	<i>H pylori</i> at 6 weeks		<i>H pylori</i> at 12 weeks		<i>H pylori</i> at 6 months	
		Negative	Positive	Negative	Positive	Negative	Positive
No of children	23	6	17	10	13	7	13
Ulcer symptoms present	17	1	8	2	8*	0	6*
Endoscopic findings:							
Nodular antritis	11	1	7	2	4	0	5
Ulcer healed	0	4	7	8	7	7	8
Ulcer unhealed	23	2	10	2	6 (1)	0	5 (3)
Histological findings:							
Active chronic gastritis	23	2	16*	3	12*	3	13*
Significant duodenitis (grade 2 and 3)	14	3	10	1	7*	1	8*

Numbers in parentheses denote ulcer recurrence.

\*Significant difference ( $p < 0.05$ ) between positive and negative groups.

clearance had healed ulcers. In contrast, ulcers had healed in only two of six children with persistent *H pylori* infection throughout the study period ( $p < 0.02$ ).

Only one child who was negative for *H pylori* at six weeks had persistent abdominal pain compared with eight who were positive ( $p > 0.15$ ). At 12 weeks, two of 10 children in the negative group had residual abdominal pain compared with eight of 13 children in the positive group ( $p < 0.05$ ).

#### ULCER AND SYMPTOM RECURRENCE (TABLE 3)

An 11 year old boy with persistent *H pylori* infection was found to have early asymptomatic relapse of ulcer at 12 weeks. Three more children in the positive group were also found to have ulcer recurrence on endoscopy at six months, two of whom had complained of recurrent abdominal pain. None of the six children who remained negative at six months after initial clearance had developed a recurrent ulcer. In contrast, all three children with ulcer recurrence at six months had persistent *H pylori* infection throughout the study period ( $p < 0.05$ ). All seven children in the group negative for *H pylori* at six months were symptom free whereas six of 13 children in the positive group still had residual pain ( $p = 0.03$ ).

#### SIDE EFFECTS OF TREATMENT

Five of the 23 children developed side effects on amoxycillin treatment: three with protracted diarrhoea and two with skin eruptions. These symptoms subsided spontaneously after cessation of treatment. There were no side effects observed related to cimetidine treatment.

#### HISTOLOGICAL GASTRITIS AND DUODENITIS

*H pylori* was detected in 66 of 89 available antral biopsy specimens, with 64 (97%) having histo-

logical evidence of active chronic gastritis. In the remaining two without histological gastritis, coexistent duodenal biopsy specimens showed active duodenitis with *H pylori* being detected in one. Eradication of *H pylori* was associated with a significant improvement in the severity of histological gastritis (fig 2). The mean score for polymorphonuclear leucocytes for active gastritis in the clearance group at 12 weeks decreased from 1.50 before treatment to 0.30 after *H pylori* eradication ( $p < 0.01$ ). In contrast, the score in the persistently infected group fell only from 1.54 to 1.23 ( $p > 0.15$ ). Relapse of infection was associated with a significant worsening of active gastritis.

The grading of duodenitis also correlated significantly with *H pylori* infection and histological active gastritis but did not correlate well with endoscopic ulcer healing (fig 3). The mean duodenitis score in the negative group at 12 weeks decreased from 1.80 before treatment to 0.60 after *H pylori* eradication ( $p < 0.01$ ). In contrast, the duodenitis score in the positive group only fell from 1.77 to 1.54 ( $p > 0.3$ ).

Active duodenitis (intraepithelial neutrophils present) was found in 21 of 89 (24%) duodenal biopsy specimens and gastric metaplasia on 26 occasions (29%) of which 17 were associated with active duodenitis. The presence of *H pylori* in duodenal mucosa was detected in 10 biopsy specimens, all showing histological evidence of active duodenitis. Furthermore, the presence of *H pylori* in duodenal mucosa was confined to areas of gastric metaplasia.

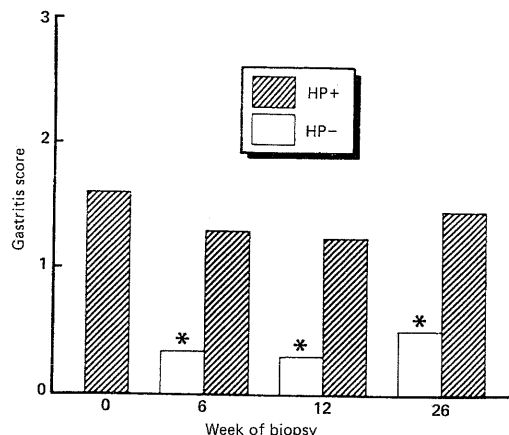


Figure 2 Effect of clearance, of *H pylori* on gastritis score (number of polymorphonuclear leucocytes present). (HP- = *H pylori* negative, HP+ = *H pylori* positive.) \* $p < 0.01$ .

Table 3 Ulcer recurrence and *H pylori* infection

	<i>H pylori</i> at 12 weeks		<i>H pylori</i> at 6 months	
	Negative	Positive	Negative	Positive
Ulcer recurrence	0	1	0	3 (3)
No recurrence	10	12	7*	10 (3)

Numbers in parentheses denote persistent *H pylori* infection throughout study period.

\*Six remained negative after initial eradication.

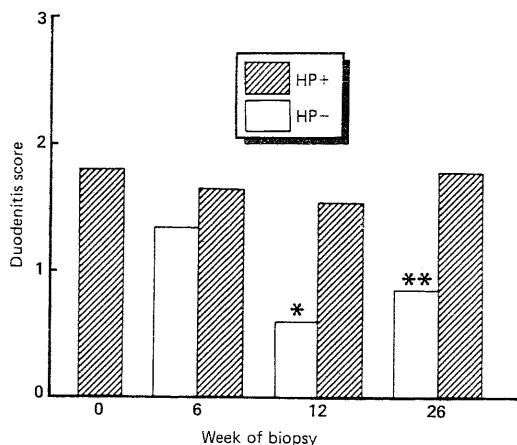


Figure 3 Effect of clearance of *H pylori* on duodenitis score. (HP- = *H pylori* negative, HP+ = *H pylori* positive.) \* $p < 0.01$ , \*\* $p < 0.05$ .

### Discussion

With the more frequent application of flexible upper endoscopy and hence more accurate diagnosis of lesions in the upper gastrointestinal tract,<sup>9</sup> the detection of duodenal ulcer in children has increased appreciably in our practice in recent years.<sup>10</sup> Although the use of H<sub>2</sub> receptor antagonists has resulted in improved ulcer healing rates, recurrence of ulceration frequently occurs in over one third of patients.<sup>11,12</sup> Marshall *et al* suggested that the presence of *H pylori* infection was the most important aetiological factor in the pathogenesis of duodenal ulcer diathesis, as persistent *H pylori* infection had been shown to be associated with significantly lower ulcer healing rates and a greater likelihood of ulcer recurrence.<sup>5</sup> Similar studies of *H pylori* associated duodenal ulcer in children and its treatment have not been reported previously. It has, however, been shown that in children with refractory duodenal ulcer, a six week course of amoxicillin achieved complete ulcer healing.<sup>13</sup> This supports the hypothesis that microbial infection might also play an important part in the pathophysiology of peptic ulcer disease in childhood. In this study, all children who remained cleared of *H pylori* after initial eradication had healed ulcers at six months without recurrent ulceration. In contrast, with failure of eradication of *H pylori* only 33% of ulcers healed ( $p < 0.02$ ) and 50% recurred ( $p < 0.05$ ) during the six month period. Children in the group negative for *H pylori* also experienced significantly less abdominal pain when compared with the persistently infected group.

As clearance of *H pylori* has only been observed with antimicrobial treatment,<sup>2,13-15</sup> and spontaneous remission of *H pylori* infection rarely occurred with use of H<sub>2</sub> receptor antagonists alone,<sup>5</sup> a combination of bactericidal and ulcer healing agents appears promising for treatment of duodenal ulceration in children.<sup>16</sup> The use of amoxicillin to eradicate *H pylori* infection has been disappointing in this study as fewer than half of the patients responded and relapse of infection was common. Furthermore, side effects including protracted diarrhoea and skin rash were troublesome. Although Oderda *et al*

have reported the effective use of amoxicillin (50 mg/kg/day, twice the standard dosage) plus tinidazole for six weeks in eradication of *H pylori* infection without mention of any side effects,<sup>17</sup> it is unlikely that children in our locality can tolerate such a dose. It has recently been shown in adults that a combination of colloidal bismuth subcitrate and tinidazole was much more effective in healing ulcers and preventing recurrence than cimetidine alone.<sup>5</sup> The use of bismuth preparations in children is, however, less desirable because of its possible neurotoxicity and arthrotoxicity in the growing child, and hence better therapeutic agents must still be sought.

The presence of *H pylori* in the gastric antrum was strongly associated with active chronic gastritis and this is in accordance with most reports in adults.<sup>1,2,13-15</sup> The severity of active gastritis correlated only with *H pylori* state and significantly improved with eradication of infection. There is little understanding of the strong correlation between *H pylori* associated gastritis and the presence of inflammatory infiltrates in the duodenum. It has been shown in this study that when *H pylori* was present in the duodenum, this was always associated with active duodenitis.<sup>18,19</sup> According to the hypothesis that duodenitis represents a part of the pathophysiological spectrum of duodenal ulcer diathesis,<sup>8,18</sup> persistent duodenitis associated with the persistence of *H pylori* infection after endoscopic ulcer healing might well be of importance in the pathogenesis of duodenal ulcer diathesis and recurrence.

Gastric metaplasia was also found in duodenal mucosa in children in this study, although the frequency of 29.2% was lower than most reported series in adults.<sup>7,18,20</sup> It is interesting to note that the presence of *H pylori* in the duodenum was invariably confined to areas of gastric metaplasia and was always associated with active duodenitis.<sup>8,19</sup> As it has also been shown that *H pylori* infection was associated with hypergastrinaemia and increased serum pepsinogen I concentrations,<sup>17,21</sup> it may be postulated that *H pylori* infection can act synergistically with acidpepsin induced gastric metaplasia to produce active duodenitis and mucosal damage which may culminate in ulceration.

In summary, our results document that persistent *H pylori* infection is associated with persistence of gastritis and duodenitis despite endoscopic evidence of ulcer healing. Significantly more patients in the persistently infected group had unhealed ulcers with residual symptoms and ulcer recurrence. We support the proposals of Marshall *et al*<sup>5</sup> and recommend that detection and eradication of *H pylori* deserves particular attention in the routine management of duodenal ulceration in childhood.

1 Warren JR, Marshall BJ. Unidentified curved bacilli on gastric epithelium in active chronic gastritis. *Lancet* 1983;i:1273-5.

2 McNulty CAM. The treatment of campylobacter-associated gastritis. *Am J Gastroenterol* 1987;82:245-7.

3 Cadranet S, Goossens H, DeBoeck M, Malengreau A, Rodesch P, Butzler J. Campylobacter pyloridis in children. *Lancet* 1986;i:735-6.

4 Drumm B, O'Brien A, Cutz E, Sherman P. Campylobacter

- pyloridis-associated primary gastritis in children. *Pediatrics* 1987;80:192-5.
- 5 Marshall BJ, Goodwin CS, Warren JR, et al. Prospective double-blind trial of duodenal ulcer relapse after eradication of *Campylobacter pylori*. *Lancet* 1988;ii:1437-42.
  - 6 Arvind AS, Cook PS, Tabaqchali S, Forthing MJG. One-minute endoscopy room test for *Campylobacter pylori*. *Lancet* 1988;i:704.
  - 7 Whitehead R. Gastritis. In: Whitehead R, ed. *Mucosal biopsy of the gastrointestinal tract*. 3rd Ed. London: Saunders, 1985:41-58.
  - 8 Wyatt JL, Rathbone BJ, Dixon MF, Heatley RV. *Campylobacter pyloridis* and acid induced gastric metaplasia in the pathogenesis of duodenitis. *J Clin Pathol* 1987;40:841-8.
  - 9 Gans SL, Ament M, Christie DL, et al. Pediatric endoscopy with flexible fiberoscopes. *J Pediatr Surg* 1975;10:375-80.
  - 10 Tam PKH, Saing H, Lau JTK. Diagnosis of peptic ulcer in children: the past and present. *J Pediatr Surg* 1986;21:15-6.
  - 11 Chiang BL, Chang MH, Lin ML, et al. Chronic duodenal ulcer in children: clinical observation and response to treatment. *J Pediatr Gastroenterol Nutr* 1989;8:161-5.
  - 12 Tam PKH, Saing H. The use of H<sub>2</sub>-receptor antagonist in the treatment of peptic ulcer disease in children. *J Pediatr Gastroenterol Nutr* 1989;8:41-6.
  - 13 Glupczynski Y, Burette A, Labbe M, et al. *Campylobacter pylori*-associated gastritis: a double-blind placebo-controlled trial with amoxicillin. *Am J Gastroenterol* 1988;83:365-72.
  - 14 Oderda G, Dell'Olio D, Morra I, Ansaldo N. *Campylobacter pylori* gastritis: long term results of treatment with amoxicillin. *Arch Dis Child* 1989;64:326-9.
  - 15 De Giacomo C, Maggiore G, Licardi G, Scotta MS, Fiocca R. Effects of antibacterial treatment of *Campylobacter pylori*-associated gastritis in children. *Gastroenterology* 1988;95:1699.
  - 16 Perisic VN, Sarjamovic L. *Campylobacter pylori*, resistant duodenal ulcers, and antibiotic treatment. *J Pediatr Gastroenterol Nutr* 1988;7:934-5.
  - 17 Oderda G, Vaira D, Holton J, Ainley C, Altare F, Ansaldo N. Amoxicillin plus tinidazole for *Campylobacter pylori* gastritis in children: assessment by serum IgG antibody, pepsinogen I, and gastrin levels. *Lancet* 1989;ii:690-2.
  - 18 Joffe SN, Lee FD, Blumgart LH. Duodenitis. *Clin Gastroenterol* 1978;7:635-50.
  - 19 Johnston BJ, Reed PL, Ali MH. *Campylobacter* like organisms in duodenal and antral endoscopic biopsies: relationship to inflammation. *Gut* 1986;27:1132-7.
  - 20 Kreuning J, Bosman FT, Kuiper G, Van der Wal AM. Gastric and duodenal mucosa in 'healthy' individuals. *J Clin Pathol* 1978;31:69-77.
  - 21 Brady CE, Hadfield TL, Hyatt JR, Utts SJ. Acid secretion and serum gastrin levels in individuals with *Campylobacter pylori*. *Gastroenterology* 1988;94:923-7.

See related paper on p 1278.

### Long term survival with trisomy 18

Most children with trisomy 18 survive for only a short period. Approximately 70% survive the first month, 50% the first two months, and 10% the first year. A few survive into later childhood and survival into the 20s has been known. Van Dyke and Allen (*Pediatrics* 1990;85:753-9) describe six children who lived for more than a year. One was still alive at the age of 6 years but the other five had died at between 13 and 29 months of either heart disease or pneumonia. The main physical management problems in long term survivors are feeding problems, infection, congenital heart disease, and scoliosis due to hemivertebrae. The authors emphasise the importance of sympathetic psychosocial management for the family unit, the recognition of reactive and preparatory grief in the family, and the provision of a coordinated team approach.

ARCHIVIST