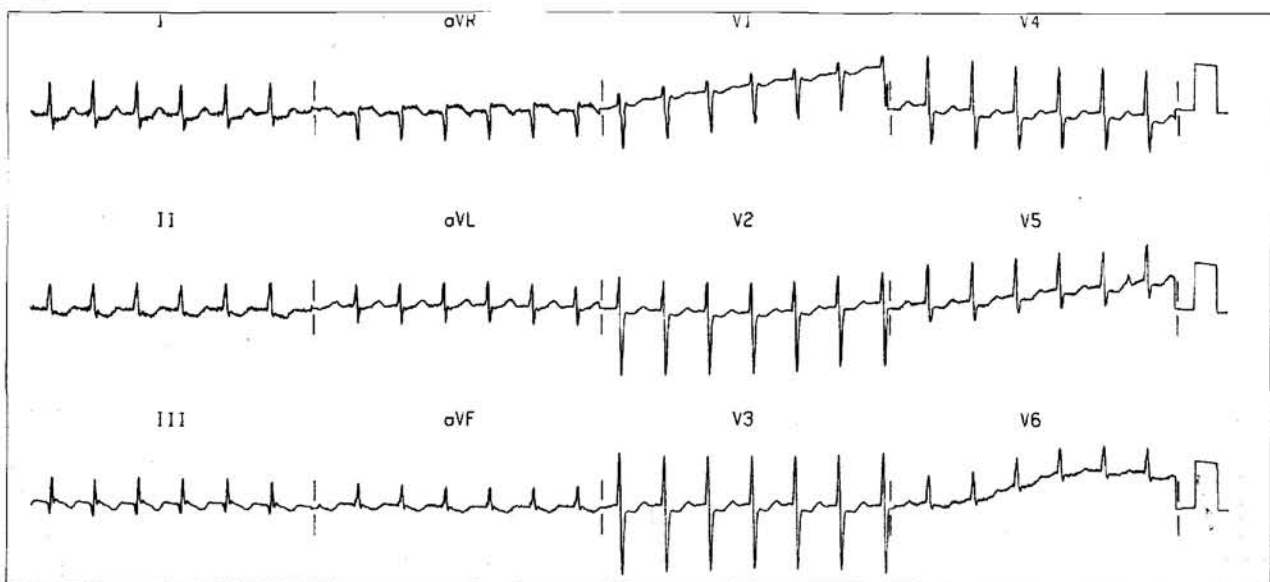


A 40-Year-Old Lady With Palpitation

Clinical History:

A 40-year-old lady attended the Accident and Emergency Department with 2 hours history of palpitation and mild shortness of breath. Her blood pressure was 160/90. The following ECG strip was obtained.

Figure 1



Question 1: What was the diagnosis?

- A. Acute Myocardial Infarction
- B. Ventricular Tachycardia
- C. Sinus Tachycardia
- D. Supraventricular Tachycardia

This ECG Round was prepared by: **Dr. S.H. Wan**
Department of Medicine & Geriatrics
Tuen Mun Hospital
Prof. C.P. Lau
Department of Medicine
The University of Hong Kong

Address for correspondence: Dr Siu-hong Wan, Cardiology, Department of Medicine & Geriatrics, Tuen Mun Hospital, New Territories, Hong Kong.

ECG ROUND

Answer : D. Supraventricular Tachycardia

The electrocardiogram showed a regular, narrow complex tachycardia with a rate of 160 per minute. No definite P waves were seen before or after the QRS complex. The ECG was compatible with supraventricular tachycardia (SVT). The P wave morphology and the relationship of the P wave to the QRS complex during SVT are very useful to identify the different forms of SVT. P waves inverted in the inferior leads can represent re-entry using the atrioventricular junction (atrioventricular nodal re-entry or atrioventricular re-entry using a bypass tract) or a low atrial tachycardia. In atrioventricular nodal re-entry, the P wave is usually buried within the QRS complex or results only in a slurring of the terminal QRS. Re-entry using a bypass tract almost always has a shorter R-P interval than P-R interval.¹ In this case, during the SVT, the P wave is not seen and is buried within the QRS complex.

In acute myocardial infarction, Q wave, ST segment elevation and T wave inversion in the respective region of the infarct is seen. In ventricular tachycardia, the QRS duration is broad (>0.14s), atrioventricular dissociation or concordance (same polarity in all chest leads V1-V6) may be present, capture or fusion beats may be seen.² In sinus tachycardia, a P wave is seen before every QRS complex.

Question 2: What would you do?

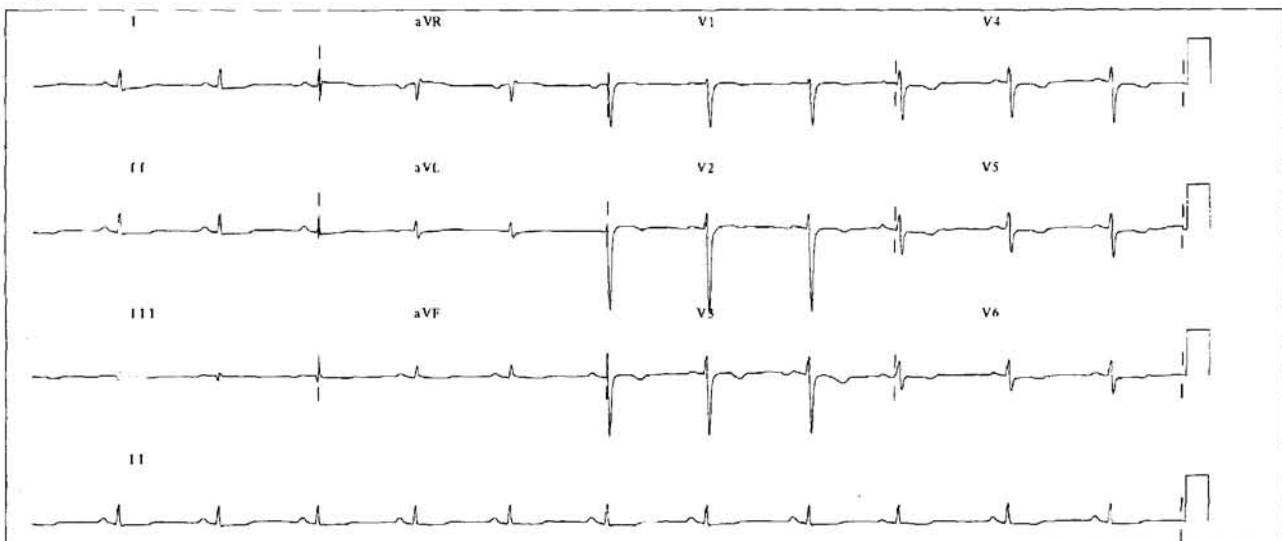
- A. A trial of vagal maneuvers
- B. Direct current (DC) cardioversion
- C. Defibrillation
- D. Adenosine bolus intravenously

Answer: A. A trial of vagal maneuvers

In patient with well tolerated supraventricular tachycardia, i.e. no significant hypotension, syncope or heart failure, a trial of vagal maneuvers should always be made. These include valsalva maneuvers, carotid sinus massage (avoid in patients with carotid bruits and never massage both carotids simultaneously) or drinking ice cold water.

If vagal maneuvers fails, intravenous adenosine should be administered. It is a naturally occurring purine nucleoside which acts directly on the atrioventricular node within seconds after the bolus injection. In a dose of 10-20 mg, it is very effective in terminating SVT. Side effects include flushing, chest tightness and dyspnoea. It is relatively contraindicated in asthmatics. Other drugs which are useful include intravenous verapamil, diltiazem, procainamide or propafenone.³ In this patient, vagal maneuvers failed and intravenous bolus adenosine was given which terminated the tachycardia promptly. **Figure 2** showed the 12 lead ECG after the termination.

Figure 2



ECG ROUND

In patients with hypotension or if the above treatment fails, synchronise DC cardioversion should be given with adequate sedation and analgesia. Initial energy of 100J is recommended. The DC shock is synchronised to the QRS complex of the tachycardia. Non-synchronised defibrillation should never be given to patients with organised tachycardias. It is only reserved for ventricular fibrillation.

After the acute termination of the SVT, a 12 lead ECG should be obtained. This is very useful in comparing the P wave morphology and QRS complex. In cases with Wolff-Parkinson-White syndrome, a short PR interval and a delta wave is seen.

Long term management of patients with supraventricular tachycardia depends on the frequency and severity of the arrhythmia, response to simple vagal maneuvers and tolerability of the tachycardia. In the absence of Wolff-Parkinson-White Syndrome, initial

treatment with either digoxin, beta-blocker or calcium channel blockers may be tried. These drugs are only moderately effective but has the advantage of having minimal serious side effects. In more severe cases, drug like Class IA (e.g. quinidine, procainamide) or IC (e.g. flecainide or propafenone) antiarrhythmic agents should be considered. Recently, radiofrequency catheter ablation of the slow pathway of the atrioventricular node or the bypass tract to treat the SVT is feasible with a more than 90% success rate and a low complication and recurrence rate.³ ■

References

1. Josephson ME. *Clinical cardiac electrophysiology: Techniques and Interpretations*. 1993;9:268-269.
2. Isselbacher KJ, Braunwald E, Wilson JD, et al. *Harrison's principles of internal medicine*. 1994;198:1029-1030.
3. Crawford MH. *Current diagnosis and treatment in cardiology*. 1995; 18:220-223.

THE HONG KONG PRACTITIONER SUBSCRIPTION APPLICATION

NAME : _____

ADDRESS : _____

TEL NO. : _____

PROFESSION :

(Please tick ✓)

FAMILY PHYSICIAN

SURGEON

PHYSICIAN

STUDENT

OTHER

The subscription rate is \$300.00 per year. Student subscription rate is \$200.00 per year. For overseas surface mailing please add \$150, airmail please add \$360.

I wish to subscribe to *The Hong Kong Practitioner*.

I enclose my payment of payable to **HKCFP EDUCATION LIMITED** for subscribing to **THE HONG KONG PRACTITIONER** for the coming year 1998.

Please return completed form with payment to : *Editorial Executive,
The Hong Kong Practitioner,
8th Floor, Duke of Windsor Social Service Building,
15 Hennessy Road, Wanchai, Hong Kong.*