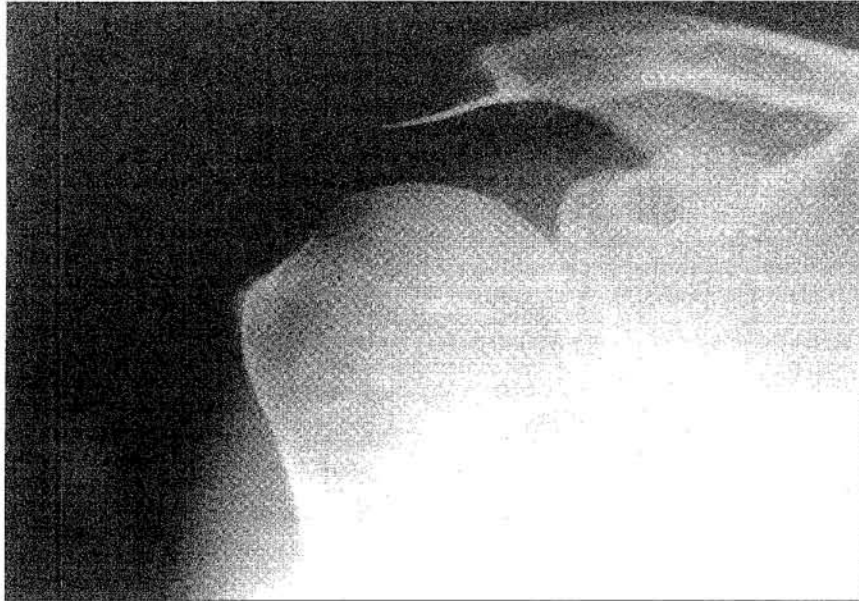

Clinical History:

A 44-year-old man presented with a painful right shoulder, worse on movement of the shoulder joint. An anteroposterior radiograph was taken. (Figure 1).

Figure 1: Anteroposterior radiograph of the right shoulder



Answer
on
page 383

What is the diagnosis?

- a) Dermatomyositis
- b) Cysticercosis
- c) Calcific rotator cuff tendinitis
- d) Synovial osteochondromatosis
- e) Tuberculous arthritis

This radiology case was prepared by:

Dr. Y. Wong,
Medical Officer.
Professor W.C.G. Peh,
Department of Diagnostic Radiology,
The University of Hong Kong,
Queen Mary Hospital.

RADIOLOGICAL CONFERENCE

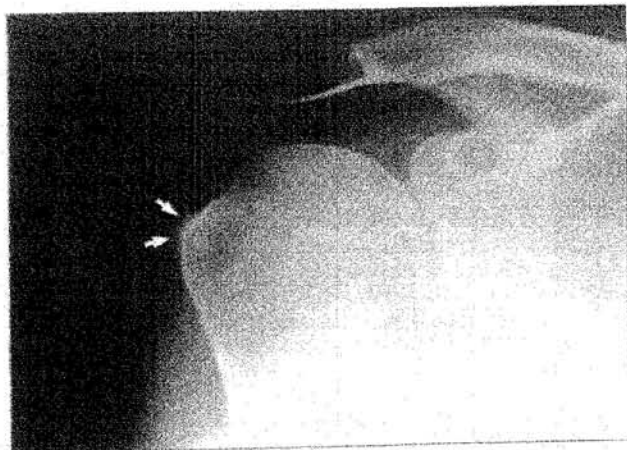
Answer:

- c) Calcific rotator cuff tendinitis

Radiological findings

Anteroposterior radiograph of the right shoulder (Figure 2) shows amorphous calcification along the tendon of the supraspinatus muscle just adjacent to its insertion into the greater tuberosity. No calcification is noted inside the glenohumeral joint or other muscle layers. The glenohumeral joint is intact. No bone erosion is present and the bone density is normal.

Figure 2: Same radiograph as Figure 1 with addition of arrows. There is amorphous calcification (arrows) of the tendon of right supraspinatus muscle just proximal to its insertion site



Discussion

Calcific rotator cuff tendinitis

Calcific tendinitis occurs as a result of calcium deposits in the rotator cuff tendon. Symptoms and signs include pain, restriction of joint movement and tenderness. The disease is particularly common in patients between 40 to 70 years of age. Radiographically, the calcific deposits occur most frequently in the

supraspinatus tendon. The right side is more often affected, although bilateral involvement is also common. Initially, the deposits are seen as thin, cloud-like, and poorly-defined radiographic densities. With time, they may appear denser, homogeneous and more sharply delineated. In some patients, the deposits remain static for long periods of time. In others, they may enlarge and change in shape.

Abrupt change in the location of calcifications may be related to extrusion from the tendon into the subacromial bursa. Sometimes, diminution in size and disappearance of calcifications may take place, especially when the patient is asymptomatic. For the treatment of this condition, a large-bore needle can be inserted into the area of the deposits, and multiple punctures performed. A second needle may be inserted into the bursa about half an inch from the original needle to remove the material through irrigation with normal saline. This interventional procedure provides dramatic relief of the patient's symptoms.

Dermatomyositis

Dermatomyositis is a disorder affecting the muscles and skin in a varying fashion. The disease usually occurs in the adults aged 40-60 years. Clinically it presents as very distinctive skin rash and plaques over the dorsum of the fingers, with features of photosensitivity. Patients may experience proximal muscle weakness and dysphagia. Respiratory muscles may be involved. Arthritis occurs in about half of involved cases, with the small joints being particularly affected. Joints are often swollen and contractures may develop in chronic cases. Soft tissue calcifications in dermatomyositis often have a characteristic appearance. They usually occur in the subcutaneous and intermuscular layers, often in the proximal portion of the limbs. Linear or curvilinear deposits are often demonstrated. The knees, elbows and fingers are commonly involved sites. Soft tissue calcifications may progress with increasing duration of disease. No subcutaneous or intermuscular calcification is seen in our patient, therefore the diagnosis of dermatomyositis can be excluded.

(Continued on page 385)

RADIOLOGICAL CONFERENCE

Cysticercosis

Cysticercosis is caused by ingestion of eggs of the pork tapeworm *Taenia solium*. Muscle weakness, tenderness, and fever occur as the larval parasites invade the intestine and infect the muscles. The brain and heart may also be involved. Radiographically, linear or oval calcifications are seen in the soft tissues and muscles. These calcifications typically have a lucent centre. The long axes of the calcified cysts usually lie in the plane of the muscle bundles. In our patient, the calcifications are not of the correct shape and lie within the tendon instead of the muscle layers, thus this diagnosis is unlikely.

Synovial osteochondromatosis

Synovial osteochondromatosis represents cartilaginous or osteocartilaginous bodies developing in the synovial membrane of joints or their communicating bursae. The condition is considered to arise from embryonic cartilage rests. The most common joints affected are the knees, hips and elbows. Patients often have a history of joint pain with limitation of movements. Intra-articular loose body formation may lead to secondary mechanical erosion of the articular cartilage with resultant osteoarthritis. Radiographically, multiple intra-articular radiodense opacities are seen ranging in size from a few millimeters to several centimeters. Typically, multiple nodules of a fairly uniform size are present. The nodules are faintly calcified initially, later becoming ossified. In our patient, the calcified densities are not intra-articular in distribution, and the ossification pattern is not that of synovial osteochondromatosis.

Tuberculous arthritis

Tuberculous arthritis is a low-grade slowly-progressive infection. It characteristically has an insidious onset with monoarticular involvement. Other lesions such as pulmonary tuberculosis may be present. Local symptoms include swelling, pain and tenderness, muscle spasm, early stiffness, and actual limitation of active and passive motion due to ankylosis. Increase in joint fluid or muscle atrophy may occur quite early in the disease course. The glenohumeral joint is occasionally affected. Radiographically, tuberculous arthritis characteristically manifests as juxta-articular osteoporosis, subchondral osseous erosion and gradual narrowing of the joint space. Gradual osteoporosis typically precedes the destructive changes. Soft tissue swelling may also be present. In our patient, the glenohumeral joint space is normal with no bony erosion or periarticular osteoporosis. Tuberculous arthritis is therefore an unlikely diagnosis. ■

References

1. Resnick D. *Bone and Joint Imaging*. 2nd ed. WB Saunders, Philadelphia, 1988;pp.1325-1329,1734-1754,2678-2685,2738,3910.
2. Dähnert W. *Radiology Review Manual*. 3rd ed. Williams and Wilkins, Baltimore, 1996;pp.19,46.
3. Murray RO, Jacobson HG, Stoker DJ. *The Radiology of Skeletal Disorders*. 3rd ed. Churchill Livingstone, London, 1990;pp.1129,1432.
4. Turek SL. *Orthopaedic Principles and Their Application*. 4th ed. J B Lippincott, Philadelphia. 1984;pp.269,455,702,929.