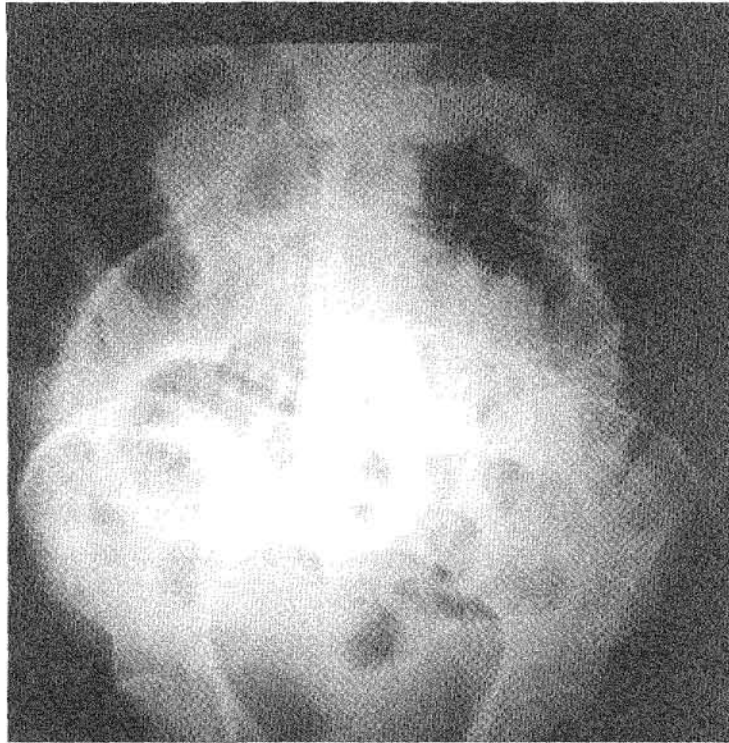

# RADIOLOGICAL CONFERENCE

## Clinical History:

A young man presented with sudden onset of abdominal pain. An abdominal radiograph was performed (Figure 1).

Figure 1: Supine abdominal radiograph



Answer  
on  
page 183

## What is the diagnosis?

- a) Pneumoperitoneum
- b) Intussusception
- c) Caecal volvulus
- d) Sigmoid volvulus
- e) Necrotising enterocolitis

This radiology case was prepared by:

**Dr. G. Li**  
**Professor W.C.G. Peh,**  
Department of Diagnostic Radiology,  
The University of Hong Kong,  
Queen Mary Hospital.

# RADIOLOGICAL CONFERENCE

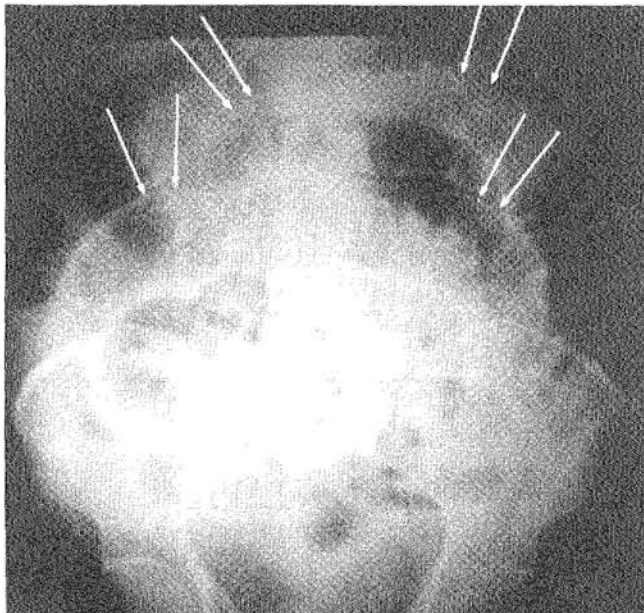
## Answer:

- a) Pneumoperitoneum

## Radiological findings

There is dilatation of gas-filled small bowel loops. The transverse folds of the valvulae conniventes of the small bowel are well visualised because of intraluminal gas. Free intraperitoneal gas on the outside of the small bowel allows identification of both the outer and inner surfaces of the bowel wall, which is seen radiographically as a thin white line (**Figure 2**).

**Figure 2:** Same radiograph as **Figure 1** with addition of arrows. Rigler's sign or the thin white stripe of the small bowel wall is clearly delineated (arrows) due to intraluminal as well as intraperitoneal gas



## Discussion

The presence of intraperitoneal air in acutely ill patients is an important radiographical observation that usually indicates bowel perforation. Various causes of free air are listed in **Table 1**.

**Table 1:** Causes of pneumoperitoneum (adapted from Ref. 3)

Perforation of viscus	- peptic ulcer - appendicitis - infarction
Iatrogenic	- surgery - peritoneal dialysis
Pneumomediastinum	
Introduction per vagina	
Pneumothorax	
Idiopathic	

Classical experimental studies by Miller and Nelson showed that as little as 1 ml of air could be detected below the right hemidiaphragm on properly-exposed chest radiographs taken with the patient in an upright position. Larger amounts may result in the following signs on abdominal radiographs:

### 1. Serosal or Rigler's sign

Normally, gas is found only in the lumen of the bowel. However, gas on both sides of the bowel may outline the bowel wall, rendering it visible as a thin, linear stripe (**Figure 2**). Since its original description by Rigler in 1941, this sign has been recognised as an important indication of pneumoperitoneum on abdominal films taken with the patient in a supine position. Overlapping loops of dilated small bowel in the mid-abdomen may however mimic this sign, so care should be taken in radiographical evaluation.

### 2. Increased lucency in the right upper quadrant

Air accumulating superiorly in the free space between the anterior aspect of the liver and the abdominal wall may cause increased lucency in the right upper quadrant. This sign can be quite subtle. Depending on the habitus of the patient, the lateral border of the air collection may be linear.

### 3. Visualisation of the undersurface of the diaphragm

Air may be trapped anteriorly in the cupola of the diaphragm, permitting visualisation of the

(Continued on page 185)

## RADIOLOGICAL CONFERENCE

undersurface of the central portion of the diaphragm. This sign is affected by the amount of air present and the orientation of the diaphragm.

#### 4. Air in Morison's pouches (posterior hepatorenal space)

Morison's pouch is an intraperitoneal recess that is bounded anteriorly by the liver and posteriorly by the right kidney. Air in Morison's pouch is characterised radiographically by a linear or triangular collection of gas in the right upper quadrant outside the expected location of the bowel.

#### 5. Outline of the normal peritoneal ligaments

With larger amounts of free air, structures such as the falciform ligament in the upper abdomen, the lateral umbilical ligaments (inverted V sign) in the lower abdomen, and the urachus may occasionally be visualised.

#### 6. "Football" sign

Originally described by Miller in infants, this sign indicates a large amount of free air filling the oval-shaped peritoneal cavity, mimicking an American football. This sign has limited value in adults.

#### 7. Air in the lesser sac of the peritoneal cavity

Intraperitoneal air may occasionally enter the foramen of Winslow and become loculated in the lesser sac. This gas collection may manifest as an ill-defined lucency above the lesser curvature of the stomach.

### Intussusception

Intussusception is defined as the telescoping of one segment of bowel into an adjacent one. It accounts for approximately 80% - 90% of bowel obstruction in infants and children. In children, the usual site of intussusception begins in the distal ileum; in 90% of cases, the cause is idiopathic. In contrast, intussusception in adults is relatively rare; accounting for only 5% of mechanical intestinal obstruction. The presence of an abdominal mass and passage of blood per rectum raises suspicion of this diagnosis. Because adult intussusception is often

chronic and relapsing, the diagnosis is suggested by recurrent episodes of subacute obstruction.

If the intussusception is of the ileocolic or colocolic variety, the "crescent" sign may be seen on radiographs. This sign is due to invagination of the intussusceptum (prolapsed segment of bowel) into the intussusciens (lumen of adjacent bowel). The intraluminal gas trapped between the two intestinal surfaces appears as a semilunar lucency. This lucent crescent is wider in diameter than normal bowel and a round soft tissue density, representing the mass created by the intussusception, is often superimposed. A more central and less distinctive lucent arc may be seen, representing trapped gas situated in lumen of the intussusciens. None of these clinical or radiographical signs were present in our patient.

### Caecal volvulus

Caecal volvulus refers to a condition characterised by a rotational twist of the right colon on its axis associated with folding of the right colon, such that the caecum is located in the mid-abdomen or left upper quadrant. Caecal volvulus occurs only when the right colon is incompletely fused to the posterior parietal peritoneum, an embryological variant present in 10% - 37% of normal adults. On radiographs, a dilated, air-filled caecum in an ectopic location, usually with the caecal apex in the left upper quadrant is characteristically seen. The medially-placed ileocaecal valve may produce a soft tissue indentation, so that the gas-filled caecum has the appearance resembling a coffee bean or kidney. Usually, little gas is seen in the distal colon. If the ileocaecal valve is incompetent, refluxed gas within the small bowel may erroneously suggest small bowel obstruction. A contrast enema shows typical beaking at the point of the volvulus in the mid-ascending colon. Caecal volvulus is likely to occur in a variety of clinical settings, including colonoscopy, barium enema, obstructive lesions in the distal colon, and pregnancy. These features were not seen in our case.

### Sigmoid volvulus

The radiographical appearance of sigmoid volvulus consists of a dilated loop of sigmoid colon that has an

# RADIOLOGICAL CONFERENCE

inverted U configuration and absent haustra. The dilated bowel commonly extends into the upper abdomen above the transverse colon. The bowel may be located in the midline, or it may be directed towards the right or left upper quadrants, where it can elevate the hemidiaphragm. Because sigmoid volvulus represents a closed loop obstruction, there is usually a considerable amount of gas in the proximal colon. Gas may also be present in the small intestine. The apposed inner walls of the sigmoid colon may occasionally form a dense white line which points towards the pelvis. Absence of rectal gas is also an important finding. Sigmoid volvulus tends to occur in elderly males and residents of nursing homes and mental hospitals, in whom chronic constipation and medication are predisposing factors for gaseous distention of the sigmoid colon. Patients with sigmoid volvulus may present with abdominal pain and distention attributable to colonic obstruction. Constipation and vomiting are also common findings. The symptoms are usually acute, but may have a gradual onset in some patients.

## Necrotising enterocolitis

Necrotising enterocolitis is a life-threatening process that primarily affects the gastrointestinal tract of premature infants. The following signs and symptoms

usually develop in the first two weeks of life: increasing gastric volume, abdominal distention, bloody stools, lethargy, and changing respiratory status. Specific radiographical features are pneumoperitoneum, fixed bowel loop on sequential studies, and portal venous gas. Other findings include gastric dilatation, a persistently dilated bowel loop, or an unchanging bowel gas pattern. Pneumatosis intestinalis presents later, and large collections of intramural gas create a linear streaky pattern that parallels the bowel wall. In our patient, this diagnosis can be excluded based on the age group and radiographical features. ■

## References

1. Rice RP, Thompson WM, Gedgandas TK. The diagnosis and significance of extraluminal gas in the abdomen. *Radiol Clin North Am.* 1982;20:819-837.
2. Grainger RG, Allison D. *Grainger & Allison's Diagnostic Radiology: A Textbook of Medical Imaging.* 3rd ed. New York: Churchill Livingstone, 1997;pp897-900.
3. Chapman S, Nakielny R. *Aids to Radiological Differential Diagnosis.* 2nd ed. London: Bailliere Tindall, 1990; pp168-169.
4. Dähnert W. *Radiology Review Manual.* 4th ed. Baltimore: Williams & Wilkins, 1999;pp463.
5. Miller RE. The technical approach to the acute abdomen. *Semin Roentgenol* 1973;8:267-269.
6. Figiel LS, Figiel SJ. Lesions of the large intestine producing acute symptoms. *Radiol Clin North Am* 1964;2:33-54.