



Adrenal lipomatous tumours: a 30 year clinicopathological experience at a single institution

K Y Lam and C Y Lo

J. Clin. Pathol. 2001;54;707-712

Updated information and services can be found at:
<http://jcp.bmjournals.com/cgi/content/full/54/9/707>

These include:

References

This article cites 25 articles, 3 of which can be accessed free at:
<http://jcp.bmjournals.com/cgi/content/full/54/9/707#BIBL>

Rapid responses

You can respond to this article at:
<http://jcp.bmjournals.com/cgi/eletter-submit/54/9/707>

Email alerting service

Receive free email alerts when new articles cite this article - sign up in the box at the top right corner of the article

Topic collections

Articles on similar topics can be found in the following collections

[Other Endocrinology](#) (621 articles)
[Other Pathology](#) (223 articles)
[Other Surgery](#) (286 articles)
[Cancer:other](#) (950 articles)

Notes

To order reprints of this article go to:
<http://www.bmjournals.com/cgi/reprintform>

To subscribe to *Journal of Clinical Pathology* go to:
<http://www.bmjournals.com/subscriptions/>

Adrenal lipomatous tumours: a 30 year clinico-pathological experience at a single institution

K Y Lam, C Y Lo

Abstract

Aims—Fatty tumours of the adrenal gland are uncommon and their features have received little attention in the literature. The aim of this study is to analyse the features of adrenal lipomatous tumours.

Methods—The histological features of primary adrenal tumours reported over a 30 year period (1970 to 1999) in Queen Mary Hospital, Hong Kong were reviewed and the clinicopathological features of adrenal lipomatous tumours were analysed.

Results—Adrenal lipomatous tumours were noted in 20 patients (12 men, eight women), and they accounted for 4.8% of the primary adrenal tumours reported. The adrenal fatty tumours comprised 11 myelolipomas, three lipomas, three teratomas, two angiomyolipomas, and one liposarcoma. Calcification or bone was noted in one third (seven of 20) of the adrenal tumours. In some fatty tumours (myelolipoma and angiomyolipoma), the fatty component may be inconspicuous. This is the first report in the English literature of angiomyolipoma and liposarcoma of the adrenal gland.

Conclusions—Different types of fatty tumours were noted in the adrenal gland. A high index of suspicion should be maintained with an aim of surgical treatment for selected patients with large and symptomatic adrenal lipomatous lesions. Histological confirmation is needed for diagnosis.

(*J Clin Pathol* 2001;54:707–712)

Keywords: myelolipoma; lipoma; angiomyolipoma; liposarcoma; adrenal

Primary adrenal tumours encountered in clinical practice are often functioning tumours, such as adrenal cortical adenomas or pheochromocytomas.¹ However, the importance of asymptomatic adrenal masses discovered incidentally during the investigation of unrelated problems was stressed by Geelhoed and Drury in 1982.² With the increased availability of high resolution ultrasonography, computed tomography (CT), and magnetic resonance imaging (MRI), incidental adrenal lesions are increasingly reported. This leads to dilemmas in the evaluation and management of these lesions.³ Adrenal tumours of uncommon pathology were more frequently reported.

Myelolipoma is included as one of the differential diagnoses for incidental adrenal lesions.⁴ Other lipomatous lesions were rarely described in the English literature.^{5–10} In our study, we reviewed the clinicopathological features of adrenal lipomatous tumours encountered in

our hospital. Most were discovered as incidental adrenal lesions. In addition, rare pathology not previously documented in the adrenal gland will be described.

Methods

The histological reports of primary adrenal tumours between 1 January 1970 and 31 December 1999 were retrieved. Tumours with adipose tissue as the sole or one of the major components were selected for review. In each case, the clinical presentation, location of the tumour, and the outcome for the patient were studied. Details of the pathological examination, including the gross appearance and size of the tumours, were noted. Immunohistochemical studies (using antibodies against muscle specific actin, desmin, HMB45, etc) were undertaken when necessary to confirm the diagnoses. Flow cytometry for ploidy analysis was used to analyse tumours with atypical histological features by adopting the previously described methodology.¹¹

Results

Twenty patients (12 men, eight women) with adrenal lipomatous tumours were noted (table 1). Ten tumours each were obtained from surgical biopsy and postmortem files. The tumours comprised myelolipoma, lipoma, teratoma, angiomyolipoma, and liposarcoma. Some of these cases have been reported previously.^{10 12 13} Over the 30 year study period, 418 primary adrenal tumours were recorded in the pathology file. Of these, 238 were from the surgical biopsy files and 180 from the postmortem files (from a total of 13 732 necropsies). Thus, adrenal lipomatous tumours comprised 4.8% (20 of 418) of primary adrenal tumours. These tumours accounted for 4.2% (10 of 238) of the surgically resected and 5.6% (10 of 180) of necropsy detected primary adrenal tumours detected. The prevalence of adrenal lipomatous tumours was 0.07% at necropsy.

MYELOLIPOMAS (CASES 1 TO 11)

Eleven adrenal myelolipomas were found and they accounted for 2.6% of the primary adrenal tumours. Eight tumours were detected during necropsy, giving a postmortem prevalence of 0.06%, whereas three resected myelolipomas accounted for 1.3% of the surgically resected primary adrenal tumours. These three patients presented with adrenal “incidentalomas” on cross sectional imagings. They were free of disease 12 years, 4.5 years, and 0.5 years after excision of the adrenal tumours.

There were eight men and three women with a mean age of 62 years (range, 41–81) at the time of surgery or necropsy. No hormonal dysfunction was noted in these patients. Six

Department of Pathology, University of Hong Kong Medical Centre, Queen Mary Hospital, 102 Pokfulam Road, Hong Kong, China
K Y Lam

Department of Surgery, University of Hong Kong Medical Centre
C Y Lo

Correspondence to:
Dr Lam
akylam@hotmail.com

Accepted for publication
17 January 2001

Table 1 Features of adrenal lipomatous tumours in Hong Kong

Case	Diagnosis	Sex/Age	Side	Diameter/weight	Follow up	Presentation	Cal/Bone
1	Myelolipoma	F/65	Right	12 cm/180 g	12 years	Incidental ultrasonographic finding	+
2	Myelolipoma	M/41	Left	14.5 cm/1018 g	4½ years	Incidental CT scan finding	+
3	Myelolipoma	M/65	Right	3.5 cm/12.6 g	1 year	Right loin pain	-
4	Myelolipoma	M/61	Right	9.0 cm/210 g	—	*Died of ruptured cerebral aneurysm	-
5	Myelolipoma	M/81	Left	0.3 cm/9 g	—	*Died of bronchopneumonia	-
6	Myelolipoma	M/45	Right	0.8 cm/7 g	—	*Died of gastric carcinoma	+
7	Myelolipoma	M/42	Right	1.5 cm/8 g	—	*Died of alcoholic liver cirrhosis	-
8	Myelolipoma	F/81	Left	0.7 cm/4 g	—	*Died of ruptured aortic aneurysm	-
9	Myelolipoma	F/84	Right	3.0 cm/93 g	—	*Died of lymphoma	-
10	Myelolipoma	M/66	Left	0.4 cm/5 g	—	*Died of amyloidosis	-
11	Myelolipoma	M/51	Left	1.5 cm/7 g	—	*Died of hepatocellular carcinoma	-
12	Lipoma	F/64	Right	8.0 cm/190 g	7 years	Incidental ultrasonographic finding	-
13	Lipoma	M/65	Left	2.0 cm/NA	—	*Died of ischaemic heart disease	-
14	Lipoma	M/78	Right	4.5 cm/24 g	—	*Died of perforated gastric ulcer	+
15	Teratoma	F/18	Left	11.0 cm/67 g	7 years	Back pain for 1 month	+
16	Teratoma	M/17	Right	7.5 cm/74 g	1 year	Back pain for 1 year	+
17	Teratoma	F/37	Left	10.0 cm/NA	8 years	Back pain for 2 months	+
18	Angiomyolipoma	F/46	Left	8.0 cm/115 g	1 year	Incidental CT scan finding	-
19	Angiomyolipoma	M/20	Left	0.2 cm/3 g	8 years	Incidental finding at nephrectomy	-
20	Liposarcoma	F/36	Right	18.0 cm/783 g	2 years	Right loin pain	-

*Incidental finding at necropsy.

Cal/Bone, calcification or bone noted in the tumour stroma; CT, computed tomography; NA, data not available.

tumours were found in the right and five in the left adrenal gland. The myelolipomas were composed of a mixture of mature adipose tissue and haematopoietic elements. Lipomatous and myeloid components were dominant in six and five cases, respectively, and calcium deposition was noted in three cases.

The mean diameter of the adrenal myelolipomas was 4.3 cm (range, 0.3–14.5) and the mean weight of the adrenal gland was 141 g (range, 4–1018). Eight tumours were less than 4 cm in diameter and weighed less than 100 g. Seven of the eight tumours discovered at necropsy were \leq 3 cm in size. The patient with a large myelolipoma (case 4) died of ruptured cerebral aneurysm. The tumour weighed 210 g and was 9 cm in diameter. The largest myelolipoma (case 2) presented as a huge fatty tumour incidentally shown by CT scan. The preoperative differential diagnoses included angiomyolipoma of kidney and retroperitoneal liposarcoma. The resected tumour was 14.5 cm in size and weighed 1018 g. Another large myelolipoma was a dumb bell shaped tumour (case 1). The clinical diagnosis was an adrenal lipomatous tumour. The tumour

weighed 180 g and was composed of two parts; one was 6.5 cm in diameter and the other was 5.5 cm in diameter (fig 1). The remaining patient underwent surgical resection of a 3.5 cm right adrenal myelolipoma because of the presence of non-specific loin pain.

LIPOMAS (CASES 12–14)

Three patients (two men, one woman) with adrenal lipomas were found. These cases accounted for 0.7% of the primary adrenal tumours. The lipomas were composed of mature adipose tissue and focal calcification was noted in one case (fig 2).

Two lipomas were from postmortem files (cases 13 and 14), giving a postmortem prevalence of 0.02%. The one lipoma from the biopsy file (case 12) accounted for 0.4% of the surgically resected primary adrenal tumours. The patient was a 64 year old woman presenting with a history of rectal carcinoma. A right hyperechogenic adrenal mass was discovered on preoperative ultrasonographic examination and was suspected to be metastatic adenocarcinoma. The adrenal mass was resected and an 8 cm lipoma that weighed 190 g was noted histologically. The patient was free of disease seven years after excision of the adrenal lipoma.

TERATOMA (CASES 15–17)

Three patients (two women, one man) with teratomas were noted. They presented with non-specific back pain and adrenal masses

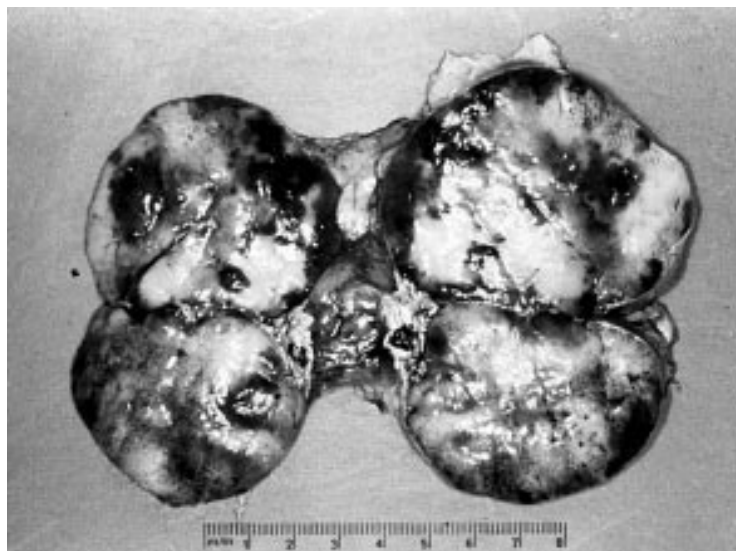

Figure 1 A dumb bell shaped myelolipoma (case 1).

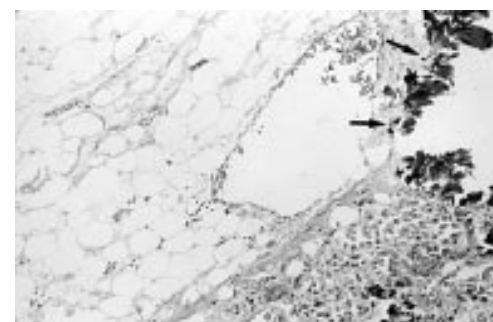
Figure 2 An adrenal lipoma (case 14) with dystrophic calcification noted (arrows). Haematoxylin and eosin stained; original magnification, \times 165.

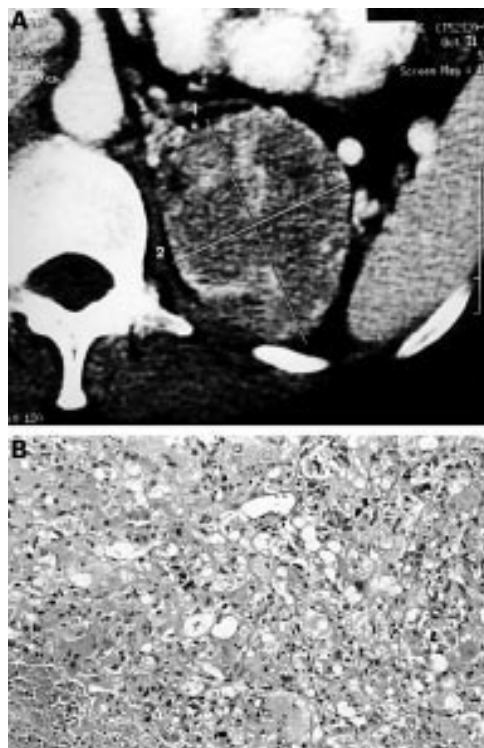

Figure 3 (A) Computerised tomography scan of an adrenal angiomyolipoma (case 18) showing an adrenal mass of heterogenous contrast enhancement. (B) Photomicrograph of the same adrenal angiomyolipoma showing the predominant epithelioid cells component. Haematoxylin and eosin stained; original magnification, $\times 200$.

were detected on imaging. They accounted for 1.3% of the surgically resected primary and 0.7% of all primary adrenal tumours. The tumours were composed of mature tissues arising from more than one germinal layer. All tumours contained a large fatty component as well as calcification/bone. Surgery was carried out because of the sizes of the tumours (diameters, 7.5 cm, 10 cm, and 11 cm, respectively). No immature elements or malignancy was noted in the tumours. The patients were free of disease at one, seven, and eight years after surgery.

ANGIOMYOLIPOMAS (CASES 18, 19)

Two patients with adrenal angiomyolipomas were diagnosed after adrenalectomy. They accounted for 0.5% and 0.8% of the primary and surgically resected primary adrenal tumours, respectively.

A 46 year old woman presented with postoperative fever after oophorectomy for a left ovarian cystic teratoma (case 18). CT scan showed a heterogeneous mass 8 cm in size arising from the medial limb of the left adrenal gland (fig 3A). Hormonal evaluation failed to reveal abnormal adrenal function. An open left adrenalectomy was performed for suspected adrenocortical carcinoma. The tumour was fleshy and haemorrhagic. It was composed of mainly epithelioid and spindle cells (fig 3B); some of these formed giant cells. Intranuclear pseudoinclusions were noted in some tumour cells. Immunohistochemical staining was positive for desmin, muscle specific actin, and

HMB45, but was negative for cytokeratins (Mak-6, CAM 5.2) and epithelial membrane antigen. The cells were separated by numerous thick walled blood vessels with frequent foci of haematoma. Some of the vessels showed hyaline deposits in the wall and occasional foci of adipocytes were noted. On flow cytometric analysis, the tumour was found to be diploid. The patient was free of disease one year after surgery.

A 20 year old man (case 19) suffered from tuberous sclerosis. He presented with haematuria and left loin pain, and radiological examination showed multiple lesions in both kidneys. The clinical diagnosis was multiple angiomyolipomas. On laparotomy, a liver nodule was also noted. The patient underwent left radical nephrectomy and biopsy of the liver nodule. Histological examination showed angiomyolipomas of the kidney, adrenal, and liver. The patient was alive eight years after surgery.

On histological examination of the radical nephrectomy specimen, a circumscribed focus of yellowish tissue (0.2 cm in diameter) was present inside the adrenal gland. The tumour contained mainly adipose tissue interspersed with small capillaries. Spindle cells and epithelioid cells positive for muscle specific actin, desmin, and HMB45 were also present.

LIPOSARCOMA (CASE 20)

A patient with adrenal liposarcoma was noted in the surgical biopsy files. The tumour accounted for 0.2% and 0.4% of primary and surgically resected primary adrenal tumours, respectively. The patient presented after complaining of right flank pain for three weeks. A cystic right adrenal tumour was detected on ultrasonographic, CT, and MRI examinations (fig 4A). Intrauterine pregnancy was concomitantly confirmed. Adrenal cortical carcinoma was suspected and during surgery an extremely large cystic tumour, 18 cm in diameter, was noted in the right adrenal gland, with displacement of the right kidney anteromedially. A 783 g tumour was resected and termination of pregnancy was also performed. The patient was free of disease two years after surgery.

On microscopic examination, the tumour had a thick fibrous capsule and a myxoid stroma. Numerous branching thin walled blood vessels giving a plexiform appearance were noted. Tumour cells with features of lipoblasts and occasional giant cells (fig 4B) were prominent and, in some areas, they were cellular. Some of these tumour cells had round cell morphology. Mitotic figures, cystic degeneration, haemorrhages, and necrosis were present. The features were compatible with a round cell liposarcoma (poorly differentiated myxoid liposarcoma). Flow cytometric analysis showed that the tumour cells were diploid.

Discussion

Lipomatous tumours in adrenal glands are uncommon. In our study, the adrenal lipomatous tumours comprised 4.8% of the primary adrenal tumours noted in the 30 year period. They presented as non-specific back pain or

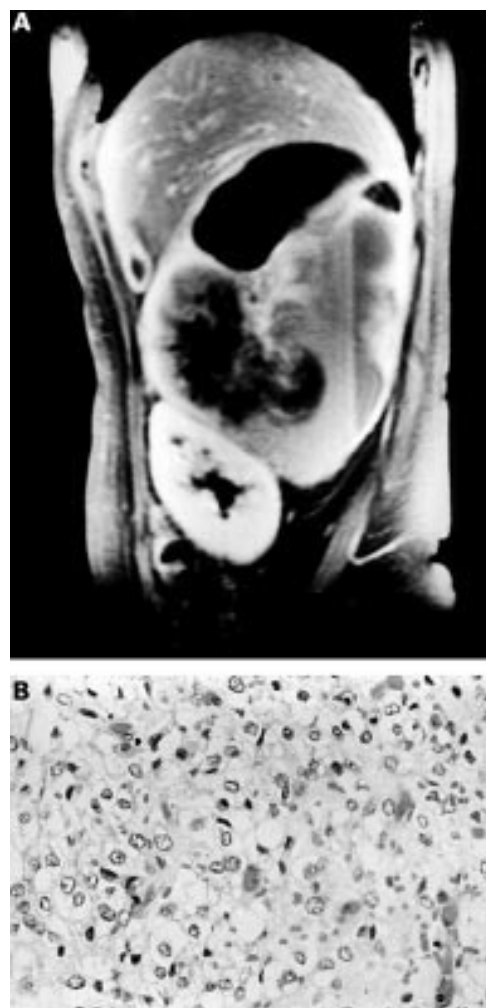


Figure 4 (A) Magnetic resonance imaging showing a cystic right adrenal liposarcoma (case 20). (B) Photomicrograph of the same adrenal liposarcoma showing the presence of lipoblasts. Haematoxylin and eosin stained; original magnification, $\times 500$.

incidental findings by imaging and necropsy. Apart from myelolipoma, rare tumours such as lipoma, teratoma, angiomyolipoma, and liposarcoma were also found.

Myelolipoma is the most common fatty tumour of the adrenal gland.⁴ The tumour is composed of mature adipose tissue and haematopoietic elements, and the tumour is thought to arise from metaplasia of undifferentiated stromal cells.¹² Reports on large series of patients with adrenal myelolipomas are lacking. In the English literature, Han *et al* and Kenney *et al* performed a review of 20 and 46 patients with myelolipomas, respectively, based on radiological features without complete

pathological examination in most patients.^{14 15} In our series, 11 patients with histologically confirmed adrenal myelolipomas were found and it is, by far, the largest series reported. The 11 adrenal myelolipomas accounted for 2.6% of the primary adrenal tumours. Of these, three myelolipomas were surgically removed, accounting for 1.3% of surgical resected primary adrenal tumours. Eight tumours were from postmortem files, giving a postmortem prevalence of 0.06%. The postmortem prevalence is slightly lower than that of other series, which ranged from 0.08% to 0.2%.¹⁶ In our series, the prevalence is probably accurate because it is based on a large number of necropsies analysed. In addition, microscopic examination of the adrenal glands was routinely performed at necropsy in our institution. However, racial differences may account for the low postmortem prevalence of myelolipoma in Hong Kong.

Similar to adrenal myelolipomas reported in the literature, we noted that myelolipomas were often diagnosed as either incidental radiological or postmortem findings.¹⁷ The tumours were usually noted in late adult life (age range, 41–84 years; mean, 62). They were equally distributed on each side. In the literature, there was no sex difference reported, although a male predominance was noted in our series.

Myelolipomas are usually less than 4 cm in diameter but they can attain very large sizes.¹⁸ To date, the largest adrenal myelolipoma reported weighed 5900 g.¹⁹ Complications, such as rupture and retroperitoneal haemorrhage, can occur in large myelolipomas.¹⁸ In our study, the weights of the larger myelolipomas were 1018 g, 210 g, and 180 g. On microscopic examination of the 11 myelolipomas, the incidence of a predominance of either the adipose tissue or the myeloid component was approximately equal. The incidence of calcification (27%) suggested that it is a common feature in adrenal myelolipomas and that it might be a feature of benign adrenal lipomatous tumours on imaging.

In contrast to myelolipomas, adrenal lipomas are uncommon. Eight cases of adrenal lipomas (including the three cases in our series) have been described in the English literature (table 2).^{5–9 13} There was no sex predilection for adrenal lipomas. Five of the eight cases were reported in the East (three from Hong Kong, one from India, and one from Israel). More data need to be collected to determine whether there is a racial difference in the incidence of this lesion. An increasing number of adrenal lipomas have been reported recently, which may be attributable to the increasing use of

Table 2 Features of adrenal lipomas reported in the English literature

Author/year/place of publication	Age/sex	Side	Size/weight of adrenal	Presentation	Follow up	Remarks
Lange/1966/Germany ⁵	M/54	Right	2.5 cm/NA	Paroxysmal hypertension	—	Tumour detected at necropsy
Prinz/1982/USA ⁶	F/73	Right	3.0 cm/NA	Incidental finding by CT scan	—	
Avinoach/1989/Israel ⁷	F/40	Right	1.3 cm/7 g	Incidental finding at laparotomy	—	
Ghavamian/1998/USA ⁹	F/50	Left	8.0 cm/NA	Incidental finding by CT scan	—	Calcification
Sharma/1998/India ⁸	M/45	Right	12.0 cm/225 g	Abdominal pain, hypertension	1 year	
Current cases	F/64	Right	8.0 cm/190 g	Incidental finding by ultrasonography	7 years	
	M/65	Left	2.0 cm/NA	Incidental finding at necropsy	—	
	M/78	Right	4.5 cm/24 g	Incidental finding at necropsy	—	Calcification and ossification

CT, computed tomography; NA, data not available.

better imaging techniques. In addition, half (three of six) of the asymptomatic adrenal lipomas were detected by imaging techniques.

The diameter of the adrenal lipomas ranged from 1.3 cm to 12 cm (mean, 5.2). They were usually small. In recent years, large adrenal lipomas have been reported. Sharma *et al* reported a symptomatic adrenal lipoma of 12 cm in size and 225 g in weight.⁸ In our series from Hong Kong Chinese, we noted an asymptomatic 8 cm adrenal lipoma that weighed 190 g. Surgery is adopted for these large tumours because of the risk of malignancy in large adrenal tumours and for the potential relief of symptoms in some patients.

The pathogenesis of adrenal lipoma remains unknown, although adrenal myelolipoma and lipoma were believed to be the same tumour entity.⁸ However, adrenal lipomas had a right side predominance (75%), whereas adrenal myelolipomas occurred in roughly equal frequency on both sides. The right side predominance of adrenal lipomas is unlikely to be the result of chance alone, and may be a clue to the origin of this tumour. More cases need to be studied to disclose the pathogenesis of adrenal lipoma.

The three adrenal teratomas have been reported previously.¹⁰ The fatty component was dominant in each of the teratomas. In contrast to many other lipomatous tumours that were often asymptomatic, the three patients with teratomas presented with non-specific back pain. In addition, bone and calcification were present in all these cases and could be identified on radiological examination.

Angiomyolipoma is apparently part of a family of neoplasms that derive from perivascular epithelioid cells.²⁰ The tumour is a rare mesenchymal tumour that is usually found in the kidney. Extrarenal angiomyolipoma is an uncommon finding and the most common extrarenal site is the liver. In our study, we reported two angiomyolipomas from the adrenal gland. One was a small angiomyolipoma that occurred in the setting of tuberous sclerosis. This case has been described previously.¹² To the best of our knowledge, there has been no other case of adrenal angiomyolipoma documented in the English literature.

Renal angiomyolipomas are associated with tuberous sclerosis in approximately half of the cases, and in this situation the tumours are often multiple and bilateral.²⁰ The site of occurrence of multiple tumours included: (1) hepatic and renal angiomyolipomas; (2) splenic and renal angiomyolipomas; (3) and renal, splenic, hepatic, and pulmonary angiomyolipomas. In the two adrenal angiomyolipomas reported in our study, one occurred in the setting of tuberous sclerosis and the other was a sporadic angiomyolipoma. The sporadic case was noted in a 46 year old woman with an 8 cm tumour that weighed 115 g. The case associated with tuberous sclerosis showed the unusual occurrence of renal, hepatic, and adrenal angiomyolipomas.

Angiomyolipomas predominately composed of smooth muscle cells are known diagnostic challenges to pathologists.²¹ They have also

been named epithelioid or atypical angiomyolipoma.²⁰⁻²² The common feature of this group of tumours is that the adipose tissue is inconspicuous. The tumour cells may have nuclear pleomorphism and multinucleated tumour giant cells. They are often misdiagnosed as sarcomatoid carcinoma, carcinoma, or sarcoma. Some of these tumours have malignant potential and recur locally. The sporadic adrenal angiomyolipoma reported in our series also belongs to this category. The positivity to HMB45 of these epithelioid or spindle tumour cells is the clue to the diagnosis. A diligent search for adipocytes and abnormal blood vessels may help in confirming the diagnosis.

Large angiomyolipomas should be removed surgically because of the risk of spontaneous tumour rupture owing to the presence of abundant and abnormal elastin-poor vascularity in the tumour.²⁰ In our study, the patient with sporadic adrenal angiomyolipoma underwent surgery because of the size of the tumour. The tumour was found to be diploid. Nevertheless, follow up is necessary because of the atypical morphology.

Liposarcoma is the most common adult soft tissue sarcoma.²³ Myxoid/round cell liposarcoma is a variant of liposarcoma that affects slightly younger adults (in the third to fifth decades) than the other types.²³ The two major sites of the tumour are the extremities and the retroperitoneum. To the best of our knowledge, primary adrenal liposarcoma has not been reported in the English literature. The adrenal liposarcoma reported in our series occurred in a 36 year old woman with the classic features of myxoid liposarcoma. It is likely that the adrenal liposarcoma originated from undifferentiated stromal cells in the adrenal gland. In addition, the presence of prominent foci of round cell differentiation and tumour necrosis suggests that it belongs to an aggressive subgroup of myxoid liposarcoma, known as round cell liposarcoma. Although the adrenal liposarcoma was found to be diploid by flow cytometry, follow up for local recurrence or distant metastases is necessary.

One unusual feature of the adrenal liposarcoma was the extensive area of cystic degeneration. Liposarcoma with cystic degeneration has been reported in other sites.²⁴⁻²⁵ The radiological appearance may simulate a benign cystic lesion. This feature stresses the importance of investigating the possibility of malignancy in cystic masses. In adrenal liposarcoma, the large size of the tumour alerts the clinician to the diagnosis of adrenal cortical carcinoma. As a result, liposarcoma should be included in the list of differential diagnoses of large adrenal fatty tumour.

To conclude, different types of lipomatous tumours can be found in the adrenal gland. They are often asymptomatic and usually present as "incidentalomas". This group of tumours comprised myelolipoma, lipoma, teratoma, angiomyolipoma, and liposarcoma. They should be included in the differential list of fatty adrenal masses. The tumours may rupture or can cause symptoms because of their

size. In addition, clinically aggressive tumours, such as epithelioid angiomyolipoma and liposarcoma, can occur. However, current imaging techniques cannot reliably distinguish the different types of tumours. A high index of suspicion should be maintained with an aim of surgical treatment for selected patients with large and symptomatic adrenal lipomatous lesions.

- 1 Lam KY. Adrenal tumours in Chinese. *Virchows Arch A Pathol Anat Histopathol* 1992;421:13–16.
- 2 Geelhoed GW, Drury EM. Management of the adrenal "incidentaloma". *Surgery* 1982;92:866–74.
- 3 Gajraj H, Young AE. Adrenal incidentaloma. *Br J Surg* 1993;80:422–6.
- 4 Kasperlik Zeluska AA, Roslonowska E, Slowinska Srzednicka J, et al. Incidentally discovered adrenal mass (incidentaloma): investigation and management of 208 patients. *Clin Endocrinol* 1997;46:29–37.
- 5 Lange HP. Lipoma of the adrenal gland simulating the signs of pheochromocytoma. *Ger Med Mon* 1966;11:190–2.
- 6 Prinz RA, Brooks MH, Churchill R, et al. Incidental asymptomatic adrenal masses detected by computed tomographic scanning. Is operation required? *JAMA* 1982;248:701–4.
- 7 Avinoach I, Robinson CR, Avinoach E, et al. Adrenal lipoma: a rare tumour of the adrenal gland. *Histopathology* 1989;15:195–6.
- 8 Sharma MC, Gill SS, Kashyap S, et al. Adrenal lipoma: a case report. *Urol Int* 1998;60:245–7.
- 9 Ghavamian R, Pullman JM, Menon M. Adrenal lipoma: an uncommon presentation of the incidental asymptomatic adrenal mass. *Br J Urol* 1998;82:136–7.
- 10 Lam KY, Lo CY. Teratoma in the region of adrenal gland: a unique entity masquerading as lipomatous adrenal tumor. *Surgery* 1999;126:90–4.
- 11 Lam KY, Ma L, Law SY, et al. Use of flow cytometry in the analysis of stage III squamous cell carcinoma of the esophagus and its association with MIB-1. *J Clin Pathol* 1996;49:975–8.
- 12 Lam KY. Lipomatous tumors of the adrenal gland: clinicopathologic study of eight cases. *J Urol Pathol* 1995;3:95–106.
- 13 Lam KY, Chan ACL, Ng IO. Giant adrenal lipoma: a report of two cases and review of literature. *Scand J Urol Nephrol* 1997;31:89–90.
- 14 Han M, Burnett AL, Fishman EK, et al. The natural history and treatment of adrenal myelolipoma. *J Urol* 1997;157:1213–16.
- 15 Kenney PJ, Wagner BJ, Rao P, et al. Myelolipoma: CT and pathologic features. *Radiology* 1998;208:87–95.
- 16 Sanders R, Bissada N, Curry N, et al. Clinical spectrum of adrenal myelolipoma: analysis of 8 tumors in 7 patients. *J Urol* 1995;153:1791–3.
- 17 Bayram F, Atasoy KC, Yalcin B, et al. Adrenal myelolipoma: case report with a review of the literature. *Australas Radiol* 1996;40:68–71.
- 18 Vierna J, Laforga JB. Giant adrenal myelolipoma. Report of a case and review of the literature. *Scand J Urol Nephrol* 1994;28:301–4.
- 19 Boudreaux D, Waisman J, Skinner DG, et al. Giant adrenal myelolipoma and testicular interstitial cell tumor in a man with congenital 21-hydroxylase deficiency. *Am J Surg Pathol* 1979;3:109–23.
- 20 Eble JN. Angiomyolipoma of kidney. *Semin Diagn Pathol* 1998;15:21–40.
- 21 Nonomura A, Minato H, Kurumaya H. Angiomyolipoma predominantly composed of smooth muscle cells: problems in histological diagnosis. *Histopathology* 1998;33:20–7.
- 22 Delgado R, de Leon Bojorge B, Albores Saavedra J. Atypical angiomyolipoma of the kidney: a distinct morphologic variant that is easily confused with a variety of malignant neoplasms. *Cancer* 1998;83:1581–92.
- 23 Weiss SW. Lipomatous tumors. *Monogr Pathol* 1996;38:207–39.
- 24 Sarkar K, Buckley C, Unthoff HK. Liposarcoma simulating a Baker's cyst: a case study. *Arch Orthop Trauma Surg* 1986;105:316–19.
- 25 Geltinger S, Thewes M, Abeck D, et al. A pleomorphic liposarcoma imitated a subcutaneous cyst. *Acta Derm Venereol* 1997;77:482–3.

Want full access but don't
have a subscription?

Pay per access

For just US\$25 you can have instant access to the whole website for 30 days. During this time you will be able to access the full text for all issues (including supplements) available. You will also be able to download and print any relevant pdf files for personal use, and take advantage of all the special features *Journal of Clinical Pathology* online has to offer.

www.jclinpath.com