



Can anterior vertebral body tethering provide superior range of motion outcomes compared to posterior spinal fusion in adolescent idiopathic scoliosis? A systematic review

Darren Li Liang Wong¹ · Pak Tung Mong¹ · Chun Yin Ng¹ · Chun Kwan Ong¹ · Zhekai Qian¹ · Mang Hong Shao¹ · Ling Kwan Ernest Sin¹ · Bao Yi Wong¹ · Chun Ming Wong¹ · Jason Pui Yin Cheung¹ · Michael To¹

Received: 3 March 2023 / Revised: 3 March 2023 / Accepted: 17 May 2023
© The Author(s) 2023

Abstract

Purpose Anterior vertebral body tethering (AVBT) was introduced as a fusionless alternative to treating adolescent idiopathic scoliosis (AIS) while preserving range of motion (ROM). This is the first systematic review to compare the ROM outcomes between AVBT and PSF in treating AIS.

Methods We conducted a comprehensive search on PubMed, EMBASE, MEDLINE, and Cochrane Library. Inclusion criteria were patients with AIS treated with AVBT or PSF or both, and clearly defined ROM outcomes; exclusion criteria were scoliosis other than AIS, biomechanical or cadaveric studies, non-English publications, case reports, conference summaries, unpublished literature, commentaries, and reviews. Primary outcome was ROM. Secondary outcomes included Cobb angle correction, quality of life (QOL), complications, and muscle strength and endurance.

Results Twelve studies were included in this review. We found moderate evidence to support that AVBT results in superior ROM outcomes than PSF while achieving comparable Cobb angle correction with low evidence. The comparison of QOL outcomes between AVBT and PSF remained inconclusive. In addition to the complications noted conventionally in PSF, AVBT could result in over-correction and distal adding-on. We also found very low evidence to support that AIS patients treated with AVBT have superior muscle strength and endurance when compared to those treated with PSF.

Conclusions AVBT provides better preservation of ROM and muscle strength postoperatively when compared with PSF, while achieving comparable curve correction. Future studies should explore the spinal growth trajectory to determine the window of opportunity for AVBT in AIS.

Keywords Adolescent idiopathic scoliosis · Anterior vertebral body tethering · Posterior spinal fusion · Range of motion · Mobility outcome

Introduction

Adolescent idiopathic scoliosis (AIS) is a three-dimensional (3D) spinal deformity characterized by (i) the lateral spinal curvature in the frontal plane, (ii) a disturbance of physiologic spinal curvatures in the sagittal plane, and (iii) an axial rotation of the vertebrae in the transverse plane [1–5].

The overall prevalence of AIS is 0.47–5.2% with the female-to-male ratio ranging from 1.5:1 to 3:1 [1]. If left untreated, these deformities may progress and result in back pain, cardiopulmonary problems, and psychosocial concerns [2].

The current management for AIS includes conservative and surgical treatment [6]. For conservative treatment, exercise and routine screening can be adopted for more mature patients with smaller Cobb angles, otherwise bracing will be considered for moderate curves (25–40°) [7, 8]. In unbraced patients, an initial Cobb angle of more than 25° and thoracic curves have been shown to be major predictors of curve progression [8]. For severe Cobb angles (> 40–50°), posterior spinal fusion (PSF) is considered [9, 10].

Due to the fusion of the vertebrae with screws and rods, PSF may result in some undesirable mobility outcomes,

✉ Jason Pui Yin Cheung
cheungjp@hku.hk

✉ Michael To
mikekto@hku.hk

¹ Department of Orthopaedics and Traumatology, The University of Hong Kong, Hong Kong, China

including loss of range of motion (ROM) of the fused vertebral segments, reduced capability in performing high-intensity physical activities, and increased risk of degeneration and arthritis of adjacent segments [11–13]. To overcome these limitations, anterior vertebral body tethering (AVBT) was popularized and subsequently approved by the US Food and Drug Administration (USFDA) as a non-fusion alternative in 2019 [14]. By anterior thoracoscopic or mini-open (small thoracotomy) approach, AVBT introduces tether and screws on the convex side of the spine to restrict its growth while permitting growth of the concavity until the length of spine is similar to the tethered side, correcting the scoliosis. AVBT is usually indicated in patients with single major thoracic curve 30–65° having Sanders maturity score of 3–5 [14, 15].

Compared with PSF, AVBT is expected to have greater postoperative ROM. However, there has been no systematic review demonstrating definitive improvement in postoperative ROM in patients treated with AVBT. Therefore, this study aims to compare current studies for any significant difference in post-AVBT/PSF mobility. Secondary objectives included a comparison of Cobb angle corrections, quality of life (QOL), surgical complications, and postoperative trunk strength and endurance.

Methods

Literature search strategy and selection criteria

The literature search and reporting of study results were conducted according to the Preferred Reporting Items for Systematic reviews and Meta-Analyses (PRISMA) Statement [16] and was registered on PROSPERO (CRD42022371586). Two independent investigators performed an extensive search on the following databases: PubMed, EMBASE, MEDLINE, and Cochrane Library (Fig. 1). All fields were searched in the databases using the following keywords: “adolescent idiopathic scoliosis” AND (“tether” OR “anterior growth modulation” OR “anterior vertebral body growth modulation” OR “posterior spinal*”) AND (“Range of motion” OR “flexibility” OR “mobility”). The detailed search items are included in the Supplementary Material. All articles published on or before July 31, 2022 were retrieved and screened. Potentially relevant abstracts were screened based on the inclusion and exclusion criteria (Table 1), and full-text articles were obtained for eligible results. The references of each included article were screened for any other pertinent articles. Any discrepancies in the final decision of

inclusion were settled through discussion with all authors. The search results are detailed in the results section and Fig. 1.

Data extraction

The primary outcome extracted was the ROM (Supplementary Table 1), as measured clinically, radiologically using side-bending radiographs, and dynamically using the Vissers Construction Nieuw-Vennep (VICON) motion capture system. Clinical measurements were conducted using DAVID® device (David Health Solutions Ltd., Helsinki, Finland), a goniometer or a measuring tape during physical examination.

Secondary outcomes extracted are listed below:

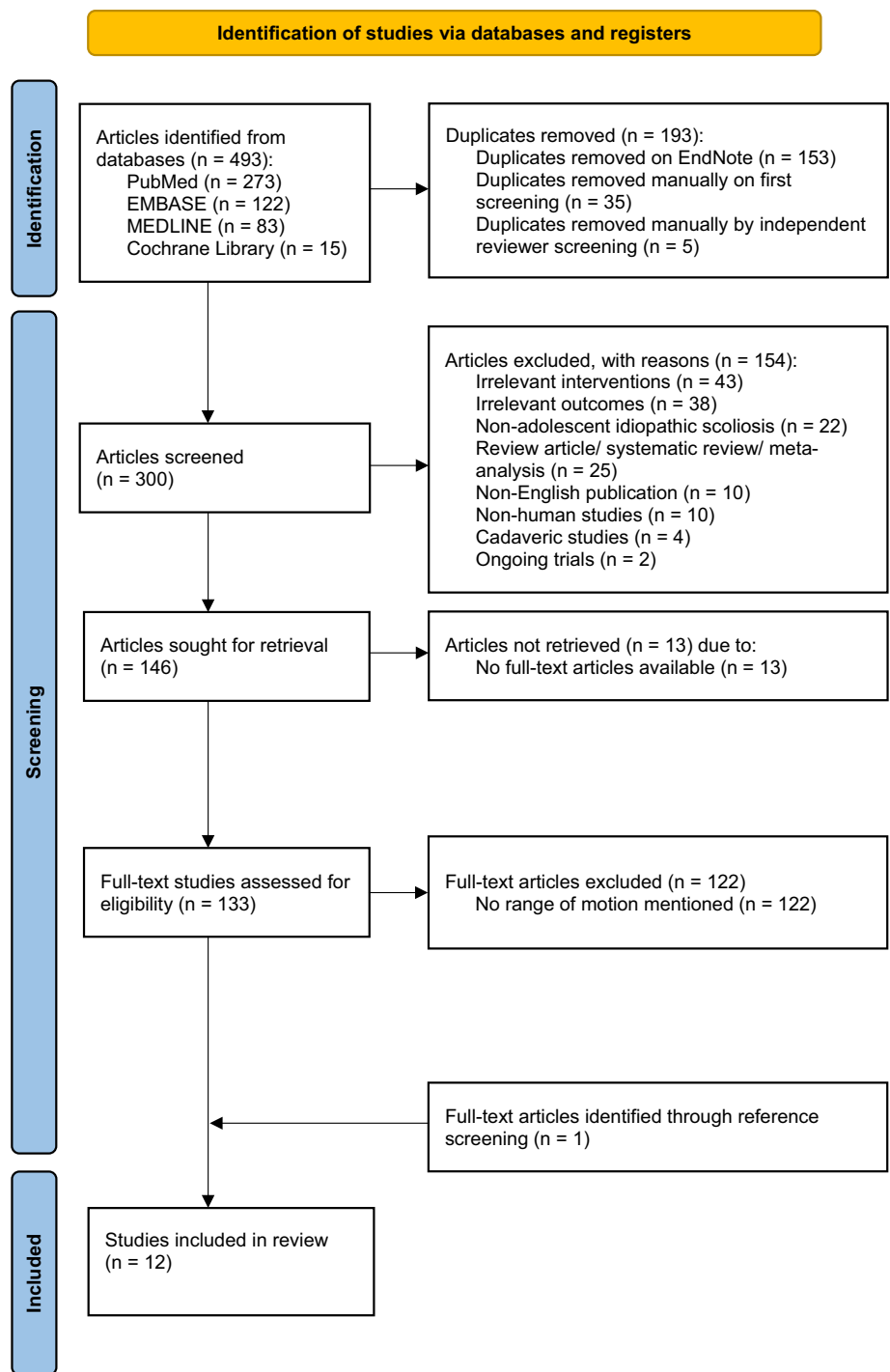
- (1) Cobb angles of the major curves (Supplementary Table 2), either preoperatively and postoperative or the curve correction as measured radiologically as Cobb angles following AVBT or PSF.
- (2) Quality of life (QOL) (Supplementary Table 3)—as reported by 36-item Short Form (SF-36), 22-item Scoliosis Research Society (SRS-22), and 24-item Scoliosis Research Society (SRS-24) questionnaires.
- (3) Complications (Supplementary Table 4), including over-correction, device/procedure-related adverse events, distal junctional kyphosis (DJK), sublaxation, pseudoarthrosis, degenerative complications, and radiologic imbalance. The complication over-correction is a specific complication for AVBT when “too small” of a deformity is treated in a patient with “too much” growth remaining [17].
- (4) Other relevant reported outcomes (Supplementary Table 5): flexor and extensor trunk endurance, motor strength of flexor and extensor muscles, and non-dynamometric trunk strength, which were assessed using functional tests or DAVID® device.

Other information regarding the study design, sample size, inclusion, and exclusion criteria of subjects, surgical technique, risk of bias, and overall quality of evidence was extracted and listed in Table 2.

Risk of bias

Two independent reviewers assessed the risk of bias for the included studies according to the Scottish Intercollegiate Network Guidelines (SIGN) [18, 19]. Any discrepancy was discussed with all authors until a consensus was reached. The risk of bias rating for each included study is listed in Table 2.

Fig. 1 PRISMA (preferred reporting items for systematic reviews and meta-analyses) flowchart illustrating selection process of studies



Grading of evidence

Two independent reviewers assessed the quality of evidence of the included studies according to the Grading of Recommendations Assessment, Development and Evaluation (GRADE) approach [20]. All included studies in this review were observational studies and were thus initially assigned as having a low level of evidence, according to GRADE

guidelines [20]. Downgrading of quality of evidence was done according to the five domains in the GRADE guidelines: risk of bias [21], imprecision [22], indirectness [23], inconsistency [22], and publication bias [24]. Meanwhile, the quality of evidence was upgraded based on large magnitude of effect, dose–response gradient, and plausible confounding that can increase confidence in estimated effects [25]. The overall quality of evidence is detailed in Table 3.

Table 1 Inclusion and exclusion criteria

Inclusion criteria	Exclusion criteria
<ul style="list-style-type: none"> • Patients with adolescent idiopathic scoliosis • Patients who underwent anterior vertebral body tethering or posterior spinal fusion or both as treatment • Studies with clearly defined outcomes for ROM 	<ul style="list-style-type: none"> • Studies including patients with idiopathic scoliosis of non-adolescent type, or non-idiopathic scoliosis caused by known pathologies such as trauma, congenital conditions, or infection • Biomechanical or cadaveric studies • Non-English publications • Case reports, conference summaries, unpublished literature, commentaries, and reviews

The quality of evidence for each outcome is listed in Supplementary Tables 1–5.

Results

Search results

The search results are detailed in the PRISMA flow diagram (Fig. 1). The search was conducted on August 22, 2022. A total of 493 articles were found with 300 articles remaining after removing the duplicates. The 300 unique articles were screened by their abstracts. Of these, 146 unique articles were assessed for eligibility by full-text screening. One unique article was added through reference screening during full-text screening. Ultimately, 12 unique articles were included in this review. Two were case–control studies, six were prospective cohort studies, and the remaining four were retrospective cohort studies. The length of follow-up ranged from 3 months to 22.4 years. Sample sizes of studies ranged from 5 to 225 patients.

Outcomes for range of motion

In accordance with the search strategy and inclusion criteria, all 12 studies included outcomes for ROM following surgical procedures of AVBT, PSF, or both (Supplementary Table 1). There is adequate evidence to suggest the superior mobility outcomes of AVBT, as coherently reported by all included papers in this systematic review. Two papers [31, 32] directly confirmed the superiority of mobility outcomes—as measured clinically and using VICON motion capture system, respectively—for AVBT as compared to PSF. Average lumbar ROM in flexion, extension, lateral bending, and rotation and average lumbar anterior and lateral bending flexibility were significantly superior ($p < 0.05$) in the AVBT group as compared to the PSF group [32]. While the AVBT group only demonstrated significant loss of flexion and side bending at 2 years postoperatively, the PSF group demonstrated a significant loss of motion in all four directions at 2 years postoperatively [31]. The post-op loss of motion was most clinically dramatic for total

trunk flexion after PSF compared with AVBT ($p < 0.05$), primarily due to the loss of lumbar flexion as more range of motion is lost with successively more caudal LIV [31]. For the $LIV \leq L1$ group, AVBT resulted in significantly more extension, side bending, and rotation ($\sim 10^\circ$ – 15° more) than PSF, but no difference in flexion [31]. Using side-bending radiographs, Buyuk et al. (2021) [26] and Wong et al. (2019) [17] reported preservation of curve flexibility and sagittal spinal motion in patients treated with AVBT. The remaining eight papers [27–30, 33–36] confirmed significant reduction in all ROM—cervical sagittal flexion, and extension and thoracic/lumbar sagittal flexion, extension, rotation, and side bending—following PSF. Of the eight studies [27–30, 33–36], four studies used VICON motion capture system [28, 30, 35, 36], three [27, 33, 34] used clinical measurement, and the remaining one study [29] used side-bending radiographs. These demonstrated the relative greater preservation of ROM in AVBT than in PSF.

Outcomes for Cobb angles

Of the 12 included studies, 10 reported findings for Cobb angles (Supplementary Table 2). The currently available studies, albeit the relatively low quality of evidence, all point to a similar clinical significance in Cobb angle correction achieved by AVBT or PSF. Only Pehlivanoglu et al. (2021) [32] directly compared AVBT and PSF. Pehlivanoglu et al. (2021) [32] found that both groups of patients had significant and similar correction of the major curve. The AVBT group had a preoperative average 48.2° corrected to 9.1° ($p < 0.001$) while the PSF group had a preoperative average 48.8° corrected to 9.7° ($p < 0.001$) at the last follow-up [32]. However, the quality of evidence is very low due to the retrospective cohort study design and the lack of confidence intervals reported. Both Buyuk et al. (2021) [26] and Wong et al. (2019) [17] also reported significant correction in Cobb angles for patients treated with AVBT, comparable to the correction in Cobb angles following PSF reported by Helenius et al. (2002) [27], Udoekwere et al. (2014) [35], Hosseini et al. (2016) [29], Holewijn et al. (2018) [28], Wong et al. (2018) [36], Kakar et al. (2019) [30], and Segal et al. (2019) [33]. Nonetheless, the quality of evidence in

Table 2 Summary of study characteristics

Study	Year	Study design	Sample size	Inclusion criteria	Exclusion criteria	Surgical technique	Follow-up duration	Outcomes extracted	Risk of bias	Overall quality of evidence
Buyuk et al. [26]	2021	PCS	32	Age of 10 to 16 years, Major Cobb angle of 40° to 70°, Sanders stage ≤ 4, Risser stage ≤ 2, Appropriate Lenke curve pattern (Lenke 1A, 1B, 1C, 2A, 2B, 2C, and 3C), Minimum of 1 year of follow-up	Lenke 5 curves, non-flexible curves (> 40° on preoperative bending radiographs), pregnancy, prior surgery, active infection, metal allergy, current substance abuse, inability to commit to follow-up or congenital, neuromuscular, or syndromic scoliosis	AVBT	1 year	Preoperative & postoperative curve parameters, Cobb angles, preoperative & postoperative range of motion	High quality	Low
Helenius et al. [27]	2002	RCS	78	AIS patients who underwent surgery with Harrington instrumentation and posterior spondylodesis performed by two senior orthopedic surgeons at Orton Orthopedic Hospital, Helsinki, Finland, from January to November 1979	Not mentioned	PSF	Average 20.8 years	Preoperative & postoperative curve parameters, Cobb angles, SRS-22, preoperative & postoperative range of motion	Acceptable	Very low
Holewijn et al. [28]	2018	PCS	12	Female patients with AIS between 12 and 18 years old	Disorders that could alter gait pattern (i.e., neurological or musculoskeletal disorders), history of spinal surgery, cognitive disorders	PSF	1 year	Preoperative & postoperative curve parameters, preoperative & postoperative range of motion	Acceptable	Very low

Table 2 (continued)

Study	Year	Study design	Sample size	Inclusion criteria	Exclusion criteria	Surgical technique	Follow-up duration	Outcomes extracted	Risk of bias	Overall quality of evidence
Hosseini et al. [29]	2016	PCS	21	AIS Lenke 1A or 1B curves between 40° and 65° with ≥ 40% correction on supine, side-bending X-rays using Cobb measurements, Sanders stage 3 to 7, body mass index ≤ 30 kg/m ² , parent(s)/legal guardian(s) willing to participate, comply with study requirements	History of metabolic bone disease, thoracic hyperkyphosis > 50°, prior spine surgery, active infection, other medical contraindication to surgery, psychiatric or cognitive impairment, known allergy to titanium or cobalt–chromium alloys, participating in another drug or device study, pregnancy, judged by the surgeon to be too small in size for safe pedicle screw placement	PSF	1 year	Preoperative & postoperative curve parameters, Cobb angles, preoperative & postoperative range of motion	Acceptable	Very low
Kakar et al. [30]	2019	Case–control	20	Individuals with thoracolumbar AIS, who underwent spinal fusion, returned to unrestricted participation in physical activity and sports	Anatomic misalignment other than AIS, lower extremity fractures	PSF	2 ± 0.6 years	Preoperative & postoperative curve parameters, preoperative & postoperative range of motion	Acceptable	Very low

Table 2 (continued)

Study	Year	Study design	Sample size	Inclusion criteria	Exclusion criteria	Surgical technique	Follow-up duration	Outcomes extracted	Risk of bias	Overall quality of evidence
Pahys et al. [31]	2022	RCS	112	AIS patients and families were offered a choice between AVBT and PSF if the patient met all three criteria below, only PSF was offered otherwise For AVBT: Curve magnitude of 45° to 65°, Curve flexibility (Reduction to < 30° on supine bending radiographs), skeletal immaturity (Risser grade 0 to 1, Sanders Digital Score (SDS) of 3 to 4)	Not mentioned	AVBT & PSF	2 years	Preoperative & postoperative curve parameters, SRS-22, preoperative & postoperative range of motion	Acceptable	Moderate
Pehlivanoglu et al. [32]	2021	RCS	43	Minimum 3 years of follow-up, age of 9 to 14, primary thoracic curves only, curve magnitudes of 40°–60°, no prior spine surgery, Risser ≤ 2, Sanders < 4, history of failed bracing	Curve > 60° Congenital scoliosis Skeletally mature	AVBT & PSF	3 to 4 years	Preoperative & postoperative curve parameters, SRS score, SF-36 score, preoperative & postoperative range of motion	Acceptable	Very low

Table 2 (continued)

Study	Year	Study design	Sample size	Inclusion criteria	Exclusion criteria	Surgical technique	Follow-up duration	Outcomes extracted	Risk of bias	Overall quality of evidence
Segal et al. [33]	2019	RCS	225	AIS patients who had Lenke 1 or 2 curves, patients who were treated with a spinal fusion that had a lower instrumental vertebra of T11, T12, or L1 were included	> 18 years old, having inadequate imaging, underwent revision surgery, or having incomplete 2-year and 5-year follow-up data	PSF	5 years	Preoperative & postoperative curve parameters, Cobb angles, preoperative & 5-year postoperative SRS-22, preoperative & postoperative range of motion	Acceptable	Low
Turan et al. [34]	2022	Case-control	50	Minimum follow-up of 3 years, underwent thoracolumbar posterior instrumentation and fusion for the correction of thoracic and lumbar deformity, Having spinal range of motion and strength measurements	Incomplete medical records, underwent only thoracic or lumbar vertebrae fusion	PSF	Minimum 3 years	Preoperative & postoperative curve parameter, SRS-22 score, preoperative & postoperative range of motion	Acceptable	Very low
Udoekwere et al. [35]	2014	PCS	47	AIS patients who had posterior spinal fusion between October 2007 and August 2012, Cobb angle > 50°	Patients with neuromuscular pathology, being unable to walk or stand independently, pregnancy, requiring a fusion outside the level of T12, L1-4	PSF	2 years	Preoperative & postoperative curve parameters, Cobb angles, motion of trunk segment relative to the pelvis, trunk kinematic peaks, overall trunk range of motion in three planes	Acceptable	Low

Table 2 (continued)

Study	Year	Study design	Sample size	Inclusion criteria	Exclusion criteria	Surgical technique	Follow-up duration	Outcomes extracted	Risk of bias	Overall quality of evidence
Wong et al. [36]	2018	PCS	24	AIS with a thoracic right-sided curve, female, age of 12 to 18 years old	History of spinal surgery, mental retardation, or other musculoskeletal/neurological diseases known to affect sensorimotor performance	PSF	1 year	Gait assessment, mean angle and range of motion of lower body kinematic angles and the hip in the frontal plane during the gait cycle, trunk range of motion, Cobb angles	Acceptable	Very low
Wong et al. [17]	2019	PCS	5	Diagnosis of AIS, age at enrollment ≥ 8 and < 15 years old, Risser stage 0, bone age ≤ 13 as measured by hand/wrist radiographs, major right thoracic scoliosis with a Cobb angle of 35° to 55° and Lenke I curves, thoracic kyphosis $< 40^\circ$, Instrumentation to be no more cephalad than T4 and no more caudal than L2 inclusive, Menses < 4 months	Vertebrae < 13 mm in height, non-ambulatory, osteoporosis by clinical diagnosis, prior ipsilateral thoracic surgery, associated syndromes of intraspinal pathology requiring neurosurgical intervention, prior surgical spinal treatment in the region of planned instrumentation, no tolerance to one-lung anesthesia, Infection in the disc or spine, past or present, evidence of active infection at the time of surgery, known allergy to polyethylene or titanium alloy	AVBT	Minimum 4 years	Preoperative & postoperative curve parameters, Cobb angles, SRS-22, Adverse events of the treatment, Preoperative & Postoperative range of motion	Acceptable	Very low

AIS, adolescent idiopathic scoliosis; AVBT, anterior vertebral body tethering; PCS, prospective cohort study; PSF, posterior spinal fusion; RCS, retrospective cohort study; SF-36, Short Form 36; SRS-22, Scoliosis Research Society 22-item

Table 3 Risk of bias assessment and grading of evidence for included studies in this systematic review

Study	Risk of bias	Inconsistency	Indirectness	Imprecision	Publication bias	Large magnitude of effect exists	Dose–response gradient	Plausible confounding can increase confidence in estimated effects	Overall quality of evidence
Buyuk et al. [26]	High quality	Not serious	Not serious	Serious	Undetected	Yes (Up 1)	N/A	N/A	Low
Helenius et al. [27]	Acceptable	Not serious	Not serious	Serious	Undetected	N/A	N/A	N/A	Very low
Holewijn et al. [28]	Acceptable	Not serious	Not serious	Serious	Undetected	N/A	N/A	N/A	Very low
Hosseini et al. [29]	Acceptable	Not serious	Not serious	Serious	Undetected	N/A	N/A	N/A	Very low
Kakar et al. [30]	Acceptable	Not serious	Not serious	Serious	Undetected	N/A	N/A	N/A	Very low
Pahys et al. [31]	Acceptable	Not serious	Not serious	Not serious	Undetected	N/A	N/A	Yes (Up 1)	Moderate
Pehlivanoglu et al. [32]	Acceptable	Not serious	Not serious	Serious	Undetected	N/A	N/A	N/A	Very low
Segal et al. [33]	Acceptable	Not serious	Not serious	Not serious	Undetected	N/A	N/A	N/A	Low
Turan et al. [34]	Acceptable	Not serious	Not serious	Serious	Undetected	N/A	N/A	N/A	Very low
Udoekwere et al. [35]	Acceptable	Not serious	Not serious	Not serious	Undetected	N/A	N/A	N/A	Low
Wong et al. [36]	Acceptable	Not serious	Not serious	Serious	Undetected	N/A	N/A	N/A	Very low
Wong et al. [17]	Acceptable	Not serious	Not serious	Serious	Undetected	N/A	N/A	N/A	Very low

N/A, not applicable

this review is insufficient to conclude similar Cobb angle correction for AVBT and PSF.

Outcomes for quality of life

Five studies reported outcomes for QOL following AVBT and PSF (Supplementary Table 3). Overall, respective QOL outcomes for AVBT and PSF were heterogeneous. Pehlivanoglu et al. (2021) [32] and Pahys et al. (2022) [31] directly compared and found different results for QOL outcomes. While Pahys et al. (2022)[31] reported no significant difference between PSF and AVBT groups postoperatively in SRS-22 domain subscores, Pehlivanoglu et al. (2021) [32] found significantly superior average total SRS scores (4.9 vs 3.8, $p < 0.001$) and average SF-36 scores (56.9 vs. 52.3, $p < 0.001$ for mental component summary, 57.2 vs. 53.1, $p < 0.001$ for physical component summary) in the AVBT group when compared to the PSF group. Meanwhile, Wong et al. (2019) [17] showed a reduced mean SRS-22 satisfaction domain score after AVBT. The two studies [27, 34] reporting QOL outcomes for PSF did not compare the

SRS-22 score preoperatively and postoperatively. Nonetheless, Helenius et al. (2002) [27] found no correlation between SRS total score and curve magnitude or correction in PSF patients at 20-year follow-up. The quality of evidence in this review is insufficient to make concrete comparison between the two surgical approaches in QOL measures.

Complications

Only one study reported complications following AVBT and three studies reported complications following PSF in our review (Supplementary Table 4). In Wong et al. (2019) [17] single-center prospective observational study of five subjects, two patients had over-correction following AVBT and another patient—the only case with Lenke “B” lumbar curve modifier preoperatively had curve progression reaching 58° at 54 months with unclear reason but postulated to be due to lumbar curve progression following modest correction by AVBT. Subsequently, one of the patients with over-correction required tether removal followed by PSF due to distal decompensation that manifested as deterioration of

overall Cobb angle which was postulated to be caused by a combination of large growth potential, main curve over-correction, and distal junctional kyphosis; the patient with modest correction underwent PSF without tether removal as there was no acute angulation to suggest tether breakage [17]. In contrast, Helenius et al. (2002) [27] reported five lateral subluxation of the lumbar vertebrae (6%), one pseudoarthrosis (1%), 19 narrowed lumbar disc spaces (24%), 17 degenerative lumbar spondylosis (22%), nine radiologic spinal imbalance (12%), and eight dislodged caudad hooks on the 20-year follow-up radiographs (13%) following PSF among 98 patients. However, two other studies [29, 33] reported generally low procedural/device-related adverse events, including asymptomatic mal-positioned screw requiring revision and distal junctional kyphosis, following PSF. In addition to the complications noted conventionally in PSF, over-correction and distal adding-on are major concerns of AVBT which may warrant possible conversion surgery to PSF.

Other reported outcomes

Using functional tests, three papers investigated the muscle strength and endurance in patients treated with AVBT and/or PSF (Supplementary Table 5). Besides outcomes for ROM following AVBT and PSF, Pehlivanoglu et al. (2021) [32] also reported significantly higher average lumbar flexor and extensor endurance in patients treated with AVBT as compared to PSF (Flexor: VBT 65.1 s, PSF 19.2 s; $p < 0.001$) (Extensor: VBT 60.8 s, PSF 28.7 s; $p < 0.001$). The AVBT group also had a significantly superior average motor strength of the trunk extensor and anterior–lateral–oblique flexor muscles (VBT 4.7, PSF 3.2; $p = 0.003$) [32]. In contrast, Turan et al. (2022) [34] found that patients treated with PSF had significantly reduced muscle strength in the cervical and thoracic/lumbar regions (all with $p < 0.05$) compared to the control group, except for the thoracic/lumbar left rotation strength ($p = 0.081$), as assessed using DAVID® device. In addition, Helenius et al. (2002) [27] reported that mean values of the non-dynamometric trunk strength measurements were at least 3 (range 1–5) following PSF. The superior muscle strength of AVBT may suggest better functional outcomes.

Discussion

PSF has been the gold standard surgical treatment of AIS, but it results in loss of ROM [9]. When AVBT was introduced and eventually approved by the USFDA in 2019, it was heralded as the fusionless alternative to PSF and the potentially new gold standard which could correct scoliosis while preserving ROM in AIS [37]. However, there have

been no reviews, confirming that AVBT is indeed superior to PSF in providing better ROM outcomes. Therefore, this review is the first to investigate ROM outcomes of AVBT compared to PSF.

As all the included studies are either case–control studies, cohort studies, or case series, this review only found moderate evidence to support the superior ROM outcomes for AVBT compared to PSF in treating AIS due to the lack of randomized controlled trials. The strongest evidence in supporting the superior ROM outcomes in AIS patients treated with AVBT when compared to PSF comes from Pahys et al. (2022) [31]. As a retrospective cohort study, the initial quality of evidence for ROM provided by Pahys et al. (2022) [31] was low. However, their quality of evidence for ROM was upgraded to moderate when they demonstrated—regardless of LIV level—superior preservation of total trunk flexion and minimal changes in total trunk extension and rotation in AVBT compared to PSF despite AVBT being indicated for patients with reduced curve flexibility (reduction to $< 30^\circ$ on supine bending radiographs) [31]. Nonetheless, Pahys et al. (2022) [31] concluded that the differences in total trunk motion were relatively modest for PSF and AVBT with an LIV at or above L1.

Although the studies in this review use different modalities for measurement of ROM, clinical measurement [32], VICON motion capture system [31], and side-bending radiographs [17, 26], all showed favorable results for AVBT in preservation of spinal motion and flexibility. Meanwhile, all modalities collectively showed decrease in motion of fused segments and trunk in three planes: sagittal, coronal, and transverse. Therefore, although studies other than Pahys et al. (2022) [31] have lower quality of evidence, the superior ROM outcomes proven by all modalities across different studies strongly suggest that AVBT indeed results in better mobility for AIS patients.

Superior ROM outcomes would be futile if curve correction is inadequate. Therefore, this review has also extracted outcomes for Cobb angle correction. We found overall low evidence to support that both AVBT and PSF could achieve significant Cobb angle correction, respectively. This finding is supported by Newton et al. (2020) [38] that demonstrated both AVBT and PSF resulted in significant postoperative correction. However, several individual studies found reduced Cobb angle correction by AVBT compared to PSF at all postoperative time points [32, 38, 39]. This is contradictory to the meta-analysis by Shin et al. (2021) [40] reporting similar deformity correction between the AVBT and PSF groups.

Apart from ROM, it is also equally important to assess whether AVBT improves QOL. Our review revealed controversial findings—with overall very low evidence due to the cohort study design and lack of confidence intervals—that AVBT resulted in significantly superior average

total SRS-22 and SF-36 scores compared to PSF. Meanwhile, Newton et al. (2020) [38] and Qiu et al. (2021) [41] found equivalent patient-reported outcomes between the AVBT and PSF groups, as measured by SRS-22, across all domains: pain, self-image, function, mental health, and satisfaction. A recent meta-analysis also found no significant difference between AVBT and PSF for postoperative SRS-22 self-image (4.27 in AVBT versus 4.23 in PSF) or total score (4.36 in AVBT versus 4.3 in PSF) [40]. Therefore, our review cannot conclude the superior QOL improvement in AIS patients treated with AVBT compared to PSF.

Regarding the complications of AVBT, our evidence and findings came from only one study because there are limited studies on the long-term outcomes for AVBT as it has only been approved by the USFDA in 2019. In a single-center prospective observational study of this investigational device of AVBT, Wong et al. (2019) [17] reported two patients (40%) with over-correction and two patients requiring PSF as revision surgery. While one patient with open triradiate cartilage (TRC) was able to maintain coronal balance at 4 years despite over-correction, the other patient required tether removal followed by PSF due to distal decompensation manifesting as deterioration of the overall Cobb angle [17]. Another patient underwent PSF without tether removal after developing curve progression due to modest correction following AVBT [17]. Based on our review alone, we are unable to comment on the complication rate of AVBT due to the very low quality of evidence by Wong et al. (2019) [17] as the study has a small sample size of 5. Nonetheless, Wong et al. (2019) [17] was included because it is the only study we found that investigated the long-term outcome of AVBT with a follow-up duration of at least 4 years. A meta-analysis by Shin et al. (2021) [40] also found higher rate of re-operation in the AVBT group (14.1%) compared to the PSF group (0.6%). The most common reason for re-operation in AVBT was over-correction, accounting for 54.8% of the re-operation cases [40]. Over-correction is generally thought to be caused by the excessive growth potential, which is also needed for progressive curve correction in AVBT [17, 40]. Currently, there is no consensus on the determination of the ideal time for surgery to achieve maximal curve correction and minimal over-correction. This is because the expected growth curve in the spine is still not well understood [38]. Additionally, tether breakage and adding-on were the second most common reasons for re-operation, each accounting for 22.6% of re-operation cases in the AVBT group [40]. Nonetheless, Newton et al. (2020) [38] found that although AVBT resulted in less deformity correction and more revision procedures than PSF, AVBT still resulted in delay or prevention of PSF in majority of the patients. Additionally, in our review, we found very low to low evidence that PSF also resulted in substantial number of complications, including degenerative changes, radiologic instability, and adverse

device/procedure-related events. Moreover, many of the PSF studies did not report complications. Therefore, our review cannot conclusively determine the complication rates of AVBT and PSF.

This systematic review has limitations. Firstly, this review only examined the generalized ROM outcomes instead of any specific direction of ROM. Secondly, it was difficult to make fair comparisons between the included studies as there are no standardized measurement methods for ROM. However, despite different modalities of measurement for ROM, all confirmed superior ROM outcomes in AIS patients treated with AVBT compared to PSF. Thirdly, the variability in the operated segments, including the LIV and upper instrumented vertebra (UIV), made fair comparisons between studies rather challenging. Fourthly, the long-term complication of add-on or decompensation in the PSF group may be more and not reported in studies directly comparing AVBT vs PSF due to the limited duration of follow-up.

In conclusion, this is the first systematic review investigating the ROM outcomes for AVBT compared with PSF in treating AIS. We found adequate evidence to demonstrate that AVBT provides better preservation of ROM and muscle strength postoperatively when compared with PSF, while achieving comparable curve correction. Nonetheless, over-correction remains one of the biggest challenges in treating AIS patients with AVBT. Future studies can focus on exploring the growth trajectory of the spine to determine the window of opportunity to perform AVBT in AIS to achieve maximal curve correction with minimal risk of over-correction. For fair comparisons, clinical studies should also consider LIV and UIV when comparing the mobility, curve correction, complications, functional outcomes, and long-term outcomes for AVBT and PSF. Patients opting for AVBT may have a higher demand for athletic activities; thus, return to sport activities and high athletic functional performance should also be assessed in future studies.

Prospero

This systematic review has been registered in PROSPERO (CRD42022371586) on November 10, 2022.

Authors' contribution Darren Li Liang Wong, Jason Pui Yin Cheung, and Michael To were involved in conceptualization; Darren Li Liang Wong, Pak Tung Mong, Chun Yin Ng, Chun Kwan Ong, Zhekai Qian, Mang Hong Shao, Ling Kwan Ernest Sin, Bao Yi Wong, Chun Ming Wong, and Jason Pui Yin Cheung helped in methodology; Darren Li Liang Wong, Pak Tung Mong, Chun Yin Ng, Chun Kwan Ong, Zhekai Qian, Mang Hong Shao, Ling Kwan Ernest Sin, Bao Yi Wong, and Chun Ming Wong contributed to formal analysis and investigation; Darren Li Liang Wong, Pak Tung Mong, Chun Yin Ng, and Chun Kwan Ong were involved in writing—original draft preparation; Jason Pui Yin Cheung helped in writing—review and editing. Jason Pui

Yin Cheung and Michael To contributed to resources; Jason Pui Yin Cheung and Michael To helped in supervision.

Funding No funding was received for conducting this study.

Availability of data and material Not applicable.

Code availability Not applicable.

Declarations

Conflict of interest The authors have not disclosed any competing interests.

Ethics approval Not applicable.

Consent to participate Not applicable.

Consent for publication Not applicable.

Open Access This article is licensed under a Creative Commons Attribution 4.0 International License, which permits use, sharing, adaptation, distribution and reproduction in any medium or format, as long as you give appropriate credit to the original author(s) and the source, provide a link to the Creative Commons licence, and indicate if changes were made. The images or other third party material in this article are included in the article's Creative Commons licence, unless indicated otherwise in a credit line to the material. If material is not included in the article's Creative Commons licence and your intended use is not permitted by statutory regulation or exceeds the permitted use, you will need to obtain permission directly from the copyright holder. To view a copy of this licence, visit <http://creativecommons.org/licenses/by/4.0/>.

References

- Konieczny MR, Hs S, Krauspe Rd (2012) Epidemiology of adolescent idiopathic scoliosis. *J Child Orthop* 7:3–9. <https://doi.org/10.1007/s11832-012-0457-4>
- Weinstein SLD, Dolan LAP, Cheng JCYMD, Danielsson AMD, Morcuende JAMD (2008) Adolescent idiopathic scoliosis. *Lancet* 371:1527–1537. [https://doi.org/10.1016/S0140-6736\(08\)60658-3](https://doi.org/10.1016/S0140-6736(08)60658-3)
- Post M, Verdun S, Roussouly P, Abelin-Genevois K (2019) New sagittal classification of AIS: validation by 3D characterization. *Eur Spine J* 28:551–558. <https://doi.org/10.1007/s00586-018-5819-2>
- Pasha S, Baldwin K (2018) Are we simplifying balance evaluation in adolescent idiopathic scoliosis? *Clin Biomech (Bristol, Avon)* 51:91–98. <https://doi.org/10.1016/j.clinbiomech.2017.11.011>
- Kotwicki T (2008) Evaluation of scoliosis today: examination, X-rays and beyond. *Disabil Rehabil* 30:742–751. <https://doi.org/10.1080/09638280801889519>
- Addai D, Zarkos J, Bowey AJ (2020) Current concepts in the diagnosis and management of adolescent idiopathic scoliosis. *Childs Nerv Syst* 36:1111–1119. <https://doi.org/10.1007/s00381-020-04608-4>
- Weinstein SL, Dolan LA, Wright JG, Dobbs MB (2013) Effects of Bracing in Adolescents with Idiopathic Scoliosis. *N Engl J Med* 369:1512–1521. <https://doi.org/10.1056/NEJMoa1307337>
- Wong LPK, Cheung PWH, Cheung JPY (2022) Curve type, flexibility, correction, and rotation are predictors of curve progression in patients with adolescent idiopathic scoliosis undergoing conservative treatment : a systematic review. *Bone Joint J* 104–B:424–432. <https://doi.org/10.1302/0301-620X.104B4.BJJ-2021-1677.R1>
- Asher MA, Burton DC (2006) Adolescent idiopathic scoliosis: natural history and long term treatment effects. *Scoliosis* 1:2–2. <https://doi.org/10.1186/1748-7161-1-2>
- Burton DC, Sama AA, Asher MA, Burke SW, Boachie-Adjei O, Huang RC, Green DW, Rawlins BA (2005) The treatment of large (>70 degrees) thoracic idiopathic scoliosis curves with posterior instrumentation and arthrodesis: when is anterior release indicated? *Spine* 30:1979–1984. <https://doi.org/10.1097/01.brs.0000176196.94565.d6>
- Green DW, Lawhorne TW, Widmann RF, Kepler CK, Ahern C, Mintz DN, Rawlins BA, Burke SW, Boachie-Adjei O (2011) Long-term magnetic resonance imaging follow-up demonstrates minimal transitional level lumbar disc degeneration after posterior spine fusion for adolescent idiopathic scoliosis. *Spine* 36:1948–1954. <https://doi.org/10.1097/BRS.0b013e3181ff1ea9>
- Kepler CK, Meredith DS, Green DW, Widmann RF (2012) Long-term outcomes after posterior spine fusion for adolescent idiopathic scoliosis. *Curr Opin Pediatr* 24:68–75. <https://doi.org/10.1097/MOP.0b013e32834ec982>
- Danielsson AJ, Romberg K, Nachemson AL (2006) Spinal range of motion, muscle endurance, and back pain and function at least 20 years after fusion or brace treatment for adolescent idiopathic scoliosis : A case-control study. *Spine* 31:275–283. <https://doi.org/10.1097/01.brs.0000197652.52890.71>
- FDA (2022) Pediatric Advisory Committee. FDA Executive Summary H190005 The TetherTM—Vertebral Body Tethering System. <https://www.fda.gov/media/157897/download>. Accessed 10 June 2022
- Newton PO (2020) Spinal growth tethering: indications and limits. *Ann Transl Med* 8:27. <https://doi.org/10.21037/atm.2019.12.159>
- Moher D, Liberati A, Tetzlaff J, Altman DG, The PG (2009) Preferred reporting items for systematic reviews and meta-analyses: The PRISMA statement. *PLOS Med* 6:e1000097. <https://doi.org/10.1371/journal.pmed.1000097>
- Wong H-K, Ruiz JNM, Newton PO, Gabriel Liu K-P (2019) Non-fusion surgical correction of thoracic idiopathic scoliosis using a novel, braided vertebral body tethering device: minimum follow-up of 4 years. *JB JS Open Access* 4:e0026–e0026. <https://doi.org/10.2106/JBJS.OA.19.00026>
- SIGN (2012) Scottish Intercollegiate Network Guidelines. Case Control Studies. Edinburgh: SIGN. <http://www.sign.ac.uk>. Accessed 10 August 2022
- SIGN (2012) Scottish Intercollegiate Network Guidelines. Cohort studies. Edinburgh: SIGN. <http://www.sign.ac.uk>. Accessed 10 August 2022
- Guyatt G, Oxman AD, Akl EA, Kunz R, Vist G, Brozek J, Norris S, Falck-Ytter Y, Glasziou P, deBeer H, Jaeschke R, Rind D, Meerpohl J, Dahm P, Schünemann HJ (2011) GRADE guidelines: 1. Introduction—GRADE evidence profiles and summary of findings tables. *J Clin Epidemiol* 64:383–394. <https://doi.org/10.1016/j.jclinepi.2010.04.026>
- Balshem H, Helfand M, Schünemann HJ, Oxman AD, Kunz R, Brozek J, Vist GE, Falck-Ytter Y, Meerpohl J, Norris S, Guyatt GH (2011) GRADE guidelines: 3. Rating the quality of evidence. *J Clin Epidemiol* 64:401–406. <https://doi.org/10.1016/j.jclinepi.2010.07.015>
- Zhang Y, Coello PA, Guyatt GH, Yepes-Nuñez JJ, Akl EA, Hazlewood G, Pardo-Hernandez H, Etxeandia-Ikobaltzeta I, Qaseem A, Williams JW, Tugwell P, Flottorp S, Chang Y, Zhang Y, Mustafa RA, Rojas MX, Xie F, Schünemann HJ (2019) GRADE guidelines: 20. Assessing the certainty of evidence in the importance of outcomes or values and preferences—inconsistency, imprecision, and other domains. *J Clin Epidemiol* 111:83–93. <https://doi.org/10.1016/j.jclinepi.2018.05.011>

23. Zhang Y, Alonso-Coello P, Guyatt GH, Yepes-Nuñez JJ, Akl EA, Hazlewood G, Pardo-Hernandez H, Etxeandia-Ikobaltzeta I, Qaseem A, Williams JW, Tugwell P, Flottorp S, Chang Y, Zhang Y, Mustafa RA, Rojas MX, Schünemann HJ (2019) GRADE Guidelines: 19. Assessing the certainty of evidence in the importance of outcomes or values and preferences—risk of bias and indirectness. *J Clin Epidemiol* 111:94–104. <https://doi.org/10.1016/j.jclinepi.2018.01.013>
24. Guyatt GH, Oxman AD, Montori V, Vist G, Kunz R, Brozek J, Alonso-Coello P, Djulbegovic B, Atkins D, Falck-Ytter Y, Williams JW, Meerpohl J, Norris SL, Akl EA, Schünemann HJ (2011) GRADE guidelines: 5. Rating the quality of evidence—publication bias. *J Clin Epidemiol* 64:1277–1282. <https://doi.org/10.1016/j.jclinepi.2011.01.011>
25. Guyatt GH, Oxman AD, Sultan S, Glasziou P, Akl EA, Alonso-Coello P, Atkins D, Kunz R, Brozek J, Montori V, Jaeschke R, Rind D, Dahm P, Meerpohl J, Vist G, Berliner E, Norris S, Falck-Ytter Y, Murad MH, Schünemann HJ (2011) GRADE guidelines: 9. Rating up the quality of evidence. *J Clin Epidemiol* 64:1311–1316. <https://doi.org/10.1016/j.jclinepi.2011.06.004>
26. Buyuk AF, Milbrandt TA, Mathew SE, Larson AN (2021) Measurable thoracic motion remains at 1 year following anterior vertebral body tethering, with sagittal motion greater than coronal motion. *J Bone Joint Surg Am* 103:2299–2305. <https://doi.org/10.2106/jbjs.20.01533>
27. Helenius I, Remes V, Yrjönen T, Ylikoski M, Schlenzka D, Helenius M, Poussa M (2002) Comparison of long-term functional and radiologic outcomes after Harrington instrumentation and spondylodesis in adolescent idiopathic scoliosis: a review of 78 patients. *Spine* 27:176–180. <https://doi.org/10.1097/00007632-200201150-00010>
28. Holewijn RM, Kingma I, De Kleuver M, Keijsers NLW (2018) Posterior spinal surgery for adolescent idiopathic scoliosis does not induce compensatory increases in adjacent segment motion: a prospective gait analysis study. *Global Spine J* 8:43S–44S. <https://doi.org/10.1177/2192568218771030>
29. Hosseini P, Nnadi C, Reháč L, Repko M, Grevitt M, Aydinli U, Carl A, Pawelek J, Crandall D, Akbarnia BA (2016) Analysis of segmental mobility following a novel posterior apical short-segment correction for adolescent idiopathic scoliosis. *Spine* 41:E1223–e1229. <https://doi.org/10.1097/brs.0000000000001607>
30. Kakar RS, Li Y, Brown CN, Oswald TS, Simpson KJ (2019) Spine and lower extremity kinematics exhibited during running by adolescent idiopathic scoliosis patients with spinal fusion. *Spine Deform* 7:254–261. <https://doi.org/10.1016/j.jspd.2018.08.015>
31. Pahys JM, Samdani AF, Hwang SW, Warshauer S, Gaughan JP, Chafetz RS (2022) Trunk range of motion and patient outcomes after anterior vertebral body tethering versus posterior spinal fusion: comparison using computerized 3D motion capture technology. *J Bone Joint Surg Am*. <https://doi.org/10.2106/JBJS.21.00992>
32. Pehlivanoglu T, Oltulu I, Erdag Y, Akturk UD, Korkmaz E, Yildirim E, Sarioglu E, Ofluoglu E, Aydogan M (2021) Comparison of clinical and functional outcomes of vertebral body tethering to posterior spinal fusion in patients with adolescent idiopathic scoliosis and evaluation of quality of life: preliminary results. *Spine Deform* 9:1175–1182. <https://doi.org/10.1007/s43390-021-00323-5>
33. Segal DN, Grabel ZJ, Konopka JA, Boissonneault AR, Yoon E, Bastrom TP, Flynn JM, Fletcher ND (2019) Fusions ending at the thoracolumbar junction in adolescent idiopathic scoliosis: comparison of lower instrumented vertebrae. *Spine Deform*. <https://doi.org/10.1016/j.jspd.2019.05.006>
34. Turan K, Kara GK, Camurcu Y, Kizilay YO, Uysal Y, Sahin E, Aydinli U (2022) Cervical and thoracic/lumbar motion and muscle strength in surgically treated adolescent idiopathic scoliosis patients. *J Back Musculoskelet Rehabil*. <https://doi.org/10.3233/bmr-210303>
35. Udoekwere UI, Krzak JJ, Graf A, Hassani S, Tarima S, Riordan M, Sturm PF, Hammerberg KW, Gupta P, Anissipour AK, Harris GF (2014) Effect of lowest instrumented vertebra on trunk mobility in patients with adolescent idiopathic scoliosis undergoing a posterior spinal fusion. *Spine Deform* 2:291–300. <https://doi.org/10.1016/j.jspd.2014.04.006>
36. Wong-Chung D, Schimmel JJP, de Kleuver M, Keijsers NLW (2018) Asymmetrical trunk movement during walking improved to normal range at 3 months after corrective posterior spinal fusion in adolescent idiopathic scoliosis. *Eur Spine J* 27:388–396. <https://doi.org/10.1007/s00586-017-5369-z>
37. Alkhalife YI, Padhye KP, El-Hawary R (2019) New technologies in pediatric spine surgery. *Orthop Clin North Am* 50:57–76. <https://doi.org/10.1016/j.oocl.2018.08.014>
38. Newton PO, Bartley CE, Bastrom TP, Kluck DG, Saito W, Yaszay B (2020) Anterior spinal growth modulation in skeletally immature patients with idiopathic scoliosis: a comparison with posterior spinal fusion at 2 to 5 years postoperatively. *J Bone Joint Surg Am* 102:769–777. <https://doi.org/10.2106/JBJS.19.01176>
39. Mathew SE, Hargiss JB, Milbrandt TA, Stans AA, Shaughnessy WJ, Larson AN (2022) Vertebral body tethering compared to posterior spinal fusion for skeletally immature adolescent idiopathic scoliosis patients: preliminary results from a matched case–control study. *Spine deformity* 10:1123–1131. <https://doi.org/10.1007/s43390-022-00519-3>
40. Shin M, Arguelles GR, Cahill PJ, Flynn JM, Baldwin KD, Anari JB (2021) Complications, reoperations, and mid-term outcomes following anterior vertebral body tethering versus posterior spinal fusion: a meta-analysis. *JB & JS Open Access*. <https://doi.org/10.2106/JBJS.OA.21.00002>
41. Qiu C, Talwar D, Gordon J, Capraro A, Lott C, Cahill PJ (2021) Patient-reported outcomes are equivalent in patients who receive vertebral body tethering versus posterior spinal fusion in adolescent idiopathic scoliosis. *Orthopedics* 44:24–28. <https://doi.org/10.3928/01477447-20201119-02>

Publisher's Note Springer Nature remains neutral with regard to jurisdictional claims in published maps and institutional affiliations.