

COVID toe in an adolescent boy: a case report

Joshua SC Wong^{1†}, MB, BS, FHKAM (Paediatrics), TS Wong^{1†}, MB, ChB, MRCPCH,
 Gilbert T Chua^{2†}, MB, BS, FHKAM (Paediatrics), Christy Wan¹, MB, BS, SH Lau¹, MB, BS, Samuel CS Ho¹, MB, BS,
 Jaime S Rosa Duque², MD, PhD, Ian CK Wong^{3,4}, PhD, FRCPCH, Kelvin KW To⁵, MD, FRCPATH,
 Winnie WY Tso², FHKAM (Paediatrics), Christine S Wong⁶, MRCP, FHKCP, Marco HK Ho², MD, FHKAM (Paediatrics),
 Janette Kwok⁷, PhD, FRCPA, CB Chow¹, MD, FHKAM (Paediatrics), Paul KH Tam^{8,9}, FRCS, FRCPCH,
 Godfrey CF Chan², MD, FRCPCH, WH Leung², MD, PhD, YL Lau², MD, FRCPCH, Patrick Ip², MPH, FHKAM (Paediatrics),
 Mike YW Kwan^{1*}, MSc (Applied Epidemiology) CUHK, FHKAM (Paediatrics)

¹ Department of Paediatrics and Adolescent Medicine, Princess Margaret Hospital, Hong Kong

² Department of Paediatrics and Adolescent Medicine, Li Ka Shing Faculty of Medicine, The University of Hong Kong, Hong Kong

³ Centre for Safe Medication Practice and Research, Department of Pharmacology and Pharmacy, The University of Hong Kong, Hong Kong

⁴ Research Department of Practice and Policy, UCL School of Pharmacy, University College London, United Kingdom

⁵ Department of Microbiology, Carol Yu Centre for Infection, Li Ka Shing Faculty of Medicine, The University of Hong Kong, Hong Kong

⁶ Dermatology Division, Department of Medicine, Queen Mary Hospital, Hong Kong

⁷ Division of Transplantation and Immunogenetics, Department of Pathology, Queen Mary Hospital, Hong Kong

⁸ Division of Paediatric Surgery, Department of Surgery, The University of Hong Kong, Hong Kong

⁹ Dr Li Dak-Sum Research Centre, The University of Hong Kong–Karolinska Institutet Collaboration in Regenerative Medicine, The University of Hong Kong, Hong Kong

† Co-first authors

* Corresponding author: kwanyw1@ha.org.hk

This article was published on 17 Mar 2022 at www.hkmj.org.

Hong Kong Med J 2022;28:175–7

<https://doi.org/10.12809/hkmj219690>

Case report

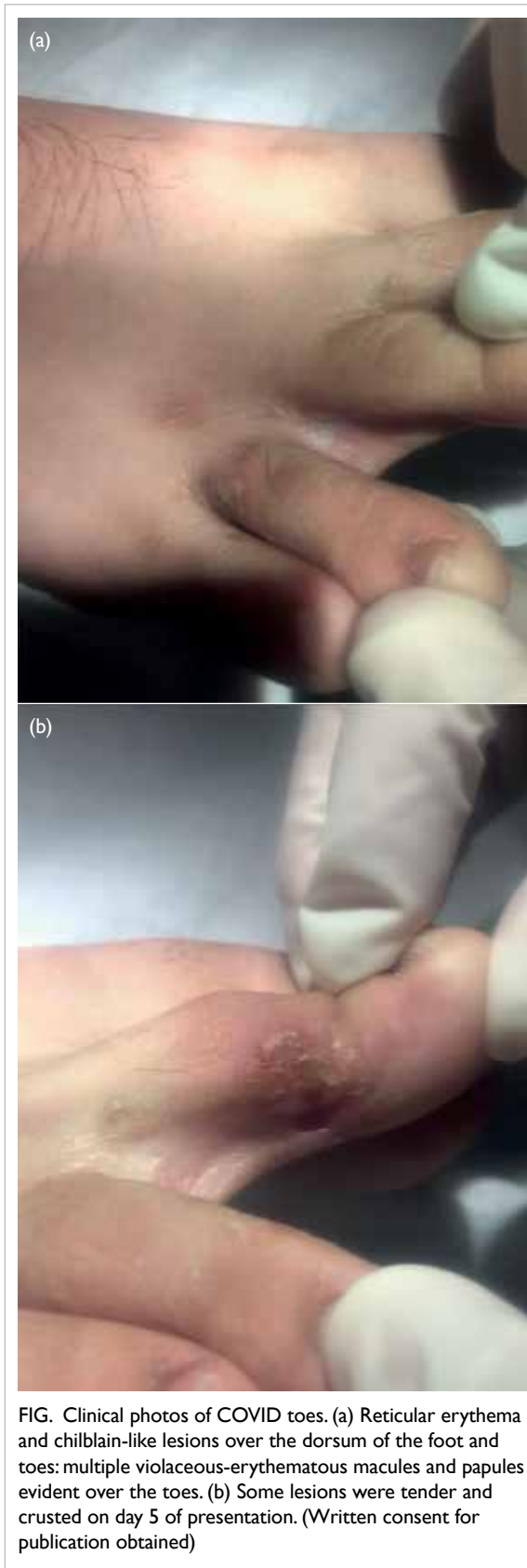
In July 2020, a 17-year-old Pakistani boy presented with pain in his right foot unrelated to trauma or insect bite, after returning from Pakistan. The following day he tested positive for severe acute respiratory syndrome coronavirus 2 (SARS-CoV-2) infection. He had no previous medical history but was obese with a body mass index of 32.4 kg/m². He denied any camping, water-trekking, or outdoor barefoot walking while in Pakistan. Physical examination revealed multiple purplish, flat, dry lesions <5 mm in diameter on his right toes and dorsum of the foot. They were tender on palpation but there was no surrounding erythema (Fig). No lesions were evident on the left foot or elsewhere and he had no symptoms or signs suggestive of any systemic autoimmune disorder. Pain associated with the lesions subsided by day 4 of illness. Some lesions spontaneously resolved but some became raised and crusted after day 3 (Fig). Topical fusidic acid for 1 week was prescribed to treat any potential bacterial infection. Of note, he developed a fever up to 39°C on day 8 and a productive cough. Vital signs remained stable with no respiratory distress or need for oxygen therapy. Chest X-ray did not show pneumonic changes and fever subsided within 24 hours. White blood cell count and differential were normal and C-reactive protein was 28 mg/L. Alanine aminotransferase was initially elevated at 131 U/L but showed a downward trend on rechecking. Clotting profile and D-dimer were normal. On day 12,

SARS-COV-2 immunoglobulin G was detected and the patient was discharged from the hospital. His toe lesions resolved completely a few days later.

Discussion

Rash is an uncommon symptom in coronavirus disease 2019 (COVID-19) infection.¹ It has been described in Italy where 20% of COVID-19 patients developed cutaneous signs, including erythematous rash and widespread urticarial or vesicular lesions, at disease onset or following hospitalisation. The lesions usually subsided after a few days and there was no correlation with disease severity.² Cutaneous manifestations included pseudo-chilblain (pernio-like), vesicular eruptions, urticarial lesions, maculopapular eruptions, and livedo or necrosis.^{2,3}

Classic chilblains (or pernios) are inflammatory skin lesions that occur on the dorsal surface of the fingers and toes. They form painful and itchy erythematous and oedematous nodules that may ulcerate. They are triggered by cold and usually recur yearly during winter.³ Since March 2020, cases of acral lesions resembling chilblains have been reported across Europe, coinciding with the beginning of the COVID-19 outbreak. These lesions have differed to classic ones, showing an equal sex distribution, absence of obvious triggering factors, and involvement of the feet and distal third of the legs.³ They have been seen more commonly in previously healthy children or adolescents aged >10 years, almost always (74%-100%) on the feet but



occasionally on the hands and fingers. The lesions were multiple and varied in size from a few millimetres to centimetres and were described as erythematous, violaceous, swollen, or purpuric. Itchiness and mild pain were frequently reported but required only symptomatic treatment. Lesions started to regress within 12 days to 8 weeks with complete resolution. The appearance of chilblain-like lesions was not thought to be associated with a poor disease outcome.^{2,3} A major limitation of these reports is that only 11% of cases hospitalised tested positive for SARS-CoV-2 by polymerase chain reaction (PCR), with the remainder untested or testing negative. Some authors have attributed this to the low sensitivity of tests or low viral load in children.³ The pathophysiological relationship between COVID-19 infection and chilblain-like lesions remains poorly understood, but has been hypothesised to be related to type 1 interferonopathies.³

Our patient is one of the few reported cases of laboratory-confirmed SARS-CoV-2 infection with chilblain-like lesions. To date, our patient is the only child in Hong Kong to present with SARS-CoV-2 infection as well as so-called “COVID toe”.¹ Currently, there are insufficient data to determine a clear relationship between these dermatological symptoms and COVID-19. Rash is a common manifestation of many diseases and may not be associated COVID-19 infection. A recent case series of 17 adolescents in Italy who developed chilblain-like lesions during the first wave of COVID-19 screened negative on SARS-CoV-2 PCR of nasopharyngeal swabs, negative for SARS-CoV-2 immunoglobulin M and immunoglobulin G, and had no viral genome in biopsy specimens. However, this report was limited by its small sample size and did not compare data with an age- and gender-standardised background incidence of chilblains in the population.⁴ Most patients with dermatological manifestations were not confirmed to be infected with SARS-CoV-2. Another systematic review also concluded that some, but not all paediatric cases, who developed chilblain-like lesions during the COVID-19 pandemic had positive SARS-CoV-2 PCR, serology or viral particles confirmed in electron microscopy.⁵ Larger-scale epidemiological study is needed to confirm an association between these chilblain-like lesions and COVID-19 infection. Reported manifestations and histological findings were too heterogeneous to ascertain the pathophysiology. Nevertheless, physicians should remain vigilant since dermatological manifestations may be the first or only symptom in patients with COVID-19 infection,^{2,3} enabling a timely diagnosis of COVID-19 infection to reduce transmission. Physicians should also consider the possibility of coagulopathies and interferonopathies.

Author contributions

Concept or design: MYW Kwan, P Ip.

Acquisition of data: C Wan, SH Lau, SCS Ho, JS Rosa Duque.

Analysis or interpretation of data: C Wan, SH Lau, SCS Ho, JS Rosa Duque.

Drafting of the manuscript: JSC Wong, TS Wong, GT Chua.

Critical revision of the manuscript for important intellectual content: ICK Wong, KKW To, WWY Tso, CS Wong, MHK Ho, J Kwok, CB Chow, PKH Tam, GCF Chan, WH Leung, YL Lau.

All authors approved the final version of the manuscript and agreed to be accountable for all aspects of the work in ensuring that questions related to the accuracy or integrity of any part of the work are appropriately investigated and resolved.

Funding/support

This study is supported by the Collaborative Research Fund (CRF) 2020/21 and One-off CRF Coronavirus and Novel Infectious Diseases Research Exercises (Ref: C7149-20G).

The funders had no role in study design, data collection and analysis, decision to publish, or preparation of the manuscript.

Ethics approval

The patient was treated in accordance with the Declaration of Helsinki, provided informed consent for the treatment/procedures, and provided consent for publication.

References

1. Chua GT, Wong JS, Lam I, et al. Clinical characteristics and transmission of COVID-19 in children and youths during 3 waves of outbreaks in Hong Kong. *JAMA Network Open* 2021;4:e218824.
2. Andina D, Belloni-Fortina A, Bodemer C, et al. Skin manifestations of COVID-19 in children: Part 2. *Clin Exp Dermatol* 2021;46:451-61.
3. Andina D, Belloni-Fortina A, Bodemer C, et al. Skin manifestations of COVID-19 in children: Part 1. *Clin Exp Dermatol* 2021;46:444-50.
4. Discepolo V, Catzola A, Pierri L, et al. Bilateral chilblain-like lesions of the toes characterized by microvascular remodeling in adolescents during the COVID-19 pandemic. *JAMA Network Open* 2021;4:e2111369.
5. Koschitzky M, Oyola RR, Lee-Wong M, Abittan B, Silverberg N. Pediatric COVID toes and fingers. *Clin Dermatol* 2021;39:84-91.