



■ FOOT & ANKLE

The metatarsus adductus effect by the syndesmosis procedure for hallux valgus correction

**D. Y. Wu,
E. K. F. Lam**

From Hong Kong
Adventist Hospital,
Hong Kong, China

Aims

The purpose of this study is to examine the adductus impact on the second metatarsal by the nonosteotomy nonarthrodesis syndesmosis procedure for the hallux valgus deformity correction, and how it would affect the mechanical function of the forefoot in walking. For correcting the metatarsus primus varus deformity of hallux valgus feet, the syndesmosis procedure binds first metatarsal to the second metatarsal with intermetatarsal cerclage sutures.

Methods

We reviewed clinical records of a single surgical practice from its entire 2014 calendar year. In total, 71 patients (121 surgical feet) qualified for the study with a mean follow-up of 20.3 months (SD 6.2). We measured their metatarsus adductus angle with the Sgarlato's method (SMAA), and the intermetatarsal angle (IMA) and metatarsophalangeal angle (MPA) with Hardy's mid axial method. We also assessed their American Orthopaedic Foot & Ankle Society (AOFAS) clinical scale score, and photographic and pedobarographic images for clinical function results.

Results

SMAA increased from preoperative 15.9° (SD 4.9°) to 17.2° (5.0°) ($p < 0.001$). IMA and MPA corrected from 14.6° (SD 3.3°) and 31.9° (SD 8.0°) to 7.2° (SD 2.2°) and 18.8° (SD 6.4°) ($p < 0.001$), respectively. AOFAS score improved from 66.8 (SD 12.0) to 96.1 (SD 8.0) points ($p < 0.001$). Overall, 98% (119/121) of feet with preoperative plantar calluses had them disappeared or noticeably subsided, and 93% (113/121) of feet demonstrated pedobarographic medialization of forefoot force in walking. We reported all complications.

Conclusion

This study, for the first time, reported the previously unknown metatarsus adductus side-effect of the syndesmosis procedure. However, it did not compromise function restoration of the forefoot by evidence of our patients' plantar callus and pedobarographic findings.

Level of Clinical Evidence: III

Cite this article: *Bone Jt Open* 2021;2-3:174–180.

Keywords: Hallux valgus, Metatarsus primus varus, Bunion, Syndesmosis procedure, Metatarsus adductus

Introduction

Hallux valgus (HV) is a common foot deformity and the commonest surgical condition of the foot. Its surgical result correlates with correction of its underlying metatarsus primus varus (MPV) deformity.¹ MPV deformity is varus deviation of a destabilized first metatarsal.^{2,3} The fundamental surgical principles in MPV correction are first metatarsal realignment and re-stabilization. The long-evolving osteotomy and arthrodesis

techniques have been most popular among foot surgeons.^{4,5} However, the soft-tissue approach by the syndesmosis procedure (SP) has also long been proven effective.⁶⁻⁸

MPV deformity is an acquired and progressive condition. Its first metatarsal and metatarsocuneiform joint are unstable and can be hypermobile.^{2,3} The intermetatarsal binding concept by cerclage sutures has been able to realign the first metatarsal satisfactorily without osteotomy.⁹ It realigns the

Correspondence should be sent to Daniel Yiang Wu; email: dymjwu@gmail.com

doi: 10.1302/2633-1462.23.BJO-2020-0195.R1

Bone Jt Open 2021;2-3:174–180.

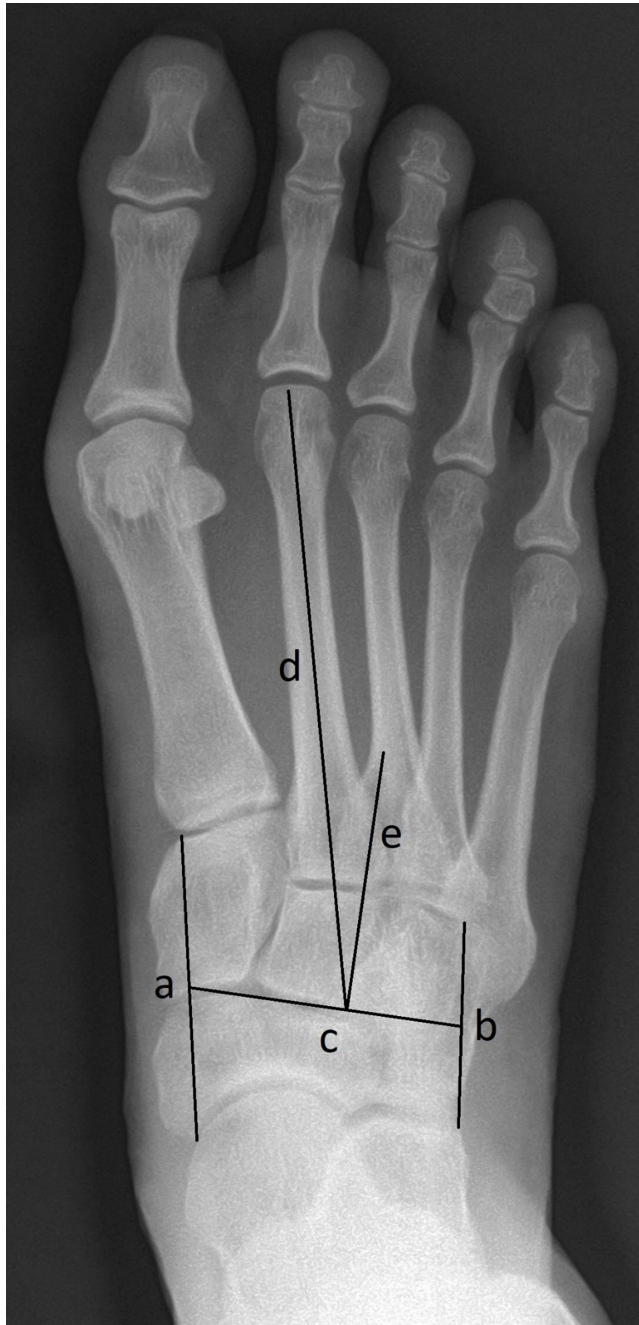

Fig. 1

Sgarlato's metatarsus adductus angle measurement method: Line A extends between the most lateral point of the fourth metatarso-cuboid and the calcaneo-cuboid joints. Line B extends between the most medial point of the talo-navicular and the medial cuneiform-first metatarsal joints. Line C extends between midpoints of lines A and B. Line D represents the longitudinal axis of the second metatarsal bone. Line E is perpendicular to line C and represents the longitudinal axis of the lesser tarsus. Sgarlato's angle is between the lines D and E.

first metatarsal by binding it to the adjacent second metatarsal with intermetatarsal cerclage sutures.⁹ It has also been shown capable of restabilizing the first metatarsal and preventing MPV recurrence by inducing a syndesmotic soft-tissue bonding to stabilize the first metatarsal

to the second metatarsal.¹⁰ However, the forces needed for the correction of the MPV deformity and the maintenance of the first metatarsal stability may affect the alignment of the second metatarsal, since first metatarsal bears the most stress of forefoot for pushing-off in walking.¹¹

This study was to primarily identify any significant varus deviation effect on the second metatarsal and related function compromise after the SP. We hypothesized that any metatarsus adductus effect by the SP may not compromise function restoration of the forefoot because congenital MA deformity has not been known to do so.¹²

Methods

The surgeon-author (DYW) has a surgical practice in which he has applied the SP technique exclusively to all his hallux valgus deformity corrections, regardless of their severity, for more than 30 years. Our indications for surgical correction were radiologically the intermetatarsal angle (IMA) greater than 9° or the metatarsophalangeal angle (MPA) greater than 15° , and clinically unsuccessful alleviation of hallux valgus related pain symptoms such as bunion bursitis, metatarsalgia, and clawed lesser toes with conservative measures for more than six months. The surgeon tried to follow up with his surgical patients for two years whenever possible for radiological, photographic, and pedobarographic assessment. He randomly picked the 2014 calendar year for this study. All available and relevant clinical records and investigative images were retrieved from his electronic databank and reviewed. He did not specifically recall any patient for this study. No patients were rejected and no other surgical techniques were conducted. There was a total of 128 foot procedures in 73 patients. All working data for this study and more than 850 working images can be found in Supplementary Material, including the seven excluded feet for failing to return for a minimum six-month assessment (Bilateral cases 1701 and 1735) and for their postoperative stress fractures (Case 1697L, 1725 R and 1742 R). The final cohort composed of 71 patients of 50 bilateral procedures and 21 single procedures for a total of 121 foot-procedures. There were 62 females and nine males. The mean follow-up time was 20.3 months (6 to 36). The reason for not setting a longer minimum follow-up criterion than six months was that past studies of the SP revealed no more statistically significant MPV and HV deformity recurrence from the sixth postoperative month up to five years.^{8,10}

Patients' preoperative, six-month postoperative, and final follow-up dorsoplantar-view radiographs were reviewed. The majority of radiographs were done in the surgeon-author's clinic with patients standing over the same foot markings on the platform of a computerized digital podiatric x-ray machine manufactured by 20/20

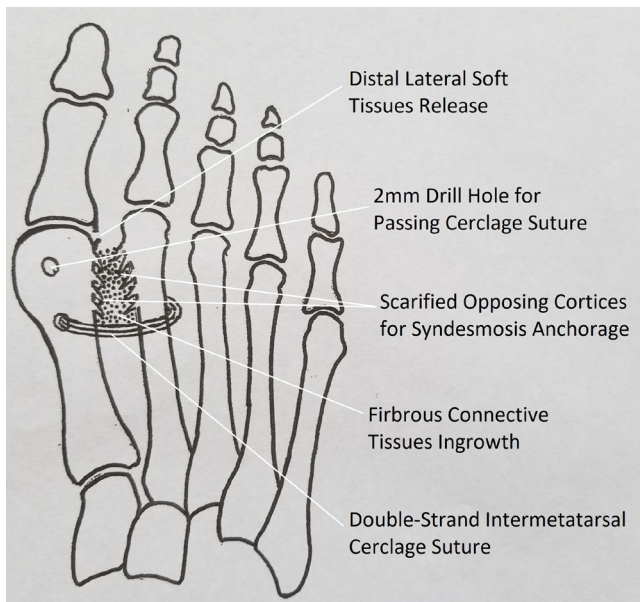


Fig. 2

Schematic illustration of key features of the syndesmosis procedure.

Imaging (USA) with its cathode tilted 30° posteriorly. Their second metatarsal alignment relative to the lesser tarsals' vertical axis was determined with the Sgarlato's method for measuring the metatarsus adductus angle (SMAA)¹³ (Figure 1). The HV deformity was defined by the MPA and their MPV deformity was defined by the IMA. They were all measured with Hardy's mid-axial line method¹⁴ by the same nurse in his clinic with the assistance of a built-in software programme (Opal-RAD; Viztek, USA).

Patients' clinical results were determined by the 100-point Hallux Metatarsophalangeal-Interphalangeal Scale of the American Orthopaedic Foot and Ankle Society (AOFAS).¹⁵ Photographs of their pre- and final postoperative plantar calluses and pedobarographic studies with the F-scan of Tekscan (USA) were reviewed.

Surgical principle. The detailed surgical technique of the SP has been well described in the past (Figure 2).^{6,8-10} The correction of the MPV deformity is achieved by realigning the first metatarsal and correction of the HV deformity by releasing the distal lateral soft-tissue contracture. The first metatarsal is realigned by tying it to the second metatarsals with two No. 2 absorbable Polydioxanone sutures (PDS) and two 2-0 nonabsorbable Ethibond double-strand cerclage sutures through 2 mm drill holes in the distal half of the first metatarsal and around the second metatarsal. Sutures were passed with a straight loose needle through first metatarsal drill holes and then around the second metatarsal with a curved loose needle. The distal lateral soft-tissue release was carried out with an inverted "T" incision. The horizontal incision was for releasing the metatarsosesamoid ligament to facilitate fibula sesamoid spontaneous realignment. The vertical incision was for releasing the lateral collateral ligament

of the metatarsophalangeal joint to facilitate spontaneous hallux realignment once the first metatarsal was realigned with cerclage sutures. To minimize second metatarsal pressure erosion by the cerclage sutures, a mini stainless steel plate was interposed between them. All feet had their redundant medial skin and capsuloligamentous tissues excised after first metatarsal realignment and bunionectomy.

Additional surgery. Four feet also underwent capsulotomy, collateral ligaments release and extensor tendon lengthening of the metatarsophalangeal joint for dorsal dislocation of clawed lesser toes. No other additional surgeries such as Akin,¹⁶ Weil,¹⁷ or other lesser metatarsal osteotomies was performed.

Postoperative protocol. Full weight-bearing walking was allowed and crutches were indicated for outdoor walking from the first postoperative day. Walking was restricted to an average of 3,000 steps a day for three months. All patients were instructed to carry out their own toe exercises, and no patient required physiotherapy. A forefoot cast was applied ten days postoperatively when wounds had largely healed and swelling subsided. High-heeled shoes and running were allowed after the sixth postoperative month.

Statistical analysis. The data were analyzed using JMP Pro 15.0.0 (SAS Institute, USA). Shapiro-Wilk test was used to validate the normality assumption for the data that the null hypothesis of data being normally distributed cannot be rejected in all measurements. Paired *t*-test was adopted to test the effectiveness of the syndesmosis procedure in terms of the mean of the differences of IMA or MPA before and after the surgery. Pearson correlation coefficient was used to assess the strength of association between two measurements. Partial correlation analysis was carried out to assess the strength of correlation between two variables by controlling for the effect of a third variable. All tests were two-tailed, and a *p*-value < 0.05 was considered statistically significant.

Results

Radiological. IMA, and MPA were satisfactorily corrected by the sixth postoperative month and maintained until final follow-up examination (Table I). SMAA was significantly increased for the same time period (Table I). In total, 72 (60%) preoperative and 90 (74%) final postoperative feet had SMAA > 15°.

AOFAS score. Preoperative AOFAS score averaged a mean of 66.8 (standard deviation (SD) 12.0) points and improved to 96.1 (SD 8.0) points at the final follow-up examination.

Plantar callus observation. Overall, 119 feet (98%) had preoperative and final follow-up plantar view photographs. Of these, 104 feet had palpable and visible calluses under the forefoot and 69 (66.3%) of these feet had complete remission and the rest had substantial

Table I. Radiological finding of Sgarlato's metatarsus adductus angle (SMAA), intermetatarsal angle (IMA), and metatarsophalangeal angle (MPA) of the cohort (n = 121)

Timepoint	Mean SMAA, ° (range)	Mean IMA, ° (range)	Mean MPA, ° (range)
Preop	15.9 (0 to 30)	14.6 (6.5 to 24.2)	31.9 (16.5 to 52.8)
6 mths	17.6 (-1 to 30)	7.5 (2.9 to 12.8)	18.9 (8.4 to 38.9)
Final	17.2 (0 to 29)	7.2 (1.3 to 14.2)	18.8 (4.8 to 38.7)

Table II. Mean of Sgarlato's metatarsus adductus angle (SMAA), intermetatarsal angle (IMA), metatarsophalangeal angle (MPA), and American Orthopaedic Foot and Ankle Society clinical score (AOFAS) at different periods and their corresponding mean improvements over different periods.

Variable	Mean value (SD)			Change between timepoints					
	Preop (A)	6 mths (B)	Final (C)	B - A	p-value	C - A	p-value	C - B	p-value
SMAA	15.88 (4.90)	17.60 (5.16)	17.17(4.99)	1.65	< 0.001	1.29	< 0.001	-0.33	< 0.001
IMA	14.55 (3.28)	7.52 (2.00)	7.18(2.19)	-7.00	< 0.001	-7.37	< 0.001	-0.36	< 0.001
MPA	31.88 (8.00)	18.91 (5.83)	18.78 (6.37)	-12.84	< 0.001	-13.10	< 0.001	-0.22	0.427
AOFAS	66.75 (12.00)		96.09 (7.98)			29.01	< 0.001		

subsidence of their plantar calluses, except for one patient's bilateral hallux callus (Supplementary Material: Case 1681) from running marathons. The most common callus site was under mid metatarsal heads of 86 feet (71%), and 71 feet (82.6%) had complete remission.

Pedobarographic observation. In total, 116 feet (96%) had preoperative and final follow-up pedobarographic studies by F-scan examination, and 108 feet (93%) had noticeable medialization redistribution of plantar force from mid and lateral metatarsals to the first metatarsal.

Correlation analysis. Comparing to preoperative assessments, there was a significant increase in SMAA and AOFAS scores and a significant decrease in IMA and MPA at all their assessment timepoints ($p < 0.001$), as summarized in Table II.

There were moderate to strong correlations among the AOFAS, IMA, and MPA improvements at the final follow-up ($\text{Corr}(\text{AOFAS}, \text{IMA}) = -0.534$ ($p < 0.001$), $\text{Corr}(\text{AOFAS}, \text{MPA}) = -0.477$ ($p < 0.001$), $\text{Corr}(\text{IMA}, \text{MPA}) = 0.745$ ($p < 0.001$)), but these improvements had no significant correlations with the preoperative SMAA ($\text{Corr}(\text{SMAA}, \text{AOFAS}) = -0.028$ ($p = 0.767$), $\text{Corr}(\text{SMAA}, \text{IMA}) = -0.029$ ($p = 0.756$), $\text{Corr}(\text{SMAA}, \text{MPA}) = -0.011$ ($p = 0.909$)) and postoperative SMAA ($\text{Corr}(\text{SMAA}, \text{AOFAS}) = 0.088$ ($p = 0.339$), $\text{Corr}(\text{SMAA}, \text{IMA}) = -0.090$ ($p = 0.327$), $\text{Corr}(\text{SMAA}, \text{MPA}) = -0.092$ ($p = 0.316$, all paired t-test)). A partial correlation analysis was carried out to assess the strength of correlation between SMAA and MPA by controlling for the effects of IMA. Moderate partial correlations of 0.403, 0.499, and 0.421 (all $p < 0.001$) were observed at preoperative, six-month postoperative, and final follow-up, respectively, which were much stronger than their respective pairwise correlations without controlling for the effects of IMA.

Complications. There was partial MPV deformity recurrence of final IMA $> 10^\circ$ in 10 feet (8%) that averaged a mean of 11.4° (SD 0.8°) from 17.4° (SD 1.8°) preoperatively (Supplementary Table iii). There was also partial HV

deformity recurrence of final MPA $> 20^\circ$ in 46 feet (38%) that averaged a mean of 25.1° (SD 4.5°) from 37.1° (6.6°) preoperatively (Supplementary Table iv). One patient developed more plantar callus (plantomedial aspect of both great toes) postoperatively—a 55-year-old bilateral procedure male patient after having run seven marathons during his first two postoperative years, without complaining about pain and no more lateral wearing of his running shoes (Supplementary Material: Case 1681).

Three feet (2.5%) suffered second metatarsal stress fracture (Supplementary Material: Cases 1697 L, 1725 R, 1742 R). Three feet (2.5%) (Supplementary Material: Cases 1712L, 1716 R, 1747 R) developed asymptomatic peripheral ossification of the syndesmosis with reduced intermetatarsal mobility. One foot (Supplementary Material: Case 1746), a relatively young 63-year-old female patient developed bilateral moderate hallux rigidus with mild discomfort. She was still very satisfied with her otherwise much-improved foot function. One patient (Supplementary Material: Case 1748) had asymptomatic widening of the 2 to 3 intermetatarsal space of her feet after an excellent correction of her severe deformity. There were no infections, transfer metatarsalgia, or neuralgia.

Discussion

The second metatarsal is the most stable of all five metatarsals for its deeply embedded base among adjacent bones, and the first metatarsal is the strongest to meet its greatest demand in loading for walking.¹¹ Under certain circumstances, the first metatarsal may become destabilized and displaced medially to develop the MPV deformity.

Bone stability relies mainly on ligaments for its static stability and muscles for its dynamic stability.¹² The exact mechanism for first metatarsal stability is complex and not fully understood. Without any muscles attached to it distally, it depends mostly on ligaments for its static stabilization and the windlass mechanism

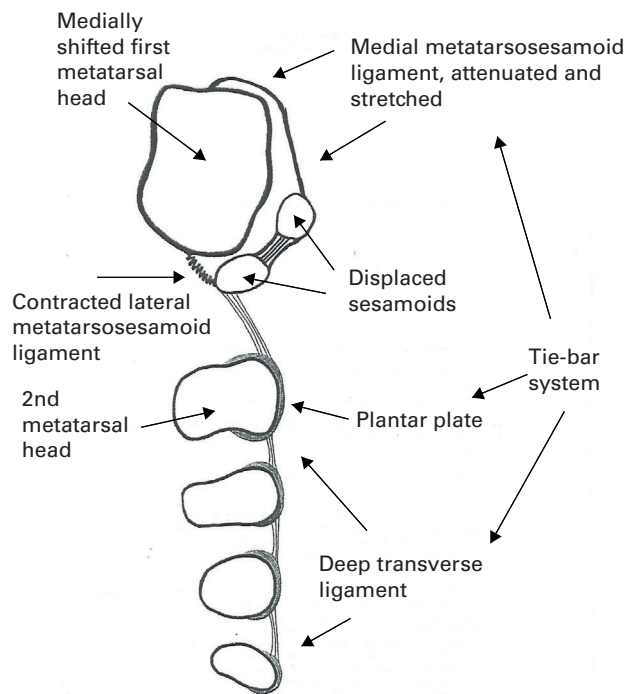


Fig. 3

Cross-section of the metatarsus primus varus deformity demonstrating the failure of its tie-bar system at the medial metatarsosesamoid ligament.

for its dynamic stabilization.^{18,19} Stainsby²⁰ described a critical tie-bar system to maintain the stability between metatarsal heads. The medial metatarsosesamoid ligament of HV feet at the very medial end of this stabilizing system was found attenuated and stretched to have allowed the first metatarsal head to slip away medially (Figure 3). This failed ligament seemed to be the final common denominator of all acquired MPV deformity (Supplementary Material: Case 1748). Many precipitating factors behind this key anatomical failure have been identified, such as heredity, female sex, shoes, and degeneration.²¹ As the MPV deformity progresses, the windlass mechanism will be compromised and the first metatarsal becomes further destabilized.²²

The concept of applying intermetatarsal cerclage sutures for first metatarsal realignment and inducing a syndesmotic bonding with the second metatarsals for its stability was first reported in 1961.² It was originally referred to as an "osteodesis" procedure, which may be misconstrued as a "synostosis" process. Hence, Wu²³ renamed it later to the syndesmosis procedure to reflect its true objective of establishing a soft tissue bonding to

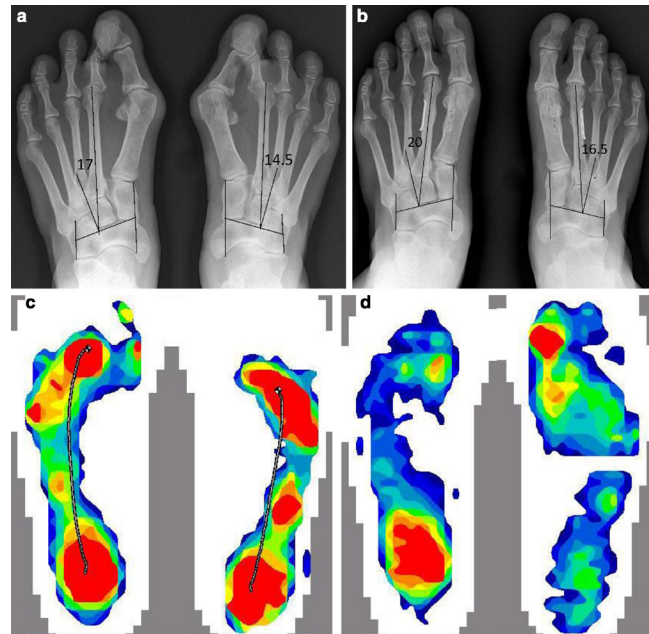


Fig. 4

a) Preoperative standing radiograph of a 55-year-old female with bilateral severe hallux valgus deformity. Sgarlato's metatarsus adductus angle (SMAA) 17° and 14.5°, intermetatarsal angle (IMA) 17.8° and 19.3°, and metatarsophalangeal angle (MPA) 35.6° and 48.1° of her left and right foot respectively. There was also overlapping toes with both second metatarsophalangeal joint (MPJ) dorsally subluxated. b) Her two-year postoperative standing radiograph showed the SMAA was 20° and 16.5°, IMA 7.2° and 6.3°, and MPA 19.9° and 13.7° of her left and right foot respectively. Both overlapping toes deformity and subluxated second MPJs were reduced and maintained. Preoperative metatarsosesamoid dissociation was also much improved. Both metatarsophalangeal joints and metatarsocuneiform joints' congruences were improved. There was increased 2-3 intermetatarsal space from Figure 4a. c) Her preoperative pedobarographic study by F-scan revealed that most plantar force concentrated under midmetatarsal heads (red) during walking instead of the first ray (first metatarsal head and hallux) of normal feet. d) Her two-year postoperative pedobarographic F-scan revealed reduced mid metatarsal pressure bearing and increased first ray function.

prevent MPV recurrence. Its surgical concept is based on the understanding that MPV deformity is primarily a soft-tissue issue of incompetent ligaments, not bone or joint deformity.^{20,24} The displaced first metatarsal, phalanges, sesamoids, and joints are mostly normal and innocent. They can all be realigned without resorting to osteotomy or restabilized without arthrodesis.^{25,26}

This current study reconfirmed past studies that the SP could effectively realign and restabilize the first metatarsal (Table I) for MPV and HV correction (Figure 4) (Supplementary Material: Case 1748).^{6,8-10} However, this is the first study to report that the 1-2 intermetatarsal bonding technique by the SP can result in a significant increase in varus deviation of the second metatarsal (Table II). This assessment was based on the SMAA measuring method. It was chosen for this study because after investigating five different measuring techniques,

Aryan et al²⁷ determined that “The MA angle measured by Sgarlato’s technique demonstrated the highest inter- and intra-observer reliability as well as reliably demonstrating a significant positive correlation between HAV and MA angles.” Although there was slightly reduced SMAA after the sixth postoperative month, there was a sustained increase (Figure 4b; Supplementary Material: Case 1748). It may suggest that it is a one-time alignment adjustment. Whether this realignment was a procedure-related abnormal effect or a restoration to its pre-MPV alignment requires future investigation. Similar study of other intermetatarsal binding techniques may also help provide more information.

MA is a common congenital foot deformity, and it has been reported in 45% to 70% general populations, depending on the angle measuring method.²⁸ Also, about 30% of hallux valgus feet undergoing surgery have been noted to have MA deformity.^{28,29} In total, 72 feet (60%) of our cohort had preoperative SMAA > 15 or the MA deformity as defined by Aryan.¹³ This prevalence increased to 90 feet (74%) at our final postoperative review. Farsetti¹² found that after following 45 congenital MA feet for an average of 32.5 years, all had good foot function with or without early conservative treatment.

The primary function of the foot is locomotion. The first ray alone contributes more than 50% of forefoot’s push-off power. The destabilized and displaced first metatarsal, hallux, and sesamoids would impair the all-important windlass mechanism and normal forefoot function for walking. Pedobarographic examinations have shown a consistent loss of first ray plantar power and consequential lateral migration of walking force to the lesser rays.³⁰ This pathognomonic function deterioration of the first ray has also been well supported by mid metatarsals callus formation and metatarsalgia due to abnormal overuse. Hence, the primary objective of all bunion surgeries has always been restoring the normal mechanical function of the first ray.³¹

Besides improved AOFAS scores, our study also demonstrated that 108 (93%) out of 116 feet had improved mechanical function of increased loading of the first ray and decreased lateral loading by their pedobarographic studies (Figure 4c and d) (Supplementary Material: Case 1748). This mechanical evidence was also substantiated by the subsidence of preoperative plantar calluses in 102 (98%) out of 104 feet. Such consistent pedobarographic and plantar callus improvement suggested satisfactory function restoration. It can probably be only attributed to an overall adequate anatomical realignment of affected bones and joints, including the increased second metatarsal varus alignment or despite it since the usual metatarsus adductus deformity is not known to compromise the function of the foot.⁶ Nonetheless, our statistical analysis found no correlation between pre- or postoperative

SMAA and improved AOFAS score, IMA, or MPA. For the first time to our knowledge, SMAA has been statistically shown not to influence the outcome of hallux valgus correction.

HV feet with metatarsus adductus have been deemed more difficult to correct and having greater incidence of recurrence.³² We ran a partial correlation analysis by controlling the IMA and discovered a statistically significant correlation between SMAA and MPA at all pre- and postoperative examination timepoints. The correlation was much stronger than otherwise without controlling the IMA. This significant finding is for the first time to our best knowledge being reported. It can probably explain the past observation of greater residual MPA than usual after satisfactory MPV correction of HV feet with the metatarsus adductus deformity. Our data also demonstrated that the AOFAS function score and MPA improvements did not correlate with SMAA but IMA improvement.

The second metatarsal fracture is a unique complication of all intermetatarsal binding techniques. Better technical modifications than the concept of a stress-dissipating steel plate are still required to help minimize its occurrence. Theoretically, deviation of the second metatarsal can also put stress on the 2-3 intermetatarsal stability and result in their separation (Supplementary Material: Case 1748) (Figure 4a and b). Future studies are necessary to understand it better.

Medial capsulotomy of the metatarsocuneiform joint (MCJ) had been considered to facilitate first metatarsal realignment and to reduce cerclage suture stress on the second metatarsal, but it was felt unnecessary since there was little resistance felt in its realignment and often MPV was over-corrected.⁹ Neither were there postoperative symptoms to suggest any undue tension on the MCJ. We believe most of the suture tension arose directly from ground-impact in walking.

This study’s weaknesses were mainly a document review of a single surgeon’s work and possible bias. However, they were well compensated by its complete set of the relevant photo-, radio-, and pedobarographic images for open viewing and review. The strength of this study was its highly standardized data collecting methods, and bone- and joint-preserving surgical technique for a consistent intra- and inter-case comparison.

This study reconfirmed that the SP is an effective bone- and joint-preserving technique for hallux valgus deformity correction and recurrence prevention. The SP, assessed by the Sgarlato’s method, did increase varus alignment of the second metatarsal but did not compromise its satisfactory functional outcome. The SMAA did not influence the improvement of several important deformity parameters, except the MPA.

Supplementary material



An image gallery displaying all available working radiographs, photographic, and pedobarographic images, and tables showing Sgarlato's method for measuring the metatarsus adductus angle, intermetatarsal angle and metatarsophalangeal angle, and American Orthopaedic Foot & Ankle Society raw data.

REFERENCES

1. Truslow W. Metatarsus Primus varus or hallux valgus. *JBJS*. 1925;7A(1):98–108.
2. Kimura T, Kubota M, Taguchi T, Suzuki N, Hattori A, Marumo K. Evaluation of First-Ray mobility in patients with hallux valgus using weight-bearing CT and a 3-D analysis system: a comparison with normal feet. *J Bone Joint Surg Am*. 2017;99-A(3):247–255.
3. Shibuya N, Roukis TS, Jupiter DC. Mobility of the first ray in patients with or without hallux valgus deformity: systematic review and meta-analysis. *J Foot Ankle Surg*. 2017;56(5):1070–1075.
4. Pinney S, Song K, Chou L. Surgical treatment of mild hallux valgus deformity: the state of practice among academic foot and ankle surgeons. *Foot Ankle Int*. 2006;27(11):970–973.
5. Pinney SJ, Song KR, Chou LB. Surgical treatment of severe hallux valgus: the state of practice among academic foot and ankle surgeons. *Foot Ankle Int*. 2006;27(12):1024–1029.
6. Irwin LR, Cape J. Intermetatarsal osteodesis: a fresh approach to hallux valgus. *The Foot*. 1999;9:93–98.
7. Wong DWC, Wu DY, Man HS, Leung AKL. The use of a syndesmosis procedure for the treatment of hallux valgus: good clinical and radiological results two years post-operatively. *Bone Joint J*. 2014;96-B(4):502–507.
8. Wu DY, Lam KF. Osteodesis for hallux valgus correction: is it effective? *Clin Orthop Relat Res*. 2015;473(1):328–336.
9. Wu DY, Lam EKF. Radiological evaluation of a preoperative first metatarsal realignment test for metatarsus Primus varus and hallux valgus correction by the Syndesmosis procedure. *Foot Ankle Int*. 2020;41(3):342–349.
10. Wu DY, Lam EKF. Can the syndesmosis procedure prevent metatarsus Primus varus and hallux valgus deformity recurrence? A 5-year prospective study. *J Foot Ankle Surg*. 2018;57(2):316–324.
11. Roy KJ, Force RKJ. Force, pressure, and motion measurements in the foot: current concepts. *Clin Podiatr Med Surg*. 1988;5(3):491–508.
12. Farsetti P, Weinstein SL, Ponseti IV. The long-term functional and radiographic outcomes of untreated and non-operatively treated metatarsus adductus. *J Bone Joint Surg Am*. 1994;76-A(2):257–265.
13. Dawoodi AIS, Perera A. Reliability of metatarsus adductus angle and correlation with hallux valgus. *Foot Ankle Surg*. 2012;18(3):180–186.
14. Hardy RH, Clapham JC. Observations on hallux valgus; based on a controlled series. *J Bone Joint Surg Br*. 1951;33-B(3):376–391.
15. Kitaoka HB, Alexander IJ, Adelaar RS, Nunley JA, Myerson MS, Sanders M. Clinical rating systems for the ankle-hindfoot, midfoot, hallux, and lesser toes. *Foot Ankle Int*. 1994;15(7):349–353.
16. Schilde S, Delank K-S, Arbab D, Gutteck N. Minimally invasive vs open Akin osteotomy. *Foot Ankle Int*. 2020;1071100720962411.
17. Rivero-Santana A, Perestelo-Pérez L, Garcés G, Álvarez-Pérez Y, Escobar A, Serrano-Aguilar P. Clinical effectiveness and safety of Weil's osteotomy and distal metatarsal mini-invasive osteotomy (DMMO) in the treatment of metatarsalgia: a systematic review. *Foot Ankle Surg*. 2019;25(5):565–570.
18. Fuller EA. The windlass mechanism of the foot. A mechanical model to explain pathology. *J Am Podiatr Med Assoc*. 2000;90(1):35–46.
19. Hicks JH. The mechanics of the foot. II. The plantar aponeurosis and the arch. *J Anat*. 1954;88(1):25–30.
20. Stainsby GD. Pathological anatomy and dynamic effect of the displaced plantar plate and the importance of the integrity of the plantar plate-deep transverse metatarsal ligament tie-bar. *Ann R Coll Surg Engl*. 1997;79(1):58–68.
21. Kilmartin TE, Wallace WA. The aetiology of hallux valgus: a critical review of the literature. *The Foot*. 1993;3(4):157–167.
22. Shibuya N, Jasper J, Peterson B, Sessions J, Jupiter DC. Relationships between first metatarsal and sesamoid positions and other clinically relevant parameters for hallux valgus surgery. *J Foot Ankle Surg*. 2019;58(6):1095–1099.
23. Wu DY. Syndesmosis procedure: a non-osteotomy approach to metatarsus primus varus correction. *Foot Ankle Int*. 2007;28(9):1000–1006.
24. Kilmartin TE, Barrington RL, Wallace WA. Metatarsus Primus varus. A statistical study. *J Bone Joint Surg Br*. 1991;73-B(6):937–940.
25. Holmes GB, Hsu AR. Correction of intermetatarsal angle in hallux valgus using small suture button device. *Foot Ankle Int*. 2013;34(4):543–549.
26. Weatherall JM, Chapman CB, Shapiro SL. Postoperative second metatarsal fractures associated with suture-button implant in hallux valgus surgery. *Foot Ankle Int*. 2013;34(1):104–110.
27. Dawoodi AIS, Perera A. Reliability of metatarsus adductus angle and correlation with hallux valgus. *Foot Ankle Surg*. 2012;18(3):180–186.
28. Dawoodi AIS, Perera A. Reliability of metatarsus adductus angle and correlation with hallux valgus. *Foot Ankle Surg*. 2012;18(3):180–186.
29. Loh B, Chen JY, Yew AKS, et al. Prevalence of metatarsus adductus in symptomatic hallux valgus and its influence on functional outcome. *Foot Ankle Int*. 2015;36(11):1316–1321.
30. Hofmann UK, Götze M, Wiesenreiter K, Müller O, Wünschel M, Mittag F. Transfer of plantar pressure from the medial to the central forefoot in patients with hallux valgus. *BMC Musculoskelet Disord*. 2019;20(1):149.
31. Kernoze TW, Roehrs TD, McGarvey S. Analysis of plantar loading parameters pre and post surgical intervention for hallux valgus. *Clin Biomech*. 1997;12(3):S18–S19.
32. Larholt J, Kilmartin TE. Rotational Scarf and akin osteotomy for correction of hallux valgus associated with metatarsus adductus. *Foot Ankle Int*. 2010;31(3):220–228.

Author information:

- D. Y. Wu, MD, Orthopaedic Surgeon, Department of Orthopaedic Surgery, Hong Kong Adventist Hospital, Hong Kong, China.
- E. K. F. Lam, PhD, Associate Professor, Deputy Head of Department, Dean, Faculty of Science, Department of Statistics & Actuarial Science, University of Hong Kong, Hong Kong, China.

Author contributions:

- D. Y. Wu: Conceptualized the study, Performed the surgery, Collected and analyzed the data, Wrote the manuscript.
- E. K. F. Lam: Performed the statistical analysis.

Funding statement:

- No benefits in any form have been received or will be received from a commercial party related directly or indirectly to the subject of this article.

© 2021 Author(s) et al. This is an open-access article distributed under the terms of the Creative Commons Attribution licence (CC-BY-NC-ND), which permits unrestricted use, distribution, and reproduction in any medium, but not for commercial gain, provided the original author and source are credited.