

Three-dimensional Printing Technology for Deep Circumflex Iliac Artery Flap: From Recipient to Donor Sites

Wang-Yong Zhu, PhD
Wing Shan Choi, PhD
Yu-Xiong Su, PhD

Summary: The deep circumflex iliac artery (DCIA) flap is one of the most commonly used vascularized free flaps for jaw reconstruction; however, its clinical application is limited by donor site complications. We aimed to describe a new technique of using 3-dimensionally (3D) printed patient-specific devices for mandibular reconstruction with DCIA flap and simultaneous dental implants, and for donor site restoration after harvesting the DCIA flap. One patient with mandible ameloblastoma underwent mandibular reconstruction using a DCIA flap with the “jaw-in-a-day” approach. The 3D-printed patient-specific devices included mandibular cutting guides, DCIA harvesting and dental implant guide, surgical plate, and iliac prosthesis. The postoperative 1-month accuracy measurement showed the mean distance deviations of the mandible, transferred bone grafts, dental implants and iliac prosthesis were 1.8 mm, 2.1 mm, 0.9 mm, and 1.2 mm, respectively. Three-dimensionally printed iliac prosthesis satisfactorily restored the contour of the iliac crest after DCIA flap harvesting. No complication of donor site was recorded during the follow-up of 12 months. We successfully used 3D-printed patient-specific implants in both donor and recipient sites for DCIA flap jaw reconstruction. Further studies with a larger sample size and long-term follow-up are needed. (*Plast Reconstr Surg Glob Open* 2021;9:e3618; doi: 10.1097/GOX.0000000000003618; Published online 10 June 2021.)

INTRODUCTION

The deep circumflex iliac artery (DCIA) flap provides a strong cortical bone with a reliable vascular source and is widely used for reconstruction of the mandible, where solid bone is required to withstand the normal forces of mastication and for osseointegration.¹ However, its clinical application is limited by donor site complications.²⁻⁴ Here we described a new technique of using 3-dimensionally (3D) printed patient-specific devices for mandibular reconstruction with DCIA flap and simultaneous dental implants, and for donor site restoration after harvesting. This technique has merit not only in improving accuracy of reconstruction and implantation, but also in

restoring donor site contour, thus reducing postoperative complications.

SURGICAL TECHNIQUE

Pre-surgical Planning

A 61-year-old male patient was diagnosed with left mandibular ameloblastoma. Preoperative computed tomography (CT) scans of the maxillofacial area and pelvis were performed, and the data were imported for 3D model reconstruction and virtual surgery in Proplan CMF 3.0 software (Materialise, Leuven, Belgium). The chief surgeon designed the margins of bony resection considering the physical examination information and preoperative imaging. The prosthodontist designed the dental bridge in proper occlusion according to the pre-existing dentition. To achieve good quality cortical bone for dental implants, a contralateral DCIA flap was used to reconstruct the mandibular defect with the iliac crest for repairing mandibular alveoli. After fine adjustments, 2 dental implants were planned on ideal positions.

From the Division of Oral and Maxillofacial Surgery, Faculty of Dentistry, The University of Hong Kong, Hong Kong Special Administrative Region.

Received for publication January 7, 2021; accepted March 24, 2021.

Copyright © 2021 The Authors. Published by Wolters Kluwer Health, Inc. on behalf of The American Society of Plastic Surgeons. This is an open-access article distributed under the terms of the [Creative Commons Attribution-Non Commercial-No Derivatives License 4.0 \(CCBY-NC-ND\)](https://creativecommons.org/licenses/by-nc-nd/4.0/), where it is permissible to download and share the work provided it is properly cited. The work cannot be changed in any way or used commercially without permission from the journal.

DOI: 10.1097/GOX.0000000000003618

Disclosure: All the authors have no financial interest to declare in relation to the content of this article. The study was funded by Health and Medical Research Fund (No. 05161626), HK SAR, and Guangdong Science and Technology Department (No. 2019A050516001).

The virtual surgical planning data were imported into the Materialise 3-Matic 13.0 (Materialise, Leuven, Belgium). The patient-specific devices (Fig. 1), including mandibular cutting guides, DCIA harvesting and dental implant guide, surgical plate, and iliac prosthesis, were custom-designed based on the patient's mandible and iliac crest. The iliac prosthesis, composed of an empty girder titanium framework allowing the reinsertion of the abdominal muscles, and sleeve-like structures at the border increasing the retention and resistance, was designed to accurately restore the defect of the iliac crest. The patient-specific titanium devices were designed as the approach we described in a previous study,⁵ and then printed with grade 2 pure titanium using the selective laser melting technology (Fig. 2).

Intraoperative Steps

The mandibular reconstruction was done using the "jaw-in-a-day" method.⁶ The harvesting of the DCIA flap was performed as the classic procedure. The planned donor bone size was 8.8 cm × 3.5 cm. The osteotomy was done according to the DCIA harvesting and dental implant guide. Next, 2 dental implants were inserted with a torque of 40 N/cm and placed in the iliac crest as planned. Then the iliac bone was cut into 2 segments and fixed by the 3D-printed patient-specific titanium plate. After division of the pedicle, the bone-plate-implants complex was transferred as 1 piece to the recipient site, precisely directed by those pre-drilled screw holes in the mandibular stumps, without further plate bending or flap manipulation. Prefabricated acrylic bridge pontic 34-36 was adapted to the temporary abutments, and occlusion was checked




Fig. 2. The 3D-printed patient-specific devices.

satisfactorily. Meanwhile the customized titanium prosthesis was inserted into the defect at the iliac crest, fixed by mini screws on external surface.

POSTOPERATIVE CARE

One-month postoperative CT imaging data were acquired, and the accuracy of reconstruction was measured by the same methods as we previously reported.⁷

RESULTS

The total operative time was 487 min, ischemic time 79 min, and the intraoperative blood loss was 1700 ml. Intraoperative photographs are shown in Supplemental Digital Content 1, and preoperative and postoperative

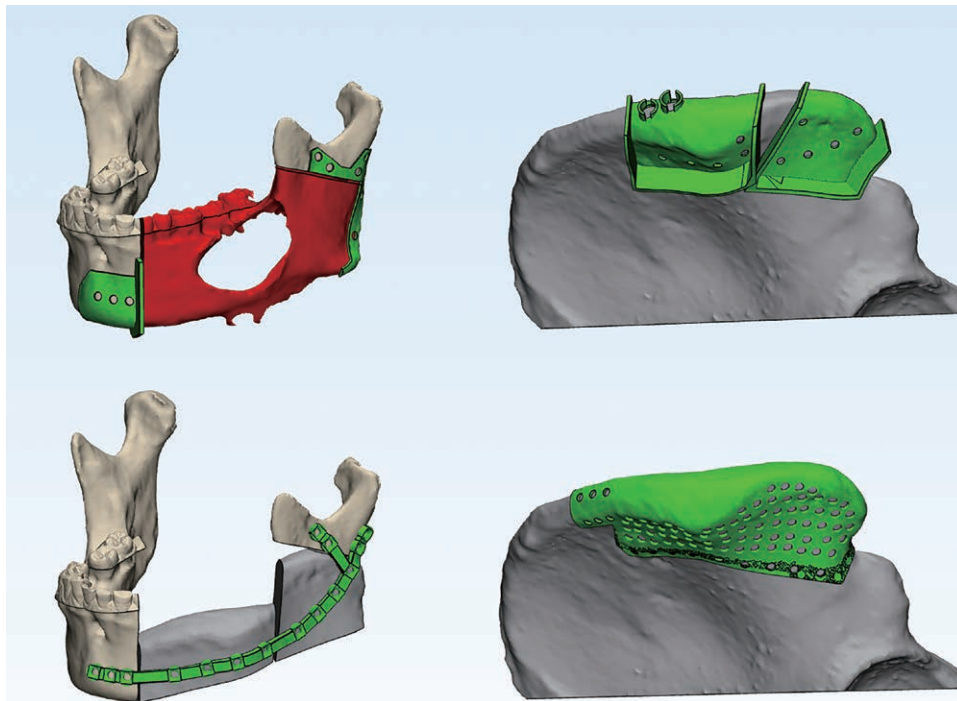


Fig. 1. The virtual design of patient-specific devices, including mandibular cutting guides (top left), DCIA harvesting and dental implant guide (top right), surgical plate (bottom left), and iliac prosthesis (bottom right).

photographs of patient's jaw are shown in Supplemental Digital Content 2. (See figure 1, Supplemental Digital Content 1, which displays intraoperative photographs: a, flap was harvested with the use of DCIA harvesting and dental implant guide; b, two dental implants were placed through the cortical bone of iliac spine, bone graft was segmented, and 3D-printed surgical plate was fixed, to form a “bone-plate-implants complex”; c, the customized iliac prosthesis was implanted in the defect to restore the original shape of iliac crest; d, mandibular cutting guides were placed in the original mandible to guide the osteotomy; e, inset of the bone-plate-implants complex; f, intraoral photograph of reconstructive mandible. <http://links.lww.com/PRSGO/B669>.) (See figure 2, Supplemental Digital Content 2, which displays the preoperative (top) and postoperative (bottom) photographs of patient's occlusion. <http://links.lww.com/PRSGO/B670>.)

The patient's postoperative recovery was uneventful, and the length of hospital stay was 16 days. The patient was able to walk with a stick at discharge. The postoperative 1-month follow-up radiographic images of reconstructive mandible and iliac crest are shown in Figure 3 and Figure 4. The 3D-printed iliac prosthesis adequately restored the contour of the iliac crest. During a follow-up of 12 months, no reconstruction site or donor site complications were recorded.

At 1 month postoperative the mean distance deviation of the mandible, bone grafts, dental implants, and iliac prosthesis were 1.8 mm, 2.1 mm, 0.9 mm, and 1.2 mm, respectively. The intercondylar distance and angulation deviation were 0.3 mm and 7.4 degrees, respectively. The intergonial distance and angulation deviation were 6.2 mm and 5.2 degrees, respectively. Schematic pictures of deviation measurements are shown in Supplemental Digital Content 3. (See figure 3, Supplementary Digital Content 3, which displays the schematic pictures of deviation measurements: a, reconstructive mandible; b, bone graft; c, dental implant; d, iliac prosthesis; e, intercondylar distance and angulation deviation; f, intergonial distance and angulation deviation. <http://links.lww.com/PRSGO/B671>.)

DISCUSSION

In this report, we used 3D-printed patient-specific devices, including mandibular cutting guide, DCIA harvesting and dental implant guide, surgical plate, and iliac

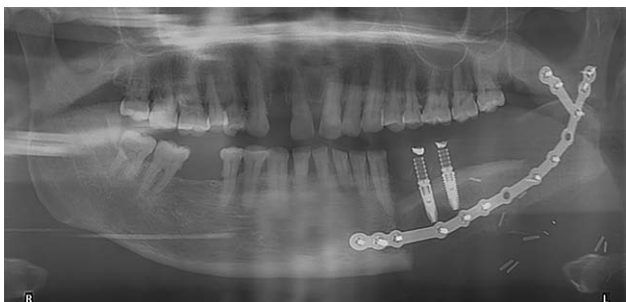


Fig. 3. Postoperative panoramic x-ray of the reconstructed mandible.

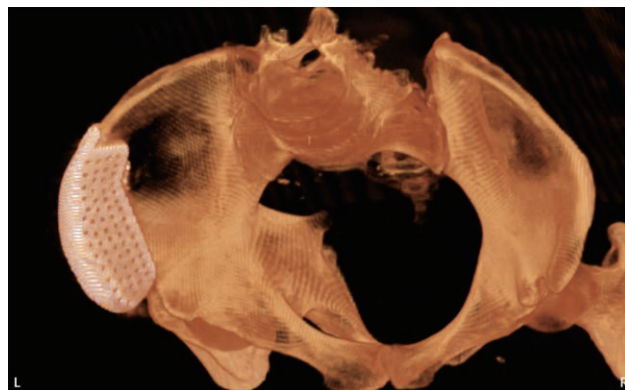


Fig. 4. Postoperative CT of iliac restoration.

prosthesis, for DCIA flap harvesting, mandibular reconstruction and oral rehabilitation, and donor site restoration. The main innovation of our work was using 3D-printed patient-specific implants in both donor and recipient sites for DCIA flap jaw reconstruction. Although the preliminary clinical outcome was satisfactory, long-term follow-up with more cases is needed to reach a final conclusion.

Although vascularized iliac crest provides ideal bone quality and contour for mandibular reconstruction, donor site morbidities, such as chronic pain, abdominal hernia, and loss of the normal bone profile of the hip⁴ limit its clinical application. Among these, herniation after harvesting of DCIA flap occurs in 2.8%–8.3% and can proceed to more severe complications such as bowel obstruction.^{2,3} Furthermore, pelvic bone fracture may occur after harvesting of DCIA flap or iliac bone graft, especially in osteopenic conditions and operations including the anterior iliac crest.⁸ Apparently, an anatomical defect is mainly responsible for these complications. To reduce the risk of hernia after DCIA flap harvesting, the iliac cortex splitting technique was introduced to harvest smaller, thinner bone from the iliac crest,⁹ and the tension-free hernioplasty with various meshes was recommended for hernia repair.¹⁰ In our case, the 3D-printed patient-specific iliac prosthesis provided an anatomical barrier against the herniation, and restored the iliac integrity following its original shape to prevent pelvic bone fracture. During 1 year of follow-up, no donor site complication happened in our case.

CONCLUSIONS

We present our initial experience using 3D-printed patient-specific implants for both functional mandibular reconstruction and DCIA donor site restoration, thus improving the versatility of the DCIA flap in mandibular reconstruction. Further studies with a larger sample size are needed to validate long-term outcomes of this technique.

Yu-Xiong Su, PhD

Prince Philip Dental Hospital 34

Hospital Road Hong Kong

Special Administrative Region

E-mail: richsu@hku.hk

REFERENCES

1. Ting JW, Rozen WM, Niomsawatt V, et al. Developments in image-guided deep circumflex iliac artery flap harvest: a step-by-step guide and literature review. *J Oral Maxillofac Surg.* 2014;72:186–197.
2. Kantelhardt T, Stock W, Stützel H, et al. Results at the donor site after free microvascular iliac crest transplantation. *EJ Plastic Surg.* 1999;22:366–369.
3. Ling XF, Peng X, Samman N. Donor-site morbidity of free fibula and DCIA flaps. *J Oral Maxillofac Surg.* 2013;71:1604–1612.
4. Valentini V, Gennaro P, Aboh IV, et al. Iliac crest flap: donor site morbidity. *J Craniofac Surg.* 2009;20:1052–1055.
5. Yang WF, Zhang CY, Choi WS, et al. A novel ‘surgeon-dominated’ approach to the design of 3D-printed patient-specific surgical plates in mandibular reconstruction: a proof-of-concept study. *Int J Oral Maxillofac Surg.* 2019;49:13–21.
6. Patel A, Harrison P, Cheng A, et al. Fibular reconstruction of the maxilla and mandible with immediate implant-supported prosthetic rehabilitation: jaw in a day. *Oral Maxillofac Surg Clin North Am.* 2019;31:369–386.
7. Yang WF, Choi WS, Wong MCM, et al. Three-dimensionally printed patient-specific surgical plates increase accuracy of oncologic head and neck reconstruction versus conventional surgical plates: a comparative study. *Annals of Surgical Oncology* 2020.
8. Covani U, Ricci M, Santini S, et al. Fracture of anterior iliac crest following bone graft harvest in an anorexic patient: case report and review of the literature. *J Oral Implantol.* 2013;39:103–109.
9. Taylor GI. Reconstruction of the mandible with free composite iliac bone grafts. *Ann Plast Surg.* 1982;9:361–376.
10. Lak KL, Goldblatt MI. Mesh selection in abdominal wall reconstruction. *Plast Reconstr Surg.* 2018;142(3 Suppl):99S–106S.