

# Diagnostic utility of whole spine and thoracic spine MRI corner inflammatory lesions in axial spondyloarthritis

Shirley Chiu Wai Chan , Philip Hei Li, Kam Ho Lee, Helen Hoi Lun Tsang, Chak Sing Lau and Ho Yin Chung 

*Ther Adv Musculoskel Dis*

2020, Vol. 12: 1–11

DOI: 10.1177/  
1759720X20973922

© The Author(s), 2020.  
Article reuse guidelines:  
sagepub.com/journals-  
permissions

## Abstract

**Background:** The presence of  $\geq 3$  corner inflammatory lesions has been proposed as the definition of a positive spinal magnetic resonance imaging (MRI) for axial spondyloarthritis (axSpA), but subsequent studies showed inconclusive findings. Our objective was to evaluate whether locations of corner inflammatory lesions (CILs) would affect the diagnostic utility of MRI in axSpA.

**Method:** Two groups were consecutively recruited from eight rheumatology centers in Hong Kong. The 'axSpA' group included 369 participants with a known diagnosis of axSpA. The 'non-specific back pain' (NSBP) control group consisted of 117 participants. Clinical, biochemical, and radiological parameters were collected and all patients underwent MRI of the spine and sacroiliac joints. CILs were assessed based on their locations (cervical, thoracic or lumbar) to determine the optimal cutoff for diagnosis.

**Results:** The cutoff of  $\geq 5$  whole spine CILs (W-CILs) and  $\geq 3$  thoracic spine CILs (T-CILs) had comparable specificity to MRI sacroiliitis. Of 85/369 axSpA patients without sacroiliitis on conventional radiograph or MRI, 7 had  $\geq 5$  W-CILs and 11 had  $\geq 3$  T-CILs. Incorporating the proposed cutoffs into Assessment of SpondyloArthritis international Society axSpA criteria,  $\geq 5$  W-CILs and  $\geq 3$  T-CILs had similar performance when added to the imaging criteria for sacroiliitis (sensitivity 0.79 *versus* 0.80, specificity 0.92 *versus* 0.91).

**Conclusion:** Spinal MRI provided little incremental diagnostic value in unselected axSpA patients. However, in patients without sacroiliitis on MRI or radiographs, 8–13% might be diagnosed by spinal MRI. Thoracic and whole spine MRI had similar diagnostic performance using the proposed cutoff of  $\geq 5$  W-CILs and  $\geq 3$  T-CILs.

**Keywords:** corner inflammatory lesion, diagnosis, MRI, spondyloarthritis

Received: 25 July 2020; revised manuscript accepted: 26 October 2020.

## Introduction

Axial spondyloarthritis (axSpA) is a spectrum of chronic inflammatory diseases affecting the axial skeleton. The presence of sacroiliitis, on either conventional radiographs or magnetic resonance imaging (MRI), forms the backbone criterion in the imaging arm of the Assessment of SpondyloArthritis international Society (ASAS) classification criteria for axSpA.<sup>1,2</sup> However, the inflammatory process is not limited to sacroiliac (SI) joints. One study has shown that spinal

inflammation was found in half of patients with active non-radiographic axSpA in the absence of sacroiliitis on MRI.<sup>3</sup>

A corner inflammatory lesion (CIL) is defined as an increased short tau inversion recovery (STIR) sequence signal at the corner of a vertebral body, which remains normal or hypointense in T1 weighted sequence, present in one or more sagittal slices inclusive of the spinal canal.<sup>4</sup> Multiple CILs increase the diagnostic

Correspondence to:

**Ho Yin Chung**  
Division of Rheumatology  
and Clinical Immunology,  
Department of Medicine,  
The University of Hong  
Kong, Pokfulam, 102,  
Pokfulam Road, Hong  
Kong, China  
[jameschunghoysin@gmail.com](mailto:jameschunghoysin@gmail.com)

**Shirley Chiu Wai Chan**  
**Philip Hei Li**  
**Helen Hoi Lun Tsang**  
**Chak Sing Lau**  
Division of Rheumatology  
and Clinical Immunology,  
Department of Medicine,  
The University of Hong  
Kong, Hong Kong, China

**Kam Ho Lee**  
Department of Radiology,  
Queen Mary Hospital,  
Hong Kong, China

confidence of axSpA.<sup>5</sup> The presence of  $\geq 3$  CILs has been proposed as the definition of a positive MRI of the spine for axial spondyloarthritis by the ASAS/Outcome Measures in Rheumatology (OMERACT) working group.<sup>4</sup> The diagnostic utility of this proposed criterion has been tested by Weber *et al.* in 130 patients, which has shown that when used alone, whole spine CILs have poor positive and negative likelihood ratios (LRs) (positive LR 1.74–2.36, negative LR 0.75–0.84).<sup>6</sup> In addition, combined spine and SI joint MRI add little incremental diagnostic value when compared with SI joint MRI alone.<sup>7</sup> However, no study has evaluated whether the location of CILs will affect the diagnostic utility of these lesions.

In this study, we aimed to systematically evaluate the diagnostic utility of CILs at different locations (cervical, thoracic, and lumbar) in a large tertiary cohort of 486 patients.

## Methods

This was a retrospective study of prospectively acquired data from an on-going multicenter cohort. Detailed methods have been stated in our previous publication<sup>8</sup> and described as below. Data of participants recruited between May 2016 and August 2019 were analyzed and presented in this study.

### Participant recruitment

Two groups of participants were consecutively recruited from eight rheumatology centers in Hong Kong (Queen Mary Hospital, Grantham Hospital, Tung Wah Hospital, Pamela Youde Nethersole Eastern Hospital, Caritas Medical Center, Tseung Kwan O Hospital, Kwong Wah Hospital, and Prince of Wales Hospital). The “axSpA” group included participants with a known expert diagnosis of axSpA and fulfilling the 2009 ASAS criteria for axSpA.<sup>2</sup> Other inclusion criteria were (i) age >18 years, (ii) current back pain of all types, (iii) ability to give written consent, and (iv) biologics-naïve. Exclusion criteria included (i) pregnancy and (ii) inability to undergo MRI examination. The “non-specific back pain” (NSBP) control group consisted of participants with chronic back pain without a diagnosis of axSpA. NSBP was defined as back pain without a specific and identified pathology such as trauma, tumor, infection, deformity, and nerve compression.

### Confirmation of disease diagnosis

An independent rheumatologist (HHLT), blinded to the MRI data, confirmed correct patient allocation into the axSpA and NSBP groups according to previous clinical records.

### Clinical and demographic data

Clinical and demographic data were collected at study entry from all recruited participants. These data included age, sex, smoking status, drinking status, back pain duration and severity (scored on a scale of 0–10), and family history of axSpA. Physical assessments were performed for peripheral joint counts, enthesitis, dactylitis and Bath Ankylosing Spondylitis Metrology Index.<sup>9</sup> All participants were asked to complete three questionnaires: Bath Ankylosing Spondylitis Disease Activity Index,<sup>10</sup> the Bath Ankylosing Spondylitis Functional Index,<sup>11</sup> and the Bath Ankylosing Spondylitis Global Index.<sup>12</sup> Blood parameters including HLA-B27, C-reactive protein level, and erythrocyte sedimentation rate were recorded. Ankylosing Spondylitis Disease Activity Index was calculated based on both erythrocyte sedimentation rate and C-reactive protein.

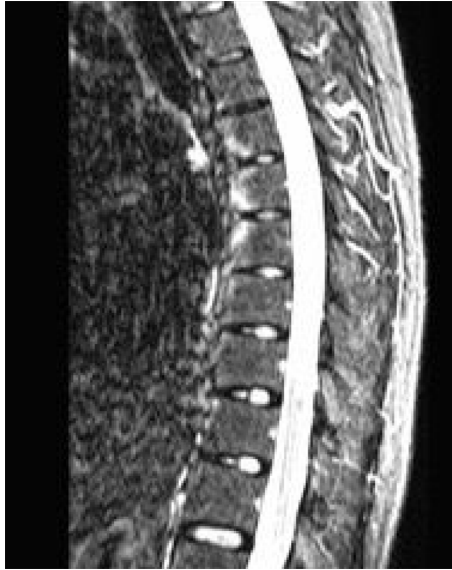### Grading of radiographs of lumbosacral (LS) spine and SI joints

Radiographs of SI joints were graded according to the Modified New York criteria.<sup>13</sup> Bilateral sacroiliitis grade 2 or above, or unilateral grade 3 or above were defined as radiological AS. All LS spine and SI joint radiographs were graded by a musculoskeletal radiologist (KHL) and a rheumatologist (HHLT), with disagreements resolved by consensus.

### Scoring of MRI of spine and SI joints

All recruited participants underwent MRI scans of the whole spine and bilateral SI joints at study entry using a 3T Achieva scanner (Philips Healthcare, Best, The Netherlands). A single torso coil was used to image both the spine and the sacroiliac joints. STIR sequence and T1 weighted images were obtained simultaneously.

The following parameters were employed for the SI joint, both the semi-coronal and semi-axial plane: fast spin-echo STIR. The field of view (FOV) was 20 cm × 20 cm; slice thickness 5 mm with no gap; the number of excitation was 2 and repetition time (TR)/ time to echo (TE) was



**Figure 1.** Corner inflammatory lesions.

3500/80 ms, inversion delay being 140–160 ms; matrix size,  $248 \times 200$ . Twenty-four slices were obtained and the total scan time was 5 min 7 s.

For the spine MRI, fast spin echo STIR sagittal was performed using the following parameters: FOV  $24 \text{ cm} \times 14 \text{ cm}$ ; 4 mm thickness without gap; matrix size  $220 \times 176$ ; number of signal averages/ acquisitions (NSA). The TR/TE/TI was 4760/80/140–160 ms. Fifteen slices were obtained, making a total scan time of 3 min 38 s.

MRI of the SI joints was scored by two independent rheumatologists (HYC and SCWC, with respectively 8 years and 4 years of experience reading MRI of the spine and SI joint) according to the Spondyloarthritis Research Consortium of Canada scoring system,<sup>14</sup> blinded to clinical, radiological parameters and MRI of the spine. A “positive MRI” of the SI joint, indicating sacroiliitis, was defined according to the ASAS handbook<sup>15</sup> as one signal of subchondral bone marrow edema on at least two slices, or more than one signal on a single slice in typical anatomical position (subchondral or periarticular). Similarly, spine MRI was read by HYC and LHP (respectively with 8 years and 4 years of experience in reading MRI of the spine and SI joint) to identify CILs, defined according to the ASAS definition<sup>5</sup> of an increased STIR signal at a vertebral corner, which remains normal or hypointense in T1 weighted sequence, present in at least one sagittal slice (Figure 1). Vertebral levels from C2 to L5 were scored.

#### *Ethics approval*

The study was approved by the Institutional Review Board of The University of Hong Kong/Hospital Authority Hong Kong West Cluster (reference no. UW 14–085). It was conducted in accordance with the Declaration of Helsinki and the guidance of Good Clinical Practice, 30 November 2006.

#### *Statistical analyses*

Baseline demographics and clinical characteristics in the axSpA and NSBP groups were compared using Student’s *t*-tests and chi square tests. The prevalence of at least one CIL at different vertebral levels in the two groups was expressed as percentages. The receiver operating characteristic (ROC) curve was constructed, and the area under curve (AUC) was used to determine the diagnostic utility of CILs at different locations (anterior lesions, posterior lesions, and CIL at different vertebral levels). Diagnostic utility of CILs at different cutoff values was determined by calculating the sensitivity, specificity, positive and negative predictive values, and positive and negative LR. The locations of CILs with the highest sensitivity and specificity greater than that of “positive MRI” sacroiliitis were chosen for further analyses.

The diagnostic utility of these CIL cutoff numbers was further tested when incorporated into the imaging arm of the ASAS criteria. The sensitivity, specificity, positive and negative predictive values, and positive and negative LR were calculated for the imaging arm of the original ASAS criteria. Similarly, we evaluated the utility of the ASAS criteria when we replaced positive MRI sacroiliitis with MRI spine using the CIL cutoff values, and when we combined both MRI SI joint and MRI spine. Clinical utility was determined according to specifications established by Jaeschke *et al.*<sup>16</sup> where a positive LR of 10 and a negative LR of 0.1, positive LR of 5–10 and a negative LR of 0.1–0.2, positive LR of 2–5 and a negative LR of 0.2–0.5, and positive LR of 1–2 and a negative LR of 0.5–1 correspond to substantially, moderately, small, and poor/rarely clinically relevant values respectively.

Cohen’s kappa was used to measure agreement in MRI scoring (sacroiliitis and CILs) by the two readers. Value ranges of 0.00–0.20, 0.21–0.40, 0.41–0.60, 0.61–0.80, 0.81–1.00 represented slight, fair, moderate, substantial, and near perfect agreement, respectively.<sup>17</sup>

All statistics were performed using the International Business Machines Corporation Statistical Package for the Social Sciences (IBM SPSS) package 25.0. A *p*-value of less than 0.05 was defined as statistically significant in all analyses.

## Results

Three hundred and sixty-nine patients with axSpA and 117 participants with NSBP were included. Baseline demographics, clinical parameters, and number of MRI spinal lesions of the axSpA and NSBP groups are described in Tables 1 and 2. Our cohort is characterized by long disease duration, with axSpA group having younger age ( $43.8 \pm 13.6$  years *versus*  $49.1 \pm 15.5$  years;  $p < 0.01$ ), male predominance (59.9% *versus* 29.2%;  $p < 0.01$ ), a greater proportion of smokers (27.9% *versus* 13.7%), and higher levels of CRP ( $1.2 \pm 2.2$  mg/dL *versus*  $0.5 \pm 1.8$  mg/dL;  $p < 0.01$ ).

Inter-reader agreement of positive MRI sacroiliitis was almost perfect (Cohen's kappa values of 0.81). The inter-reader reliability of the number of CILs was excellent (Pearson's correlation coefficient 0.94).

ROC curves were constructed to determine the diagnostic utility of CILs at different vertebral levels (Figure 2). Whole spine CILs (AUC 0.67; 95% confidence interval (CI) 0.62–0.72;  $p < 0.01$ ) and thoracic spine CILs (AUC 0.66; 95% CI 0.61–0.72;  $p < 0.01$ ) had the ability to differentiate between patients without and without axSpA.

MRI sacroiliitis had a sensitivity of 33.6% and specificity of 97.4%. The different cut-off thresholds of CILs when assessed as whole spine and thoracic spine are presented in Table 3. Using a specificity of 97.4% (specificity of MRI sacroiliitis) as threshold, the optimal cutoff values were  $\geq 5$  whole spine CILs and  $\geq 3$  thoracic spine CILs.

In the axSpA group, 85 of 369 (23.0%) patients had no sacroiliitis on MRI or X-ray. Of these 85 patients, 7/85 (8.2%) had  $\geq 5$  whole spine CILs and 11/85 (12.9%) had  $\geq 3$  thoracic CILs. Among NSBP patients, only 1/117 (0.9%) have  $\geq 5$  whole spine CILs and 3/117 (2.6%) have  $\geq 3$  thoracic CILs.

The diagnostic utility of adding the respective proposed CIL cutoff values to the imaging arm of the ASAS criteria for axSpA diagnosis are

presented in Tables 4 and 5. Adding the CIL cutoff values to the existing ASAS imaging criteria only marginally improved the sensitivity except in the non-radiographic subgroup. In the non-radiographic axSpA subgroup, incorporating CIL criteria into the imaging criteria of ASAS axSpA criteria improve the sensitivity (sensitivity 0.38 to 0.43,  $\geq 5$  whole spine CILs; sensitivity 0.38 to 0.46,  $\geq 3$  thoracic spine CILs) with similar specificity (specificity 0.93 to 0.92,  $\geq 5$  whole spine CILs; specificity 0.93 to 0.91,  $\geq 3$  thoracic spine CILs).

## Discussion

This study systemically investigated the diagnostic utility of CILs at different locations (cervical, thoracic, and lumbar) in a large group of participants with back pain of which 369 participants had axSpA and 117 patients had NSBP. Previous studies have proposed different CIL cutoff values for positive MRI of the spine,<sup>4,18</sup> but its usefulness in the diagnosis of axSpA has been questioned in a number of studies.<sup>6,7,19,20</sup> Our study evaluated CILs further grouped by vertebral levels. Similar to previous studies, our study showed that spinal MRI provided little incremental diagnostic value in axSpA when added to standard SI joint imaging among unselected patients, but might be useful in 8–13% of those without sacroiliitis on MRI or radiographs. Thoracic and whole spine MRI had similar diagnostic performance using the proposed cutoff value of  $\geq 5$  whole spine CILs (W-CILs) and  $\geq 3$  thoracic CILs (T-CILs) as “positive MRI” for spinal inflammation.

Compared with a study examining the SPACE and DESIR cohort by Ez-Zaitouni *et al.*<sup>19</sup> we demonstrated a higher frequency of positive MRI of the spine in participants without sacroiliitis using the above proposed criteria. In our cohort of participants with axSpA, 85 out of 369 (23.0%) patients had negative imaging for sacroiliitis by MRI or X-ray. Of these 85 axSpA patients, seven out of 85 (8.2%) had  $\geq 5$  whole spine CILs and 11 out of 85 (12.9%) had  $\geq 3$  thoracic CILs. This might be due to the difference in patient characteristics between the two studies. In the abovementioned study involving the SPACE and DESIR cohort,<sup>19</sup> it was shown that among patients with early disease (defined as chronic back pain of maximally 3 years' duration) only 1–2% of patients without sacroiliitis had a positive MRI spine (defined as the presence of  $\geq 3$

**Table 1.** Baseline characteristics.

	axSpA (n = 369)			NSBP (n = 117)	p-value axSpA versus NSBP
	Total (n = 369)	AS (n = 233)	nr-axSpA (n = 136)		
Age (years)	43.8 ± 13.6	44.2 ± 13.5	43.2 ± 13.7	49.1 ± 15.5	<0.01
Back pain (years)	12.3 ± 11.1	14.0 ± 11.6	9.6 ± 9.6	8.1 ± 9.3	<0.01
Male sex	59.9%	65.2%	50.7%	28.2%	<0.01
HLA-B27	85.6%	84.1%	88.2%	N/A	N/A
Smoker	27.9%	35.6%	14.7%	13.7%	<0.01
Drinker	10.3%	14.2%	3.7%	6.8%	0.36
IBP	57.5%	56.2%	59.6%	34.2%	<0.01
Family history	23.3%	20.2%	28.7%	6.0%	<0.01
CRP (mg/dL)	1.2 ± 2.2	1.4 ± 2.4	0.9 ± 1.8	0.5 ± 1.8	<0.01
ESR (mm/h)	32.4 ± 25.0	35.5 ± 24.9	27.2 ± 24.4	32.1 ± 23.6	0.90
CIL at W-spine	50.1%	2.7 ± 3.8	1.4 ± 3.0	20.5%	<0.01
CIL at C-spine	5.7%	6.0%	5.1%	0.9%	0.90
CIL at T-spine	40.4%	47.6%	27.9%	8.5%	<0.01
CIL at L-spine	23.0%	26.6%	16.9%	12.0%	<0.01
mSASSS	8.7 ± 16.8	11.1 ± 18.7	3.5 ± 10.3	N/A	N/A
ASDAS-CRP	2.0 ± 0.9	2.1 ± 0.9	1.8 ± 0.9	N/A	N/A
ASDAS-ESR	3.1 ± 1.0	3.2 ± 1.0	2.9 ± 1.0	N/A	N/A
BASDAI	4.6 ± 2.1	4.6 ± 2.1	4.4 ± 2.1	N/A	N/A
BASGI	5.0 ± 2.5	5.2 ± 2.5	4.7 ± 2.5	N/A	N/A
BASMI	3.5 ± 1.7	3.8 ± 1.7	2.8 ± 1.4	N/A	N/A
BASFI	2.9 ± 2.4	3.1 ± 2.5	2.5 ± 2.3	N/A	N/A

N/A = no sacroiliitis; absence of sacroiliitis on X-ray or magnetic resonance imaging.

AS, ankylosing spondylitis; ASDAS, Ankylosing Spondylitis Disease Activity Index; axSpA, axial spondyloarthritis; BASDAI, Bath Ankylosing Spondylitis Disease Activity Index; BASFI, Bath Ankylosing Spondylitis Functional Index; BASGI, Bath Ankylosing Spondylitis Global Index; BASMI, Bath Ankylosing Spondylitis Metrology Index; CIL, corner inflammatory lesion; CRP, C-reactive protein; C-spine, cervical spine; ESR, erythrocyte sedimentation rate; HLA, human leucocyte antigen; IBP, inflammatory back pain; L-spine, lumbar spine; mSASSS, modified stoke ankylosing spondylitis spinal score; nr-axSpA, non-radiographic axial spondyloarthritis; NSBP, non-specific back pain; T-spine, thoracic spine; W-spine, whole spine.

CILs). In contrast, our cohort is made up of participants with longer disease duration, older age, higher percentage of HLA-B27 positivity and radiographic sacroiliitis compared with the SPACE and DESIR cohorts. Furthermore, our study included a control group of participants

with NSBP. We demonstrated that the diagnostic utility of thoracic spine MRI was comparable to whole spine MRI. The use of whole spine or thoracic spine MRI might be considered in axSpA patients, especially in those without sacroiliitis on conventional radiograph or MRI.



**Table 2.** Frequency of CILs in different subgroups of patients.

	axSpA (n = 369)	AS (n = 233)	nr-axSpA (MRI SI joint+) (n = 51)	nr-axSpA (MRI SI joint-) (n = 85)	NSBP (n = 117)
CILs $\geq$ 1	185 (50.1%)	136 (58.4%)	19 (37.3%)	30 (35.3%)	24 (20.5%)
CILs $\geq$ 2	144 (39.0%)	107 (45.9%)	15 (29.4%)	22 (25.9%)	15 (12.8%)
CILs $\geq$ 3	107 (29.0%)	80 (34.3%)	12 (23.5%)	15 (17.6%)	6 (5.1%)
CILs $\geq$ 4	93 (25.2%)	69 (29.6%)	12 (23.5%)	12 (14.1%)	1 (0.9%)
CILs $\geq$ 5	63 (17.1%)	49 (21.0%)	7 (13.7%)	7 (8.2%)	1 (0.9%)
CILs $\geq$ 6	47 (12.7%)	37 (15.9%)	5 (9.8%)	5 (5.9%)	1 (0.9%)
CILs $\geq$ 7	40 (10.8%)	33 (14.2%)	3 (5.9%)	4 (4.7%)	1 (0.9%)
CILs $\geq$ 8	30 (8.1%)	25 (10.7%)	2 (3.9%)	3 (3.5%)	1 (0.9%)
CILs $\geq$ 9	24 (6.5%)	21 (9.0%)	0	2 (2.4%)	0
CILs $\geq$ 10	19 (5.1%)	17 (7.3%)	0	2 (2.4%)	0

AS, ankylosing spondylitis; axSpA, axial spondyloarthritis; CIL, corner inflammatory lesion; nr-axSpA, non-radiographic axial spondyloarthritis; MRI, magnetic resonance imaging; NSBP, non-specific back pain; SI, sacroiliac.

The thoracic spine has been shown to have the lowest prevalence of degenerative lesions due to its inherent biomechanics,<sup>21</sup> hence, we proposed its use in the differentiation between axSpA and other NSBP. We found that CILs in the thoracic spinal segments were the most frequent, accounting for 74% of the total number of CILs. This study demonstrated the diagnostic usefulness of CIL in axSpA similar to the result from previous studies.<sup>22,23</sup> From our data, CILs were the most frequent in the thoracic spine even after adjustment for number of vertebrae (Table 6). Also, thoracic CILs were more commonly found in axSpA (40.4%), and less frequently in NSBP patients (8.5%). Furthermore, the average number of thoracic CILs present in SpA patients was greater than that in NSBP patients (mean  $n = 4.3$  versus 2.7). A previous study has proposed  $\geq 3$  CIL as the cutoff value for the diagnosis of axSpA.<sup>4</sup> If we assess thoracic spinal segment alone, the cutoff value of  $\geq 3$  thoracic CILs had a specificity comparable to positive MRI for sacroiliitis but  $\geq 5$  CILs were needed to achieve comparable specificity when the whole spine was considered.

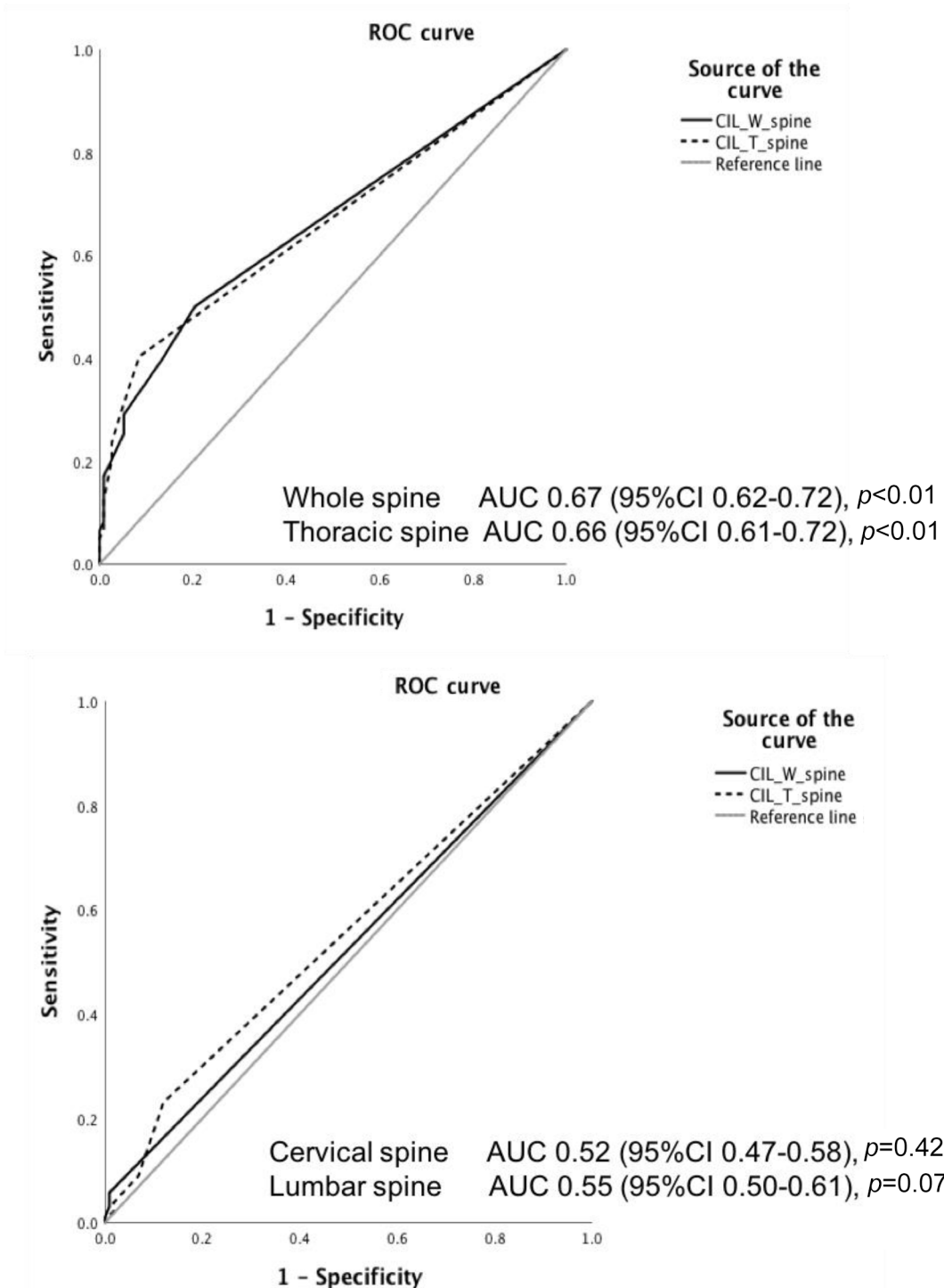
Corresponding to CIL is fatty corner lesion (FCL). It is a well-demarcated fat infiltration in the corner of a vertebral body on T1 MRI

sequence.<sup>24</sup> Fatty lesion is proposed to be the result of resolution of inflammation.<sup>25</sup> We have previously reported the differential diagnostic utility of FCL at different levels<sup>26</sup> and shown that thoracic FCLs are more frequent and have a greater contribution to axSpA diagnosis.

Our study showed that when incorporated into the ASAS criteria, the proposed MRI spine criterion was particularly useful in the group of non-radiographic-axSpA in improving the sensitivity of the imaging arm. In non-radiographic axSpA patients, only 38% have MRI sacroiliitis. By incorporating MRI spine assessment into the ASAS axSpA criteria, the sensitivity of the imaging arm improved (sensitivity 0.38 to 0.43,  $\geq 5$  whole spine CILs; sensitivity 0.38 to 0.46,  $\geq 3$  thoracic spine CILs) with similar specificity (specificity 0.93 to 0.92,  $\geq 5$  whole spine CILs; specificity 0.93 to 0.91,  $\geq 3$  thoracic spine CILs).

#### Limitation

Similar to many other rheumatic diseases, axSpA remained a clinical diagnosis and in this study physician diagnosis was used as the gold standard. Positive MRI sacroiliitis was defined according to ASAS definition and structural lesions were not considered. Even though the overall prevalence of



**Figure 2.** Test precision of corner inflammatory lesions at different spinal levels in axial spondyloarthritis diagnosis.

AUC, area under curve; CI, confidence interval; ROC, receiver operating characteristic; CIL\_W\_spine, corner inflammatory lesions in whole spine; CIL\_T\_spine, corner inflammatory lesions in thoracic spine; CIL\_C\_spine, corner inflammatory lesions in cervical spine; CIL\_L\_spine, corner inflammatory lesions in lumbar spine.

**Table 3.** Sensitivity and specificity of corner inflammatory lesion cutoff thresholds in diagnosis of axial spondyloarthritis.

Proposed cutoff	TP	FP	FN	TN	Sensitivity	Specificity
Whole spine $\geq 1$	185	24	184	93	50.1%	79.5%
$\geq 2$	144	15	255	102	39.0%	87.2%
$\geq 3$	107	6	262	111	29.0%	94.9%
$\geq 4$	93	6	276	111	25.2%	94.9%
$\geq 5$	63	1	206	116	<b>17.1%*</b>	<b>99.1%*</b>
Thoracic spine $\geq 1$	149	10	220	107	40.4%	91.5%
$\geq 2$	124	7	245	110	33.6%	94.0%
$\geq 3$	87	3	282	114	<b>23.6%*</b>	<b>97.4%*</b>
MRI sacroiliitis —	124	3	245	114	33.6%	97.4%

FN, false negative; FP, false positive; MRI, magnetic resonance imaging; TN, true negative; TP, true positive.  
\* $p$ -value = <0.01

**Table 4.** Sensitivity, specificity, positive predictive value, negative predictive value, positive and negative likelihood ratio of different classification criteria.

Imaging arm	TP	FP	FN	TN	SEN	SPEC	PPV	NPV	LR+	LR-
Unaltered	284	8	85	109	0.77	0.93	0.97	0.56	11.0	0.25
MRI SI joint replaced by $\geq 5$ whole spine CILs	247	8	122	109	0.67	0.93	0.97	0.47	9.57	0.35
MRI SI joint replaced by $\geq 3$ T-spine CILs	254	10	115	107	0.69	0.91	0.96	0.48	8.63	0.34
Sacroiliitis or $\geq 5$ whole spine CILs	291	9	78	108	0.79	0.92	0.97	0.58	9.88	0.23
Sacroiliitis or $\geq 3$ T-spine CILs	295	11	74	106	0.80	0.91	0.96	0.59	8.89	0.22

CIL, corner inflammatory lesion; FN, false negative; FP, false positive; LR+, positive likelihood ratio; LR-, negative predictive value; MRI, magnetic resonance imaging; NPV, negative predictive value; PPV, positive predictive value; SEN, sensitivity; SI, sacroiliac; SPEC, specificity; TN, true negative; TP, true positive; T-spine, thoracic spine.

positive MRI sacroiliitis was relatively low, the frequency of positive MRI sacroiliitis in the non-radiographic axSpA subgroup was similar to other cohorts.<sup>27</sup> As a result, the overall performance of the imaging arm was comparable to other international cohorts.<sup>28</sup> Our cohort was characterized by participants with long-standing disease instead of a group of new undiagnosed patients. It is also known that agreement in reading radiographs of sacroiliac joints is only moderate.<sup>29</sup> This could have potentially affected the interpretation of our results. Furthermore, the baseline characteristics between axSpA and NSBP groups were different. However, the frequency of CILs in our control

cohort was similar to that reported in a recent study by Baraliokos *et al.* among healthy individuals.<sup>30</sup> This supports the validity of our cohort as the control group for comparison.

### Conclusion

Spinal MRI provided little incremental diagnostic value in unselected axSpA patients and should not be incorporated as a routine assessment. However, among the subgroup of patients without sacroiliitis on MRI or radiographs, 8–13% might be diagnosed by spinal MRI using the proposed criteria. Thoracic and whole spine MRI



**Table 5.** Subgroup analysis in non-radiographic axial spondyloarthritis. Sensitivity, specificity, positive predictive value, negative predictive value, positive and negative likelihood ratio of different classification criteria.

Imaging arm	TP	FP	FN	TN	SEN	SPEC	PPV	NPV	LR+	LR-
Unaltered	51	8	85	109	0.38	0.93	0.86	0.56	5.43	0.67
MRI SI joint replaced by $\geq 5$ whole spine CILs	14	8	122	109	0.10	0.93	0.64	0.47	1.43	0.97
MRI SI joint replaced by $\geq 3$ T-spine CILs	21	10	115	107	0.15	0.91	0.68	0.48	1.88	0.92
Sacroiliitis or $\geq 5$ whole spine CILs	58	9	78	108	0.43	0.92	0.87	0.58	5.38	0.62
Sacroiliitis or $\geq 3$ T-spine CILs	62	11	74	106	0.46	0.91	0.85	0.59	5.11	0.59

CIL, corner inflammatory lesion; FN, false negative; FP, false positive; LR+, positive likelihood ratio; LR-, negative predictive value; MRI, magnetic resonance imaging; NPV, negative predictive value; PPV, positive predictive value; SEN, sensitivity; SI, sacroiliac; SPEC, specificity; TN, true negative; TP, true positive.

**Table 6.** Frequency of corner inflammatory lesions by spinal segments with adjustment for numbers of vertebrae.

Patient groups	C-spine (C2–7)	T-spine (T1–12)	L-spine (L1–5)	W-spine
All patients <i>N</i> =486	8.5 (51/6)	55.5 (666/12)	34.2 (171/5)	38.0 (871/23)
AxSpA <i>n</i> =369	8.2 (49/6)	53.3 (639/12)	29 (145/5)	35.5 (816/23)
NSBP <i>n</i> =117	0.3 (2/6)	2.3 (27/12)	5.2 (26/5)	2.4 (55/23)

axSpA, axial spondyloarthritis; C-spine, cervical spine; L-spine, lumbar spine; NSBP, non-specific back pain; T-spine, thoracic spine; W-spine, whole spine.

had similar diagnostic performance using the proposed cutoff value of  $\geq 5$  W-CILs and  $\geq 3$  T-CILs as “positive MRI” for spinal inflammation.

### Conflict of interest statement

The authors declare that there is no conflict of interest.

### Funding

The authors disclosed receipt of the following financial support for the research, authorship, and/or publication of this article: This work is supported by the Hong Kong Society of Rheumatology, and Novartis Research.

### ORCID iDs

Shirley Chiu Wai Chan  <https://orcid.org/0000-0002-0640-0676>

Ho Yin Chung  <https://orcid.org/0000-0002-0175-1346>

### Supplemental material

Supplemental material for this article is available online.

### References

- Rudwaleit M, Landewe R, van der Heijde D, *et al.* The development of assessment of SpondyloArthritis international society classification criteria for axial spondyloarthritis (part I): classification of paper patients by expert opinion including uncertainly appraisal. *Ann Rheum Dis* 2009; 68: 770–776.
- Rudwaleit M, van der Heijde D, Landewe R, *et al.* The development of assessment of SpondyloArthritis international society classification criteria for axial spondyloarthritis (part II): validation and final selection. *Ann Rheum Dis* 2009; 68: 777–783.

3. van der Heijde D, Sieper J, Maksymowich WP, *et al.* Spinal inflammation in the absence of sacroiliac joint inflammation on magnetic resonance imaging in patients with active non-radiographic axial spondyloarthritis. *Arthritis Rheum* 2014; 66: 667–673.
4. Hermann KG, Baraliakos X, van der Heijde D, *et al.*; On Behalf of the Assessment in SpondyloArthritis International Society (ASAS). Descriptions of spinal MRI lesions and definition of a positive MRI of the spine in axial spondyloarthritis: a consensual approach by the ASAS/OMERACT MRI study group. *Ann Rheum Dis* 2012; 71: 1278–1288.
5. Bray TJP, Jones A, Bennett AN, *et al.* Recommendations for acquisition and interpretation of MRI of the spine and sacroiliac joints in the diagnosis of axial spondyloarthritis in the UK. *Rheumatology (Oxford)* 2019; 58: 1831–1838.
6. Weber U, Zubler V, Zhao Z, *et al.* Does spinal MRI add incremental diagnostic value to MRI of the sacroiliac joints alone in patients with non-radiographic axial spondyloarthritis? *Ann Rheum Dis* 2015; 74: 985–992.
7. Weber U, Zhao Z, Rufibach K, *et al.* Diagnostic utility of candidate definitions for demonstrating axial spondyloarthritis on magnetic resonance imaging of the spine. *Arthritis Rheumatol* 2015; 67: 924–933.
8. Chung HY, Xu X, Lau VW, *et al.* Comparing diffusion weighted imaging with clinical and blood parameters, and with short tau inversion recovery sequence in detecting spinal and sacroiliac joint inflammation in axial spondyloarthritis. *Clin Exp Rheumatol* 2017; 35: 127–132.
9. Jenkinson TR, Mallorie PA, Whitelock H, *et al.* Defining spinal mobility in ankylosing spondylitis (AS). The Bath AS Metrology Index. *J Rheumatol* 1994; 21: 1694–1698.
10. Garrett S, Jenkinson T, Kennedy LG, *et al.* A new approach to defining disease status in ankylosing spondylitis: the Bath Ankylosing Spondylitis Disease Activity Index. *J Rheumatol* 1994; 21: 2286–2291.
11. Calin A, Garrett S, Whitelock H, *et al.* A new approach to defining functional ability in ankylosing spondylitis: the development of the Bath Ankylosing Spondylitis Functional Index. *J Rheumatol* 1994; 21: 2281–2285.
12. Jones SD, Steiner A, Garrett SL, *et al.* The Bath Ankylosing Spondylitis Patient Global Score (BAS-G). *Rheumatology* 1996; 35: 66–71.
13. van der Linden S, Valkenburg HA and Cats A. Evaluation of diagnostic criteria for ankylosing spondylitis. A proposal for modification of the New York criteria. *Arthritis Rheum* 1984; 27: 361–368.
14. Maksymowich WP, Inman RD, Salonen D, *et al.* Spondyloarthritis Research Consortium of Canada magnetic resonance imaging index for assessment of spinal inflammation in ankylosing spondylitis. *Arthritis Rheum* 2005; 53: 502–509.
15. Sieper J, Rudwaleit M, Baraliakos X, *et al.* The Assessment of SpondyloArthritis international Society (ASAS) handbook: a guide to assess spondyloarthritis. *Ann Rheum Dis* 2009; 68(Suppl. 2): ii1–ii44.
16. Jaeschke R, Guyatt GH and Sackett DL; For the Evidence-Based Medicine Working Group. Users' guides to the medical literature. III. How to use an article about a diagnostic test. *JAMA* 1994; 271: 703–707.
17. Landis JR and Koch CG. The measurement of observer agreement for categorical data. *Biometrics* 1997; 33: 159–174.
18. de Hooge M, van den Berg R, Navarro-Compán V, *et al.* Patients with chronic back pain of short duration from the SPACE cohort: which MRI structural lesions in the sacroiliac joints and inflammatory and structural lesions in the spine are most specific for axial spondyloarthritis? *Ann Rheum Dis* 2016; 75: 1308–1314.
19. Ez-Zaitouni Z, Bakker P, van Luntern M, *et al.* The yield of a positive MRI of the spine as imaging criterion in the ASAS classification criteria for axial spondyloarthritis: results from the SPACE and DESIR cohorts. *Ann Rheum Dis* 2017; 76: 1731–1736.
20. Molto A, Gossec L, Lefevre-Colau MM, *et al.* Evaluation of the performances of 'typical' imaging abnormalities of axial spondyloarthritis: results of the cross-sectional ILOS-DESIR study. *RMD Open* 2019; 5: e000918.
21. Ho-Pham LT, Lai TQ, Mai LD, *et al.* Prevalence and pattern of radiographic intervertebral disc degeneration in Vietnamese: a population-based study. *Calcif Tissue Int* 2015; 96: 510–517.
22. Baraliakos X, Landewe R, Hermann KG, *et al.* Inflammation in ankylosing spondylitis: a systemic description of the extent and frequency of acute spinal changes using magnetic resonance imaging. *Ann Rheum Dis* 2005; 64: 730–734.
23. Bennett AN, Rehman A, Hensor EMA, *et al.* Evaluation of the diagnostic utility of spinal magnetic resonance imaging in axial spondyloarthritis. *Arthritis Rheum* 2009; 60: 1331–1341.

24. Maksymowych WP. Progress in spondyloarthritis. Spondyloarthritis: lessons from imaging. *Arthritis Res Ther* 2009; 11: 222.
25. Weber U and Maksymowych WP. Advances and challenges in spondyloarthritis imaging for diagnosis and assessment of disease. *Curr Rheumatol Rep* 2013; 15: 345.
26. Chung HY, Yiu RSW, Chan SCW, *et al.* Fatty corner lesions in T1-weighted magnetic resonance imaging as an alternative to sacroiliitis for diagnosis of axial spondyloarthritis. *BMC Rheumatol* 2019; 3: 17.
27. Molto A, Patemotte S, van der Heijde D, *et al.* Evaluation of the validity of the different arms of the ASAS set of criteria for axial spondyloarthritis and description of the different imaging abnormalities suggestive of spondyloarthritis: data from the DESIR cohort. *Ann Rheum Dis* 2015; 74: 746–751.
28. Seprinao A, Rubio R, Ramiro S, *et al.* Performance of the ASAS classification criteria for axial and peripheral spondyloarthritis: a systematic literature review and meta-analysis. *Ann Rheum Dis* 2017; 76: 886–890.
29. Van den Berg R, Lenczner G, Feydy A, *et al.* Agreement between clinical practice and trained central reading in reading of sacroiliac joints on plain pelvic radiographs. Results from the DESIR cohort. *Arthritis Rheumatol* 2014; 66: 2403–2411.
30. Baraliokos X, Richter A, Feldmann D, *et al.* Frequency of MRI changes suggestive of axial spondyloarthritis in the axial skeleton in a large population-based cohort of individuals aged <45 years. *Ann Rheum Dis* 2020; 79: 186–192.

Visit SAGE journals online  
[journals.sagepub.com/  
home/tab](https://journals.sagepub.com/home/tab)

 SAGE journals