

# Differential myocardial fibrosis of the systemic right ventricle and subpulmonary left ventricle after atrial switch operation for complete transposition of the great arteries <sup>☆</sup>

Yiu-fai Cheung <sup>a,\*</sup>, Wendy W.M. Lam <sup>b</sup>, Edwina K.F. So <sup>a</sup>, Pak-cheong Chow <sup>a</sup>

<sup>a</sup> Department of Paediatrics and Adolescent Medicine, Queen Mary Hospital, The University of Hong Kong, Hong Kong, China

<sup>b</sup> Department of Radiology, Queen Mary, Hospital, Hong Kong, China



## ARTICLE INFO

### Article history:

Received 9 July 2020

Received in revised form 27 July 2020

Accepted 29 July 2020

Available online 11 August 2020

### Keywords:

Transposition of the great arteries

Atrial switch operation

Myocardial fibrosis

Cardiovascular magnetic resonance

## ABSTRACT

**Background:** This study aimed to assess diffuse myocardial fibrosis of the systemic right ventricle and subpulmonary left ventricle in patients after Senning or Mustard operation for complete transposition of the great artery (TGA) using cardiac magnetic resonance (CMR) T1 mapping.

**Methods:** Thirty-one adult TGA patients after Senning (n = 24) or Mustard (n = 7) operation were studied at the age of 33.3 ± 4.0 years. Systemic right ventricular (RV) and subpulmonary left ventricular (LV) volumes, ejection fraction, and myocardial T1 values and extracellular volume fraction (ECV) were determined using CMR.

**Results:** The RV and LV ejection fractions were 47.0 ± 10.9% and 61.3 ± 7.4%, respectively. Compared to published normative values, patients had significantly greater RV and LV native T1 and ECV values (all p < 0.001). For each of the basal, mid, and apical segments, the LV native T1 and ECV values were significantly greater in the left than the right ventricle (all p < 0.05). There is a significant trend on progressive increase in ECV value from the basal towards the apical segments in both the right (p = 0.002) and the left (p < 0.001) ventricle. Modestly strong correlations were found between RV and LV native T1 (r = 0.60, p < 0.001) and ECV (r = 0.49, p = 0.005) values but not with ejection fractions of the respective ventricles. **Conclusions:** Differential myocardial fibrosis, with greater involvement of the subpulmonary left ventricle than the systemic right ventricle, is present in patients with TGA after atrial switch operation. Associations between the magnitude of RV and LV fibrosis suggests adverse ventricular-ventricular interaction at the cardiac extracellular matrix level.

© 2020 The Authors. Published by Elsevier B.V. This is an open access article under the CC BY-NC-ND license (<http://creativecommons.org/licenses/by-nc-nd/4.0/>).

## 1. Introduction

The prevalence of repaired congenital heart disease in adults is increasing as survival into adulthood exceeds 85% after cardiac surgery in the present era [1]. Heart failure has emerged as one of the most important issues in patients with repaired complex congenital heart lesions [2,3]. In particular, dysfunction of the systemic right ventricle in adults after atrial switch operation for complete transposition of the great arteries (TGA) has been a focus of attention [4,5]. Based on the CONCOR Dutch national registry database, adult patients with surgically corrected TGA had a hazard ratio of

5.0 of being admitted for heart failure compared with patients with ventricular septal defect [6]. While anatomic, haemodynamic and surgical factors may contribute to cardiac dysfunction in patients after atrial switch operation, there is increasing evidence to suggest that myocardial fibrosis may play an important pathogenetic role in the development of heart failure in a spectrum of cardiovascular conditions [7,8].

In patients with complete TGA after atrial switch operation, previous cardiac magnetic resonance (CMR) late gadolinium enhancement (LGE) studies have identified areas of focal myocardial fibrosis [9–11]. Nonetheless, apparently healthy looking myocardium without regional scarring may still harbour increased amount of diffuse fibrosis, which may be detected by CMR T1 mapping [12]. Increasingly, CMR T1 mapping has found applications in the assessment of diffuse fibrotic remodeling in children and adults with congenital heart disease [13–15]. The degree of myocardial matrix alteration may be estimated by quantifying native T1 and

<sup>☆</sup> All authors takes responsibility for all aspects of the reliability and freedom from bias of the data presented and their discussed interpretation.

\* Corresponding author at: Division of Paediatric Cardiology Department of Paediatrics and Adolescent Medicine Queen Mary Hospital, The University of Hong Kong, 102, Pokfulam Road, Hong Kong, China.

E-mail address: [xfcheung@hku.hk](mailto:xfcheung@hku.hk) (Y.-f. Cheung).

extracellular volume fraction (ECV). Native T1 reflects the non-contrast enhanced T1 time, while ECV measures the size of extracellular space after administration of gadolinium-based contrast agents [16]. Data on the use of CMR T1 mapping for assessment of systemic right ventricular (RV) and subpulmonary left ventricular (LV) fibrosis in adults after atrial switch operation are limited [13,15,17].

In this study, we assessed myocardial fibrosis of the systemic right ventricle and subpulmonary left ventricle in patients after atrial switch operation for complete TGA by CMR T1 mapping and interrogated its relationships with ventricular function.

## 2. Methods

### 2.1. Study population

Thirty-one adult patients with complete TGA who had undergone Mustard or Senning procedure were recruited from the adult congenital heart clinic. The following data were obtained from the case notes: demographic variables, age at and type of operation, duration of follow-up since surgery, and current cardiac medications. The body weight and height were measured and the body mass index and body surface area calculated accordingly. The study was carried out in accordance with the Declaration of Helsinki. All adult subjects and parents of minors gave written informed consent to participate in this study approved by the Institutional Review Board.

### 2.2. Cardiovascular magnetic resonance imaging

Cardiovascular magnetic resonance (CMR) was performed using Siemens Magnetom Aera 1.5 T MRI system (Siemens AG, Healthcare Sector, Germany) with 18-channel torso body array coil. Analysis of LV and RV volumes and ejection fraction was obtained by balanced steady state free precession (SSFP) cine images with retrospective ECG gating gated retrospectively and acquired at end-expiration on axial and short axis planes.

Myocardial T1 mapping was performed in the matched mid-ventricular, basal and apical short axis slices. The T1 mapping sequence is a balanced SSFP, single breath hold modified inversion recovery Look-Locker sequence (MOLLI) with a 5(3)3 image acquisition algorithm, with data acquisition period of 5 heart beats followed by recovery period of 3 heart beats and then another data acquisition period of 3 heart beats. A total of 8 images was acquired with different Inversion time (TI) via 11 heart beats. This was done twice, once before contrast is administered and the second acquisition at 10 min after a bolus injection of 0.2 mmol/kg gadolinium-based contrast medium (Dotarem). Left ventricular and RV functional analysis and T1 mapping quantification were performed using commercially available software (Cardiac Analysis Workflow, Syngo.via workstation, Siemens AG, Healthcare Sector, Germany). T1 analysis was performed by tracing semi-automatically the epicardial and endocardial contours of the region of interest.

Myocardial T1 values were measured in the septal myocardium and the other 5 equiangular segments from the mid-left ventricular short axis slice. Myocardial T1 values were also measured within the RV free wall. A region of interest drawn in the LV cavity was used to measure the blood T1 value. The extracellular volume fraction (ECV) was estimated by the formula:  $[1/T1_{myocardium\ post} - 1/T1_{myocardium\ pre}] / [1/T1_{(blood\ post)} - 1/T1_{(blood\ pre)}] * (1 - haematocrit)$  [18]. The haematocrit on the day of CMR was determined. The septal myocardium and the other 5 equiangular segments were averaged for calculation of LV T1 and ECV values,

while the RV free wall T1 and ECV values were also calculated (Fig. 1).

### 2.3. Statistical analysis

Data are reported as mean  $\pm$  SD unless otherwise stated. Ventricular volumes were indexed by body surface area. The average of CMR native T1 and ECV values in patients were compared with those reported in the literature for healthy controls [19–27]. Relationship between parameters of RV and LV myocardial fibrosis and ventricular ejection fraction were determined using Pearson correlation analysis. Inter- and intra-observer reproducibility for the measurements of ECV values, based on T1 measurements, was performed and reported as coefficients of variation. A p value  $<$  0.05 is considered statistically significant. All statistical analyses were performed using IBM SPSS Statistics 25 (SPSS, Chicago, Illinois).

## 3. Results

### 3.1. Patients characteristics

Thirty-one (22 males) patients aged  $33.3 \pm 4.0$  years, 24 of whom had Senning operation and 7 had Mustard procedure, were studied. Six of the patients (5 Senning and 1 Mustard) had additional repair of an associated ventricular septal defect. The age at operation was  $1.4 \pm 1.2$  years. The patients were followed up for  $31.9 \pm 3.6$  years (range, 21.7 to 38.4 years). Of the 31 patients, 30 (97%) were in New York Heart Association functional class I, while 1 (3%) was in functional class II. Residual anatomic and/or haemodynamic problems included mild baffle problems including a small leak or mild narrowing in 5 patients, pulmonary outflow obstruction in 5 patients and moderate to severe tricuspid regurgitation as assessed semi-quantitatively by colour flow mapping in 1 patient. Current medications included beta-blockers (n = 8), angiotensin converting enzyme inhibitor or angiotensin receptor blocker (n = 6), digoxin (n = 4), diuretics (n = 1), calcium channel blocker (n = 1) and aspirin (n = 1).

### 3.2. Ventricular function and volumes

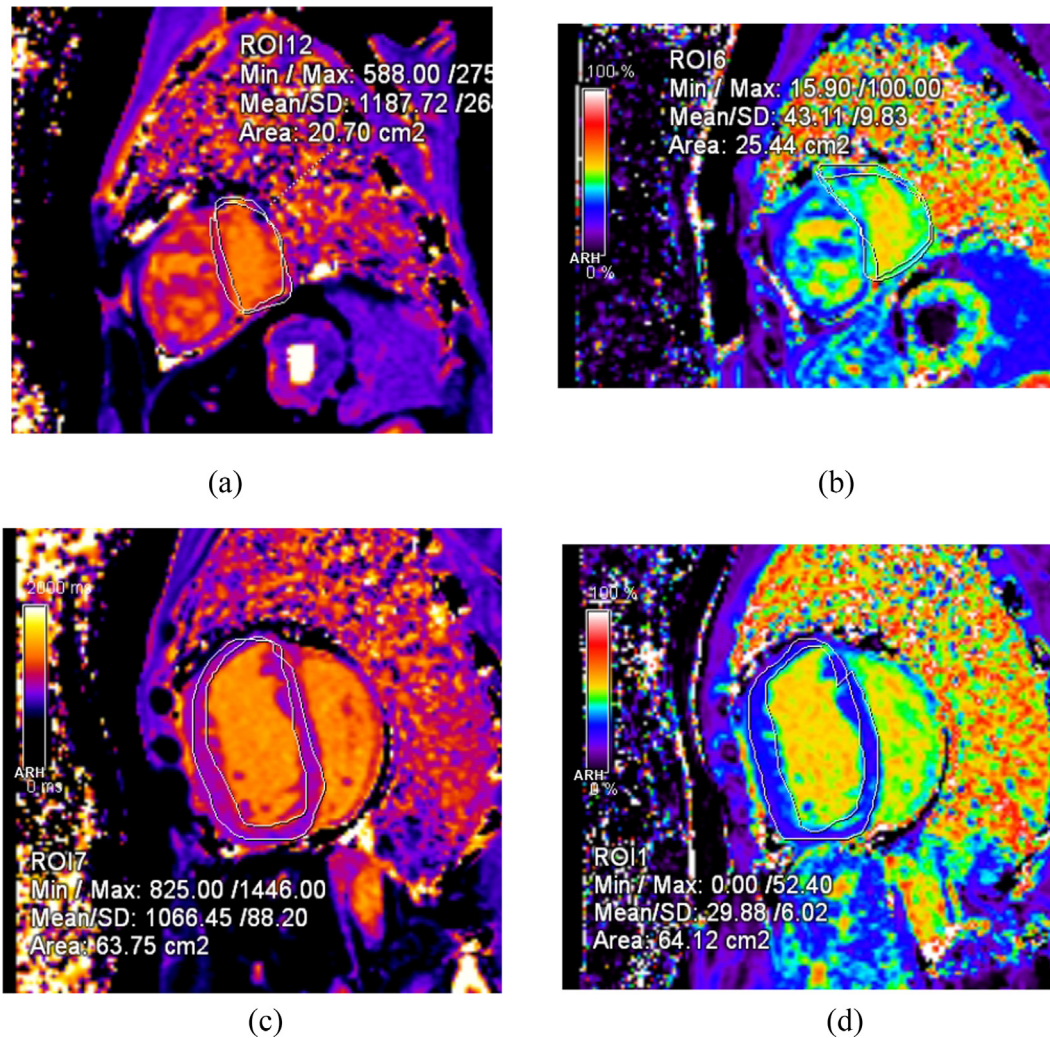
Systemic RV ejection fraction was  $47.0 \pm 10.9\%$ , with an indexed RV end-systolic volume of  $52.0 \pm 24.6$  ml/m<sup>2</sup> and end-diastolic volume of  $93.7 \pm 30.4$  ml/m<sup>2</sup>. The subpulmonary LV ejection fraction was  $61.3 \pm 7.4\%$ , with an indexed LV end-systolic volume of  $24.5 \pm 10.0$  ml/m<sup>2</sup> and end-diastolic volume of  $63.7 \pm 18.8$  ml/m<sup>2</sup>.

### 3.3. Late gadolinium enhancement

Overall, the patients showed either absent or minimal to mild degree of LGE of the right and left ventricles. With regard to the systemic right ventricle, LGE was found to absent in 15 patients, to involve only the insertion point in 6 patients, to involve only 1 segment other than insertion point in 5 patients, and to involve the insertion point with 1 additional segment in 5 patients. With regard to the subpulmonary left ventricle, LGE was found to be absent in 21 patients, to involve the insertion point in 3 patients, to involve the insertion point with 1 segment in 4 patients and to involve 1 or 2 segments other than the insertion points in 3 patients.

### 3.4. T1 Mapping parameters

Table 1 summarizes the segmental native T1 values of the right and left ventricles in patients. For each of the basal, mid, and apical segments, the LV native T1 values were significantly greater in the



**Fig. 1.** T1 maps of the basal region of the (a) left ventricle and (b) right ventricle and extracellular volume fraction maps of the basal region of the (c) left ventricle and (d) right ventricle.

**Table 1**  
Native T1 and ECV values of the right and left ventricles.

	Right ventricle	Left ventricle	p
<i>Native T1 value (ms)</i>			
Basal	1066.4 ± 36.0	1153.8 ± 152.9	0.004*
Mid	1093.6 ± 63.7	1143.9 ± 120.7	0.046*
Apical	1101.7 ± 84.5	1184.6 ± 96.3	0.001*
<i>ECV (%)</i>			
Basal	30.9 ± 4.0	34.2 ± 5.4	0.007*
Mid	31.7 ± 3.7	36.7 ± 6.6	0.001*
Apical	34.2 ± 4.6	39.2 ± 5.3	<0.001*

ECV, extracellular volume.

\*statistically significant.

left than the right ventricle (all  $p < 0.05$ ) (Fig. 2). The average native T1 value of subpulmonary LV basal, mid and apical segments was significantly greater than that of systemic RV segments ( $1087 \pm 49$  ms vs  $1161 \pm 77$  ms,  $p < 0.001$ ).

The average ECV value of subpulmonary LV basal, mid and apical segments was also significantly greater than that of systemic RV segments ( $32.2 \pm 2.8\%$  vs  $36.7 \pm 4.7\%$ ,  $p < 0.001$ ). For each of the basal, mid, and apical segments, the LV ECV values were also greater in the left than the right ventricle (all  $p < 0.01$ ) (Table 1). There is a significant trend on progressive increase in ECV value from the basal towards the apical segment in both the right

( $p = 0.002$ ) and the left ( $p < 0.001$ ) ventricle (Fig. 3). The intra- and interobserver variabilities of measurements of RV ECV were respectively 4.85% and 6.82%, while those of LV ECV were respectively 3.75% and 9.40%.

Comparison of the 6 patients with concomitant closure of ventricular septal defect versus 24 patients without revealed the absence of significant differences between both RV and LV native T1 and ECV values (all  $p > 0.05$ ).

### 3.5. Comparison with normative values

Table 2 summarizes the previously reported native T1 and ECV values in healthy volunteers [19–27]. Compared with these normative values, our patients had significantly greater RV and LV native T1 and ECV values (all  $p < 0.001$ ). Data in the literature also reveal the absence of significant difference between RV and LV ECV values in healthy subjects [19]. On the other hand, we found that a difference of  $4.5 \pm 4.1\%$  between subpulmonary LV ECV and systemic RV ECV in our patients ( $p < 0.001$  when compared with 0%).

### 3.6. Correlates of T1 mapping parameters

Table 3 shows the correlations between CMR indices of fibrosis and age and indices of ventricular size and function. There were no

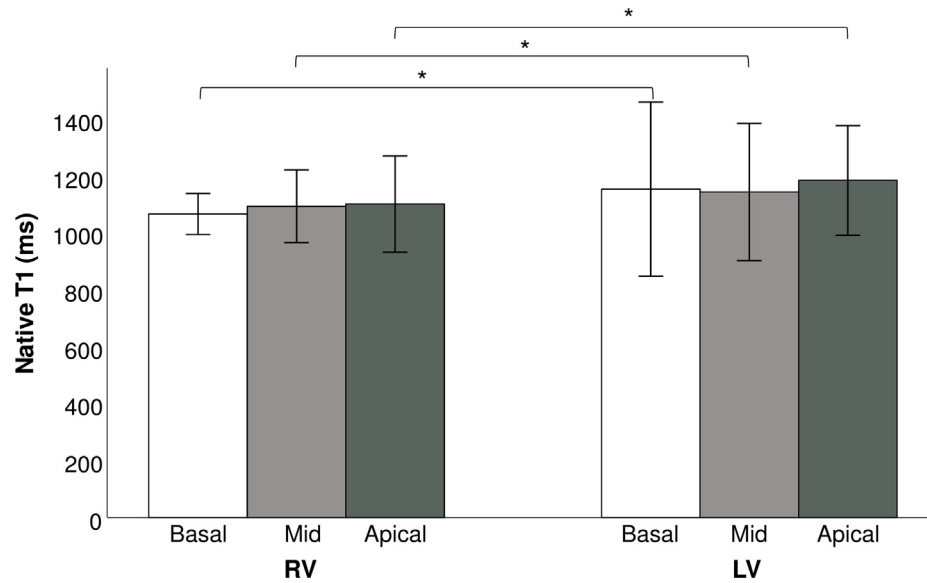


Fig. 2. Segmental native T1 values of the right and left ventricles. RV, right ventricle, LV, left ventricle. (\*p < 0.05).

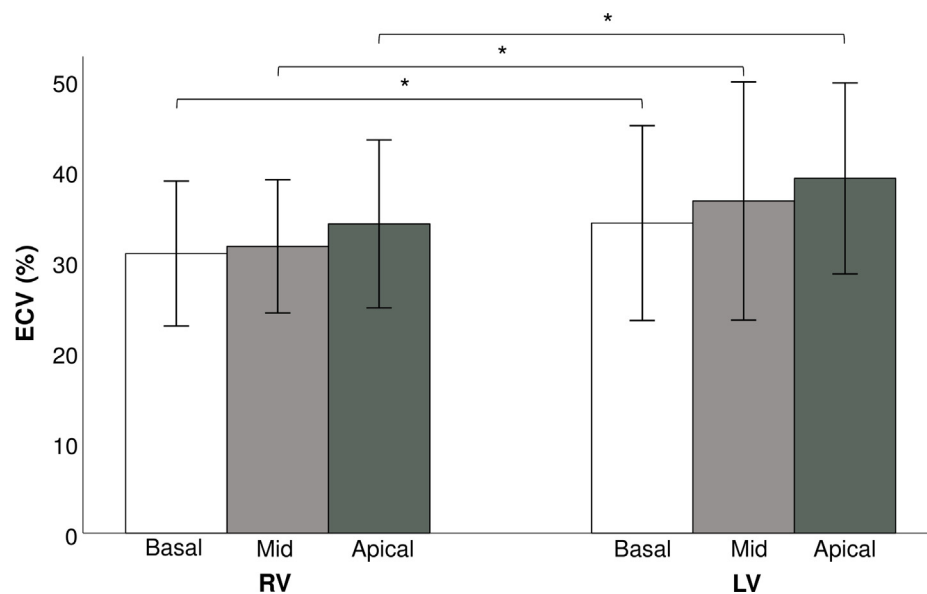


Fig. 3. Segmental extracellular volume fraction of the right and left ventricles. ECV, extracellular volume fraction, RV, right ventricle, LV, left ventricle. (\*p < 0.05).

Table 2

Comparisons between published normative native T1 time and extracellular volume values and our study results.

	Publication	n	Age (years)	Sequence	Native T1 (ms)	p	ECV (%)	p
RV	Mehta (2015) [19]	10	24.4 (21.7–26.3)	ANGIE	974 (927–996) <sup>##</sup>	<0.001*	27.0 (25.1–28.1) <sup>##</sup>	<0.001*
LV	Iles (2008) [20]	20	38 ± 3	GE, VAST 3–4 BH	975 ± 62	<0.001*	n/a	–
	Fontana (2012) [21]	50	47 ± 7	ShMOLLI <sup>#</sup>	Not reported	–	26 ± 3	<0.001*
	Sado (2012) [22]	81	44 ± 17	FLASH, multi-BH	Not reported	–	25 ± 4	<0.001*
	Piechnik (2013) [23]	342	38 ± 15	ShMOLLI <sup>#</sup>	962 ± 25	<0.001*	n/a	–
	Mehta (2015) [19]	10	24.4 (21.7–26.3)	ANGIE	971 (948–986) <sup>##</sup>	<0.001*	27.1 (25.1–27.9) <sup>##</sup>	<0.001*
	Goebel (2016) [24]	54	48 ± 11	MOLLI <sup>†</sup>	955 ± 34	<0.001*	n/a	–
	Bulluck (2017) [25]	101	46 ± 13	MOLLI <sup>†</sup>	1013 ± 27	<0.001*	n/a	–
	Nickander (2017) [26]	77	49 ± 14	MOLLI <sup>†</sup>	1027 ± 38	<0.001*	n/a	–
	Rosmini (2018) [27]	94	50 ± 14	MOLLI <sup>†</sup>	1024 ± 39	<0.001*	27 ± 3	<0.001*

Abbreviations: ECV, extracellular volume; LV, left ventricle; RV, right ventricle.

<sup>#</sup> Adiabatic pre pulse, <sup>##</sup> median, \*statistically significant (vs present study).

<sup>†</sup> CMR sequence for native T1 and magnetic field strength similar to those of the present study.

**Table 3**  
Correlates of native T1 and ECV values.

	Right ventricle Native T1		ECV	
	r	p	r	p
Age	-0.18	0.34	0.03	0.86
RVEF	-0.07	0.72	0.04	0.83
Indexed RV ESV	0.10	0.58	0.06	0.74
Indexed RV EDV	0.08	0.67	0.12	0.52
LV native T1	0.60	<0.001*	-	-
LV ECV	-	-	0.49	0.005*
	Left ventricle Native T1		ECV	
	r	p	r	p
Age	0.02	0.91	-0.10	0.59
LVEF	-0.03	0.87	0.05	0.80
Indexed LV ESV	-0.14	0.44	-0.24	0.19
Indexed LV EDV	-0.19	0.31	-0.25	0.18

Abbreviations: ECV, extracellular volume; EDV, end-diastolic volume; EF, ejection fraction; ESV, end-systolic volume; LV, left ventricular; RV, right ventricular.

\*Statistically significant.

significant correlations between RV native T1 and ECV values with age, RV ejection fraction, and RV end-systolic and -diastolic volumes. Similarly, there were no significant correlations between LV native T1 and ECV values with age, LV ejection fraction, and LV end-systolic and -diastolic volumes. On the other hand, modestly strong correlations were found between RV and LV native T1 ( $r = 0.60$ ,  $p < 0.001$ ) and ECV ( $r = 0.49$ ,  $p = 0.005$ ) values (Fig. 4).

#### 4. Discussion

The important observations of the present CMR T1 mapping study conducted in the largest cohort of adult TGA patients after atrial switch operation reported to date include 1) evidence of myocardial fibrosis, as reflected by the greater native T1 and ECV values, involving both the systemic right ventricle and subpulmonary left ventricle, 2) greater segmental and average ECV of the left ventricle compared with that of the right ventricle, 3) regional differences of myocardial fibrosis with an increasing trend of ECV from base to apex of both ventricles, and 4) significant positive correlations between RV and LV native T1 and ECV values.

Earlier CMR studies have explored focal myocardial fibrosis in Senning and Mustard patients through evaluation of LGE [9–11,28]. These studies have focussed and reported on increased LGE of the systemic right ventricle, with prevalence varying from 35% to 61% reported. While the pattern of LGE appears variable, previous investigators have found correlations between RV focal fibrosis and systemic ventricular dysfunction, impaired exercise tolerance, cardiac arrhythmias, and other adverse cardiovascular outcomes [9–11,28]. Nonetheless, complete absence of LGE has also been reported without [17] or even with [15] inclusion in the assessment of the insertion of the right ventricle with the inter-ventricular septum. We also found that LGE is either absent or very mild in our patient cohort. While the cause for these discrepant findings is unclear, the inability of CMR LGE to evaluate diffuse ventricular fibrosis is well recognized.

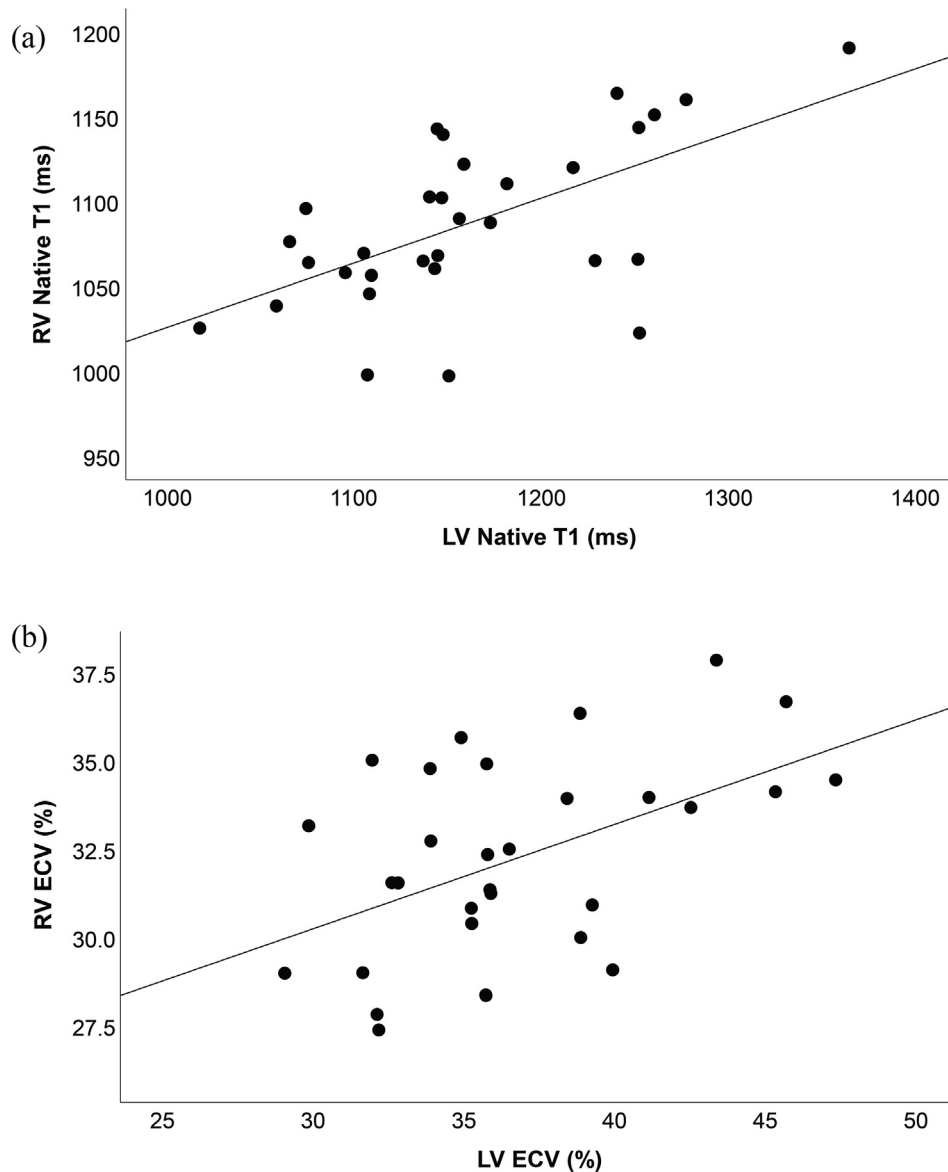
Data on the use of T1 mapping to evaluate diffuse ventricular fibrosis in patients after atrial switch operation are limited. Broberg et al studied 50 adult congenital heart patients and found that the CMR T1 mapping-derived fibrosis index was the highest in the 11 patients with a systemic right ventricle [13]. Furthermore, they found a negative correlation between ventricular fibrosis index and systemic ventricular ejection fraction for the entire study cohort. Plymen et al studied 14 adults after Mustard or Senning operation and showed that septal ECV was significantly higher than that of controls, and correlated positively with N-terminal pro-brain natriuretic peptide levels and negatively with exercise chronotropic

index [15]. However, they found difficulties of measuring RV free ECV related to heavy trabeculation, sternal wires, and blood pool in regions of interest.

It is worthwhile noting that the aforementioned studies did not evaluate the subpulmonary ventricle and studies conducted hitherto have not explored associations between systemic RV and subpulmonary LV fibrosis. Nonetheless, the recent article by Tretter and Redington has highlighted how the left ventricle can be a culprit and therapeutic target for morbidity and mortality in right-sided congenital heart disease [29]. Indeed, our group has previous demonstrated adverse diastolic RV-LV interactions in adults after atrial switch operation [30]. In the present study, we assessed further the magnitude of diffuse fibrosis of both ventricles. Our finding of increased RV native T1 and ECV values compared with published normal reference data is in agreement with the conclusion of previous studies of diffuse fibrotic remodeling of the systemic right ventricle [13] or septum [15] in patients after Senning or Mustard operation. Additionally, the present study provides novel data on subpulmonary left ventricular fibrosis in terms of severity, association with systemic RV fibrosis, and regional heterogeneity.

The finding of worse fibrotic remodeling of the subpulmonary left ventricle compared with the systemic right ventricle is intriguing. Our finding, based on a relatively large patient cohort, agrees with that reported recently by Shehu et al who similarly found greater LV than RV ECV in 10 patients studied [17]. While the cause of worse subpulmonary LV fibrotic remodeling in our patients is not immediately obvious, chronic volume unloading of the eccentrically compressed left ventricle related to septal shift and impaired LV diastolic function as shown previously by our group [30] may be contributive. Furthermore, the potential role of the recently described highly prevalent postcapillary pulmonary hypertension on subpulmonary LV adaptation and fibrosis in these patients warrants further evaluation [31].

Our finding of an association between LV and RV native T1 and ECV values suggests ventricular-ventricular interaction at the extracellular matrix level. Indeed, in patients with repaired tetralogy of Fallot, Yim et al found a similar positive association between the systemic left ventricle and subpulmonary right ventricle [14]. Additionally, we documented regional heterogeneity with progressively worsening of fibrotic remodeling towards the apical segments of both ventricles. The cause of this observation is unclear. However, in patients with repaired tetralogy of Fallot, more pronounced reduction subpulmonary RV myocardial deformation is found at the apex [32]. The latter has been proposed to be related to the greater susceptibility of the thinner and more trabeculated



**Fig. 4.** Scatter plots showing correlations between right and left ventricular (a) native T1 values and (b) extracellular volume fraction. ECV, extracellular volumes fraction, RV, right ventricular, LV, left ventricular.

RV apical segment to increased wall stress [32]. Fibrotic remodeling of the dilated RV apex in our patients may perhaps be similarly accentuated, and adverse ventricular-ventricular interaction may result in concomitant LV apical remodeling.

Our findings have important clinical implications. Focal myocardial fibrosis has been associated with ventricular dysfunction, cardiac arrhythmias, and adverse cardiovascular events in patients after atrial switch operation [9–11]. It is tempting to hypothesize that T1 parameters that reflect diffuse ventricular fibrosis may have similar if not having a greater prognostic value, although further studies are required to substantiate this speculation. Furthermore, the finding of increased ECV involving both ventricles may represent a target for therapies that target at the fibrotic process. The recently published follow up of multicenter randomized controlled trial of valsartan in patients with a systemic right ventricle has reported on decreased morbidity in symptomatic patients [33]. Although the exact mechanism is unclear, valsartan has been shown to improve fibrosis in spontaneously hypertensive rats [34]. Studies on changes in T1 mapping parameters in relation to functional outcomes with institution of anti-

fibrotic therapies may shed further mechanistic lights. Systematic review and meta-analysis have failed to provide conclusive evidence of beneficial effects angiotensin enzyme inhibitor and angiotensin receptor blocker on systemic RV dysfunction [35]. Nonetheless, given the potential beneficial effects of angiotensin converting enzyme inhibitor and angiotensin receptor blocker on cardiac remodeling and cardiac fibrosis [36,37], it would be worthwhile to conduct CMR T1 mapping studies in a larger patient population to explore the effect of these medications on the myocardial fibrosis. The present study is, however, underpowered to do so.

Patient factors may influence the severity of ventricular fibrosis. Given the small number of Mustard patients in the present study, we did not perform patient subgroup analyses. Long term studies did not reveal differences in long-term survival between Senning and Mustard patients [38,39]. Nonetheless, Moons et al showed a slightly higher prevalence of moderate to severe dysfunction of the systemic ventricles in their Mustard (15%) than Senning (10%) patient cohort, albeit statistically insignificant [40]. Further studies to compare the magnitude of ventricular fibrosis between

the two patient cohorts are warranted. Although we found similar native T1 and ECV values in patients with and without concomitant closure of ventricular septal defect, the small number of patients with defect closure may limit the statistical power to detect potential differences.

Several limitations to this study require comments. First, we have compared native T1 and ECV values of our patients against published normal values. While differences in reference values among institutions may be present, we have compared our data to values reported by different groups, including reference values derived using similar magnetic field strength and mapping sequence (Table 2). Notwithstanding, it remains optimal to compare the findings in patients with study site-specific normal values derived from healthy volunteers [41]. Second, given that our patients have small range of systemic RV ejection fraction, the present study lacked the power to demonstrate any relationships between native T1 and ECV values and systemic RV ejection. Further studies to assess the relationship between diffuse ventricular fibrosis and diastolic function and myocardial stiffness of the two ventricles are also warranted. Third, it would have been ideal to study in a prospective longitudinal manner on the relationships between CMR T1 mapping findings and progression of functional class, risk of developing cardiac arrhythmias, exercise testing parameters, and circulating cardiac biomarkers such as brain natriuretic peptide. As this is a cross-sectional study, relationships between the CMR parameters of diffuse ventricle fibrosis and clinical outcomes cannot be ascertained. Finally, as alluded to earlier, this study is underpowered to study the effects of drugs that target at the renin-angiotensin system on myocardial fibrosis, a topic that deserves further investigations.

## 5. Conclusions

Differential myocardial fibrosis, with greater involvement of the subpulmonary left ventricle than the systemic right ventricle, is present in patients with complete TGA after atrial switch operation. Associations between the magnitude of RV and LV fibrosis suggests adverse ventricular-ventricular interaction at the cardiac extracellular matrix level. Further studies to explore the role of imaging for diffuse ventricular fibrosis in risk stratification and prediction of clinical outcomes in this patient population is warranted.

## CRedit authorship contribution statement

**Yiu-fai Cheung:** Supervision, Conceptualization, Methodology, Writing - original draft, Writing - review & editing. **Wendy W.M. Lam:** Supervision, Software, Investigation, Data curation. **Edwina K.F. So:** Investigation, Formal analysis, Project administration. **Pak-cheong Chow:** Conceptualization, Resources.

## Declaration of Competing Interest

The authors declared that there is no conflict of interest.

## Acknowledgement of grant support

This research did not receive any specific grant from funding agencies in the public, commercial, or not-for-profit sectors.

## References

- [1] A.B. Bhatt, E. Foster, K. Kuehl, et al., Congenital heart disease in the older adult: a scientific statement from the American Heart Association, *Circulation* 131 (21) (2015) 1884–1931, <https://doi.org/10.1161/CIR.000000000000204>.
- [2] J.N. Menachem, K.H. Schlendorf, J.A. Mazurek, et al., Advanced heart failure in adults with congenital heart disease, *JACC Heart Fail.* 8 (2) (2020) 87–99, <https://doi.org/10.1016/j.jchf.2019.08.012>.
- [3] K.K. Stout, C.S. Broberg, W.M. Book, et al., Chronic heart failure in congenital heart disease: a scientific statement from the American heart association, *Circulation* 133 (8) (2016) 770–801, <https://doi.org/10.1161/CIR.000000000000352>.
- [4] B. Lubiszewska, E. Gosiewska, P. Hoffman, et al., Myocardial perfusion and function of the systemic right ventricle in patients after atrial switch procedure for complete transposition: long-term follow-up, *J. Am. Coll. Cardiol.* 36 (4) (2000) 1365–1370, [https://doi.org/10.1016/s0735-1097\(00\)00864-0](https://doi.org/10.1016/s0735-1097(00)00864-0).
- [5] J.W. Roos-Hesselink, F.J. Meijboom, S.E. Spitaels, et al., Decline in ventricular function and clinical condition after Mustard repair for transposition of the great arteries (a prospective study of 22–29 years), *Eur. Heart J.* 25 (14) (2004) 1264–1270, <https://doi.org/10.1016/j.ehj.2004.03.009>.
- [6] A.C. Zomer, I. Vaartjes, E.T. van der Velde, et al., Heart failure admissions in adults with congenital heart disease; risk factors and prognosis, *Int. J. Cardiol.* 168 (3) (2013) 2487–2493, <https://doi.org/10.1016/j.ijcard.2013.03.003>.
- [7] A. González, E.B. Schelbert, J. Diez, J. Butler, Myocardial interstitial fibrosis in heart failure: biological and translational perspectives, *J. Am. Coll. Cardiol.* 71 (15) (2018) 1696–1706, <https://doi.org/10.1016/j.jacc.2018.02.021>.
- [8] R.A. de Boer, G. De Keulenaer, J. Bauersachs, D. Brutsaert, J.G. Cleland, J. Diez, X.-J. Du, P. Ford, F.R. Heinzel, K.E. Lipson, T. McDonagh, N. Lopez-Andres, I.G. Lunde, A.R. Lyon, P. Pollesello, S.K. Prasad, C.G. Tocchetti, M. Mayr, J.P.G. Sluijter, T. Thum, C. Tschöpe, F. Zannad, W.-H. Zimmermann, F. Ruschitzka, G. Filippatos, M.L. Lindsey, C. Maack, S. Heymans, Towards better definition, quantification and treatment of fibrosis in heart failure. A scientific roadmap by the committee of translational research of the heart failure association (HFA) of the European society of cardiology, *Eur. J. Heart Fail* 21 (3) (2019) 272–285, <https://doi.org/10.1002/ehfj.2019.21.issue-310.1002/ehfj.1406>.
- [9] S.V. Babu-Narayan, O. Goktekin, J.C. Moon, et al., Late gadolinium enhancement cardiovascular magnetic resonance of the systemic right ventricle in adults with previous atrial redirection surgery for transposition of the great arteries, *Circulation* 111 (16) (2005) 2091–2098, <https://doi.org/10.1161/01.CIR.0000162463.61626.3B>.
- [10] A. Giardini, L. Lovato, A. Dotti, et al., Relation between right ventricular structural alterations and markers of adverse clinical outcome in adults with systemic right ventricle and either congenital complete (after Senning operation) or congenitally corrected transposition of the great arteries, *Am. J. Cardiol.* 98 (9) (2006) 1277–1282, <https://doi.org/10.1016/j.amjcard.2006.05.062>.
- [11] R. Rydman, M.A. Gatzoulis, S.Y. Ho, et al., Systemic right ventricular fibrosis detected by cardiovascular magnetic resonance is associated with clinical outcome, mainly new-onset atrial arrhythmia, in patients after atrial redirection surgery for transposition of the great arteries, *Circ. Cardiovasc. Imaging.* 8 (5) (2015), <https://doi.org/10.1161/CIRCIMAGING.114.002628.e002628>.
- [12] P. Haaf, P. Garg, D.R. Messroghli, D.A. Broadbent, J.P. Greenwood, S. Plein, Cardiac T1 mapping and extracellular volume (ECV) in clinical practice: a comprehensive review, *J. Cardiovasc. Magn. Reson.* 18 (1) (2016) 89, <https://doi.org/10.1186/s12968-016-0308-4>.
- [13] C.S. Broberg, S.S. Chugh, C. Conklin, D.J. Sahn, M. Jerosch-Herold, Quantification of diffuse myocardial fibrosis and its association with myocardial dysfunction in congenital heart disease, *Circ. Cardiovasc. Imaging* 3 (6) (2010) 727–734, <https://doi.org/10.1161/CIRCIMAGING.108.842096>.
- [14] D. Yim, E. Riesenkampff, P. Caro-Dominguez, S.-J. Yoo, M. Seed, L. Grosse-Wortmann, Assessment of diffuse ventricular myocardial fibrosis using native T1 in children with repaired tetralogy of fallot, *Circ. Cardiovasc. Imaging* 10 (3) (2017), <https://doi.org/10.1161/CIRCIMAGING.116.005695>.
- [15] C.M. Plymen, D.M. Sado, A.M. Taylor, et al., Diffuse myocardial fibrosis in the systemic right ventricle of patients late after Mustard or Senning surgery: an equilibrium contrast cardiovascular magnetic resonance study, *Eur Heart J Cardiovasc Imaging.* 14 (10) (2013) 963–968, <https://doi.org/10.1093/ehjci/jet014>.
- [16] J.C. Moon, D.R. Messroghli, P. Kellman, et al., Myocardial T1 mapping and extracellular volume quantification: a society for cardiovascular magnetic resonance (SCMR) and CMR working group of the European society of cardiology consensus statement, *J. Cardiovasc. Magn. Reson.* 15 (2013) 92, <https://doi.org/10.1186/1532-429X-15-92>.
- [17] N. Shehu, C. Meierhofer, D. Messroghli, et al., Diffuse fibrosis is common in the left, but not in the right ventricle in patients with transposition of the great arteries late after atrial switch operation, *Int. J. Cardiovasc. Imaging.* 34 (8) (2018) 1241–1248, <https://doi.org/10.1007/s10554-018-1338-9>.
- [18] A.S. Flett, M.P. Hayward, M.T. Ashworth, et al., Equilibrium contrast cardiovascular magnetic resonance for the measurement of diffuse myocardial fibrosis: preliminary validation in humans, *Circulation* 122 (2) (2010) 138–144, <https://doi.org/10.1161/CIRCULATIONAHA.109.930636>.
- [19] B.B. Mehta, D.A. Auger, J.A. Gonzalez, et al., Detection of elevated right ventricular extracellular volume in pulmonary hypertension using Accelerated and Navigator-Gated Look-Locker Imaging for Cardiac T1 Estimation (ANGIE) cardiovascular magnetic resonance, *J. Cardiovasc. Magn. Reson.* 17 (2015) 110, <https://doi.org/10.1186/s12968-015-0209-y>.
- [20] L. Iles, H. Pfluger, A. Phrommintikul, et al., Evaluation of diffuse myocardial fibrosis in heart failure with cardiac magnetic resonance contrast-enhanced T1 mapping, *J. Am. Coll. Cardiol.* 52 (19) (2008) 1574–1580, <https://doi.org/10.1016/j.jacc.2008.06.049>.

- [21] M. Fontana, S.K. White, S.M. Banyersad, D.M. Sado, V. Maestrini, A.S. Flett, S.K. Piechnik, S. Neubauer, N. Roberts, J.C. Moon, Comparison of T1 mapping techniques for ECV quantification. Histological validation and reproducibility of ShMOLLI versus multibreath-hold T1 quantification equilibrium contrast CMR, *J. Cardiovasc. Magn. Reson.* 14 (1) (2012) 88, <https://doi.org/10.1186/1532-429X-14-88>.
- [22] D.M. Sado, A.S. Flett, S.M. Banyersad, et al., Cardiovascular magnetic resonance measurement of myocardial extracellular volume in health and disease, *Heart* 98 (19) (2012) 1436–1441, <https://doi.org/10.1136/heartjnl-2012-302346>.
- [23] Piechnik SK, Ferreira VM, Lewandowski AJ, et al., Normal variation of magnetic resonance T1 relaxation times in the human population at 1.5 T using ShMOLLI, *J Cardiovasc Magn Reson.* 15 (2013 Jan) 13. [10.1186/1532-429X-15-13](https://doi.org/10.1186/1532-429X-15-13).
- [24] J. Goebel, I. Seifert, F. Nensa, et al., Can Native T1 mapping differentiate between healthy and diffuse diseased myocardium in clinical routine cardiac MR imaging?, *PLoS One.* 11 (5) (2016), <https://doi.org/10.1371/journal.pone.0155591> e0155591.
- [25] H. Bulluck, J.A. Bryant, J.Z. Tan, Y.Y. Go, T.-T. Le, R.S. Tan, T.K. Lim, H.C. Tang, N. Lath, A.S. Low, C.-L. Chin, S.A. Cook, D.J. Hausenloy, Gender differences in native myocardial T1 in a healthy chinese volunteer cohort, *Cardiovasc Imaging Asia* 1 (2) (2017) 110, <https://doi.org/10.22468/cvia.2016.00129>.
- [26] Nickander J, Lundin M, Abdula G, et al., Blood correction reduces variability and gender differences in native myocardial T1 values at 1.5 T cardiovascular magnetic resonance - a derivation/validation approach, *J Cardiovasc Magn Reson.* 19(1) (2017 Apr) 41. <https://doi.org/10.1186/s12968-017-0353-7>.
- [27] S. Rosmini, H. Bulluck, G. Captur, et al., Myocardial native T1 and extracellular volume with healthy ageing and gender, *Eur. Heart J. Cardiovasc. Imaging* 19 (6) (2018) 615–621, <https://doi.org/10.1093/ehjci/jev034>.
- [28] M. Ladouceur, S. Baron, V. Nivet-Antoine, et al., Role of myocardial collagen degradation and fibrosis in right ventricle dysfunction in transposition of the great arteries after atrial switch, *Int. J. Cardiol.* 258 (2018) 76–82, <https://doi.org/10.1016/j.ijcard.2018.01.100>.
- [29] J.T. Tretter, A.N. Redington, The forgotten ventricle? The left ventricle in right-sided congenital heart disease, *Circ. Cardiovasc. Imaging.* 11 (3) (2018), <https://doi.org/10.1161/CIRCIMAGING.117.007410> e007410.
- [30] P.C. Chow, X.C. Liang, Y.F. Cheung, Diastolic ventricular interaction in patients after atrial switch for transposition of the great arteries: a speckle tracking echocardiographic study, *Int. J. Cardiol.* 152 (1) (2011) 28–34, <https://doi.org/10.1016/j.ijcard.2010.05.078>.
- [31] M.-A. Chaix, A. Dore, L.-A. Mercier, F.-P. Mongeon, F. Marcotte, R. Ibrahim, A.W. Asgar, A. Shohoudi, F. Labombarda, B. Mondésert, N. Poirier, P. Khairy, Late onset postcapillary pulmonary hypertension in patients with transposition of the great arteries and mustard or senning baffles, *JAHA* 6 (10) (2017), <https://doi.org/10.1161/JAHA.117.006481>.
- [32] M.E. Menting, A.E. van den Bosch, J.S. McGhie, et al., Assessment of ventricular function in adults with repaired tetralogy of Fallot using myocardial deformation imaging, *Eur. Heart J. Cardiovasc. Imaging* 16 (12) (2015) 1347–1357, <https://doi.org/10.1093/ehjci/jev090>.
- [33] A.C. van Dissel, M.M. Winter, T. van der Bom, et al., Long-term clinical outcomes of valsartan in patients with a systemic right ventricle: Follow-up of a multicenter randomized controlled trial, *Int. J. Cardiol.* 278 (2019) 84–87, <https://doi.org/10.1016/j.ijcard.2018.11.027>.
- [34] A. Akashiba, H. Ono, Y. Ono, T. Ishimitsu, H. Matsuoka, Valsartan improves L-NAME-exacerbated cardiac fibrosis with TGF- $\beta$  inhibition and apoptosis induction in spontaneously hypertensive rats, *J. Cardiol.* 52 (3) (2008) 239–246, <https://doi.org/10.1016/j.jjcc.2008.07.018>.
- [35] E. Zaragoza-Macias, A.N. Zaidi, N. Dendukuri, A. Marelli, Medical therapy for systemic right ventricles: a systematic review (Part 1) for the 2018 AHA/ACC Guideline for the Management of Adults With Congenital Heart Disease: a report of the American College of Cardiology/American Heart Association Task Force on Clinical Practice Guidelines, *Circulation* 139 (14) (2019) e801–e813, <https://doi.org/10.1161/CIR.0000000000000604>.
- [36] H. Peng, O.A. Carretero, N. Vuljaj, et al., Angiotensin-converting enzyme inhibitors: a new mechanism of action, *Circulation* 112 (16) (2005) 2436–2445, <https://doi.org/10.1161/CIRCULATIONAHA.104.528695>.
- [37] F. Roubille, D. Busseuil, N. Merlet, E.A. Kritikou, E. Rhéaume, J.C. Tardif, Investigational drugs targeting cardiac fibrosis, *Expert Rev Cardiovasc Ther.* 12 (1) (2014) 111–125, <https://doi.org/10.1586/14779072.2013.839942>.
- [38] N. Vejlsturp, K. Sørensen, E. Mattsson, et al., Long-Term outcome of Mustard/Senning correction for transposition of the great arteries in Sweden and Denmark, *Circulation* 132 (8) (2015) 633–638, <https://doi.org/10.1161/CIRCULATIONAHA.114.010770>.
- [39] A. Raissadati, H. Nieminen, H. Sairanen, E. Jokinen, Outcomes after the mustard, senning and arterial switch operation for treatment of transposition of the great arteries in Finland: a nationwide 4-decade perspective, *Eur J Cardiothorac Surg.* 52 (3) (2017) 573–580, <https://doi.org/10.1093/ejcts/ezx107>.
- [40] P. Moons, M. Gewillig, T. Sluysmans, et al., Long term outcome up to 30 years after the Mustard or Senning operation: a nationwide multicentre study in Belgium, *Heart* 90 (3) (2004) 307–313, <https://doi.org/10.1136/hrt.2002.007138>.
- [41] G. Reiter, C. Reiter, C. Kräuter, M. Fuchsjäger, U. Reiter, Cardiac magnetic resonance T1 mapping. Part 1: Aspects of acquisition and evaluation, *Eur. J. Radiol.* 109 (2018) 223–234, <https://doi.org/10.1016/j.ejrad.2018.10.011>.