

Special Section: Vascular Contributions to Alzheimer's Disease

# Peripheral inflammatory markers indicate microstructural damage within periventricular white matter hyperintensities in Alzheimer's disease: A preliminary report

Walter Swardfager<sup>a,b,c,d,e,\*</sup>, Di Yu<sup>a,b,c,d</sup>, Joel Ramirez<sup>a,c,d</sup>, Hugo Cogo-Moreira<sup>f</sup>, Gregory Szilagy<sup>a,c,d</sup>, Melissa F. Holmes<sup>a,c,d</sup>, Christopher J. M. Scott<sup>a,c,d</sup>, Gustavo Scola<sup>b,g</sup>, Pak C. Chan<sup>h,i</sup>, Jialun Chen<sup>a</sup>, Parco Chan<sup>a,b</sup>, Demetrios J. Sahlas<sup>j</sup>, Nathan Herrmann<sup>a</sup>, Krista L. Lanctôt<sup>a,b,c,e</sup>, Ana C. Andreazza<sup>b,g</sup>, Jacqueline A. Pettersen<sup>k</sup>, Sandra E. Black<sup>a,c,d,h,l</sup>

<sup>a</sup>Hurvitz Brain Sciences Program, Sunnybrook Research Institute, Toronto, Ontario, Canada

<sup>b</sup>Department of Pharmacology and Toxicology, University of Toronto, Toronto, Ontario, Canada

<sup>c</sup>Canadian Partnership for Stroke Recovery, Sunnybrook Research Institute, Toronto, Ontario, Canada

<sup>d</sup>LC Campbell Cognitive Neurology Unit, Sunnybrook Research Institute, Toronto, Ontario, Canada

<sup>e</sup>University Health Network Toronto Rehabilitation Institute, Toronto, Ontario, Canada

<sup>f</sup>Departamento Psiquiatria, Universidade Federal de São Paulo, São Paulo, São Paulo, Brazil

<sup>g</sup>Anxiety and Mood Disorders Department, Centre for Addictions and Mental Health, Toronto, Ontario, Canada

<sup>h</sup>Department of Clinical Pathology, Sunnybrook Health Sciences Centre, Toronto, Ontario, Canada

<sup>i</sup>Department of Laboratory Medicine and Pathobiology, University of Toronto, Toronto, Ontario, Canada

<sup>j</sup>Department of Medicine (Neurology Division), McMaster University, Hamilton, Ontario, Canada

<sup>k</sup>Department of Medicine (Neurology Division), University of Northern British Columbia, British Columbia, Canada

<sup>l</sup>Department of Medicine (Neurology Division), University of Toronto, Toronto, Ontario, Canada

## Abstract

**Introduction:** White matter hyperintensities (WMH) presumed to reflect cerebral small vessel disease and increased peripheral inflammatory markers are found commonly in Alzheimer's disease (AD), but their interrelationships remain unclear.

**Methods:** Inflammatory markers were assayed in 54 elderly participants ( $n = 16$  with AD). Periventricular WMH were delineated from T1, T2/proton density, and fluid-attenuated magnetic resonance imaging using semiautomated fuzzy lesion extraction and coregistered with maps of fractional anisotropy (FA), a measure of microstructural integrity assessed using diffusion tensor imaging.

**Results:** Mean FA within periventricular WMH was associated with an inflammatory factor consisting of interleukin (IL)-1 $\beta$ , tumor necrosis factor, IL-10, IL-21, and IL-23 in patients with AD ( $\rho = -0.703$ ,  $P = .002$ ) but not in healthy elderly ( $\rho = 0.217$ ,  $P = .190$ ). Inflammation was associated with greater FA in deep WMH in healthy elderly ( $\rho = 0.425$ ,  $P = .008$ ) but not in patients with AD ( $\rho = 0.174$ ,  $P = .520$ ).

**Discussion:** Peripheral inflammatory markers may be differentially related to microstructural characteristics within the white matter affected by cerebral small vessel disease in elders with and without AD.

© 2017 The Authors. Published by Elsevier Inc. on behalf of the Alzheimer's Association. This is an open access article under the CC BY-NC-ND license (<http://creativecommons.org/licenses/by-nc-nd/4.0/>).

## Keywords:

Small vessel disease; Cerebrovascular disease; Diffusion tensor imaging; Cytokine; Inflammation; Microstructure; White matter disease; Alzheimer's disease; Confirmatory factor analysis

## 1. Introduction

Many inflammatory markers are increased in peripheral blood in people with Alzheimer's disease (AD), although most findings have been inconsistent, showing high

<sup>§</sup>These authors contributed equally to this work.

\*Corresponding author. Tel.: +1-416-480-6100; Fax: +1-416-480-4223.

E-mail address: [w.swardfager@utoronto.ca](mailto:w.swardfager@utoronto.ca)

heterogeneity between studies [1]. Several studies have suggested longitudinal relationships between peripheral inflammatory markers and cognitive decline in AD [2], but how these observations relate precisely to changes in brain tissue is not well understood.

Lesions to the white matter because of disease of the small cerebral blood vessels may contribute to the onset and progression of AD [3]. Observed clinically as white matter hyperintensities (WMHs) on T2-weighted magnetic resonance imaging (MRI), these lesions may result from hypoperfusion secondary to arteriosclerosis, cerebral amyloid angiopathy, or venous disease with collagenosis or tortuosity [4]. Pathology studies reveal loss of the ventricular ependyma in the vicinity of periventricular WMH and arteriolar sclerosis within deep WMH [4,5]. Immunohistochemistry reveals markers of hypoxia and endothelial activation in WMH, in concert with microglial and astrocyte activation [4], suggesting a link between WMH and inflammatory activation.

The purpose of this study was to determine how peripheral blood cytokines related to AD or implicated in hypoxic responses are related to deep and periventricular WMH, both in people with and without AD. Recently reduced microstructural integrity was found in WMH, with lower fractional anisotropy (FA) particularly in cases of more severe WMH [6]. Appreciating that WMHs are associated with inflammatory mechanisms that may threaten white matter microstructural integrity, here we examine the relationship between peripheral inflammatory markers and FA within white matter lesions.

## 2. Methods

To represent strata of high WMH and low WMH burden, patients from transient ischemic attack (non-AD with extensive WMH) and memory clinics (AD with and without extensive WMH) and healthy control subjects of similar age (minimal WMH) were recruited. Patients with cortical infarcts were excluded.

MRI (T1, proton density/T2, and fluid-attenuated inversion recovery [FLAIR]) was performed at 3.0 T and intensity inhomogeneity corrected using N3. Deep and periventricular WMH were delineated using Lesion Explorer, an in-house semiautomatic segmentation ([www.sabre.brainlab.ca](http://www.sabre.brainlab.ca)) with a three-dimensional connectivity algorithm [7].

Diffusion tensor imaging (DTI) was obtained, and WMH masks were transformed to DTI space using parameters obtained from the T2 and the DTI B0 images. Values of FA were derived after eddy-current and motion-correction using the FMRIB Diffusion Toolbox; means, medians, and standard deviations were calculated for deep and periventricular WMH regions separately.

Certain inflammatory markers with suspected roles in AD [1] or cerebral hypoxic responses [8–10] were assayed by multiplex magnetic bead immunoassay (EMD Millipore) from serum samples obtained at the time of MRI (stored at

–80°C). It was considered that hypoxia might contribute to the production of interleukin (IL)-23, IL-21, and IL-17 cytokines [9]; tumor necrosis factor (TNF), IL-1 $\beta$ , and IL-6 are also involved in hypoxic responses [10] and AD [1]; and these can induce IL-10 release [10] as part of the immune response. Confirmatory factor analysis (CFA) was used to identify a single factor accounting for variation (and covariation) in cytokine data (Mplus, version 7.4, Muthén & Muthén, Los Angeles, CA, USA). To evaluate the proposed model we considered a nonsignificant  $\chi^2$ , comparative fit index >0.90, Tucker-Lewis Index >0.95, root mean square error of approximation <0.06, and weighted root mean square residual near or <0.08 to indicate adequate fit [11]. Inflammatory factor scores were compared with mean FA values in deep and periventricular WMH using Spearman's rho in AD and non-AD participants separately, and Bonferroni corrected ( $\alpha = 0.05/4$ ).

## 3. Results

Concentrations of IL-1 $\beta$ , TNF, IL-10, IL-21, and IL-23 informed an inflammatory factor (Fig. 1) with excellent fit indices ( $\chi^2_{(5)} = 6.8774$ ,  $P = .230$ ; root mean square error of approximation = 0.070, comparative fit index = 0.972, Tucker-Lewis Index = 0.945, and weighted root mean square residual = 0.049), although IL-6, IL-17A, and IL-17F were excluded from the model because of poor factor loadings, resulting in poor fit indices.

MRI volumetrics and FA maps were obtained for 54 participants including 16 AD ( $76.4 \pm 7.7$  years, 51.2% male) and 38 non-AD subjects ( $71.4 \pm 9.5$  years, 44.8% male) similar in age and gender proportion ( $P > .05$ ). Volumes of deep ( $2136 \pm 2550$  vs.  $1627 \pm 2049$  mm<sup>3</sup>,  $P = .331$ ) and periventricular ( $19,274 \pm 21,947$  vs.  $15,812 \pm 19,279$  mm<sup>3</sup>,  $P = .464$ ) WMH did not differ between AD and non-AD participants. Mean FA in deep

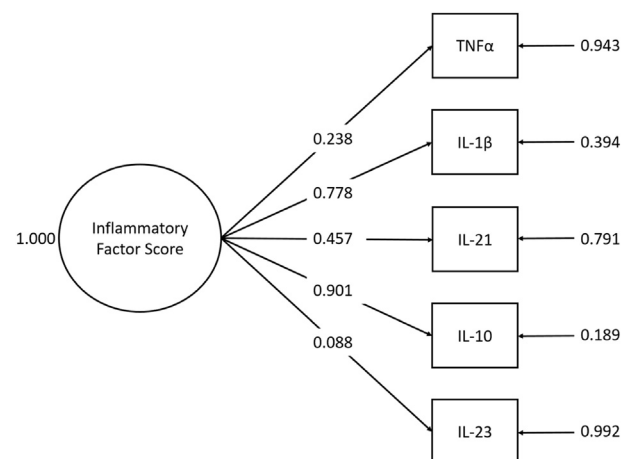


Fig. 1. Structure of an inflammatory factor informed by five cytokines. Factor loadings onto the inflammatory factor for each cytokine shown in column at right and residual variances shown in column at left. Abbreviations: IL, interleukin; TNF, tumor necrosis factor.

( $0.268 \pm 0.055$  vs.  $0.277 \pm 0.065$ ,  $P = .605$ ) and periventricular ( $0.239 \pm 0.046$  vs.  $0.236 \pm 0.041$ ,  $P = .814$ ) WMH did not differ between AD and non-AD participants.

The inflammatory factor score was correlated with lower mean FA in periventricular WMH ( $\rho = -0.703$ ,  $P = .002$ ) in patients with AD but not in others ( $\rho = 0.217$ ,  $P = .190$ ; Fig. 2A). The inflammatory factor score was associated with higher mean FA in deep WMH in non-AD participants ( $\rho = 0.425$ ,  $P = .008$ ) but not in those with AD ( $\rho = 0.174$ ,  $P = .520$ ; Fig. 2B). In post

hoc comparisons, the inflammatory factor score was not correlated with WMH volumes in either group (all  $P > .3$ ).

#### 4. Discussion

These preliminary data suggest that microstructural white matter damage because of small vessel disease is associated with a peripheral inflammatory response in AD. Consistent with a previous report [12], correlations between inflammatory markers and volumes of deep or periventricular WMH were not observed, although here this may be because of small sample size. In this study, the combination of anatomic and T2-weighted MRI sequences to delineate WMH and DTI coregistration to assess the integrity of tissue within these lesions was required to observe associations.

The inflammatory factor tested included the proinflammatory cytokines TNF and IL-1 $\beta$  that have been associated with AD [1], the immunoregulatory cytokine IL-10, and the cytokines IL-21 and IL-23 less commonly measured in AD and not surveyed previously in relation to WMH. The findings suggest potential utility in surveying inflammatory markers more broadly in AD or small vessel disease populations and of combining multiple markers to characterize and quantify relevant inflammatory activities.

In participants with AD, the inflammatory factor was associated with lower FA in periventricular WMH, but no relationship was found with deep WMH. These findings in patients with AD would be consistent with hypothesized synergy between AD and small vessel disease. In animal models, the combination of ischemia and amyloid causes greater microglial activation than either alone, resulting in additive depression of entorhinal cortical synapses [13]. In an animal model, blocking the action of IL-1 $\beta$  reversed that effect *ex vivo*, suggesting that neuroinflammation mediates synergy between amyloid and ischemia. It is therefore plausible that the degree of tissue disruption within ischemic brain lesions would be related to an inflammatory response, specifically in participants with AD.

In participants without AD, the identified inflammatory factor was neutral in relation to periventricular WMH microstructure but was associated with greater FA in deep WMH. Many cytokines have proinflammatory and anti-inflammatory effects; for instance, IL-10 is likely to be neuroprotective in stroke [9,10], although its role in small vessel disease is not well understood. In this study, CFA confirmed that the expression of IL-10 tended to co-occur with inflammatory cytokines. It has been described that IL-21 not only contributes to neuroinflammatory responses but also to IL-10 production from a regulatory population of B cells [14]. The present findings *in toto* suggest that the possible beneficial effects of certain inflammatory processes on WMH microstructure may not be realized in AD. Further studies should seek to replicate and elaborate on these results.

In a previous clinical study, increased TNF was found to predict cognitive progression in AD, suggesting potential clinical relevance of the present findings [2]. In another

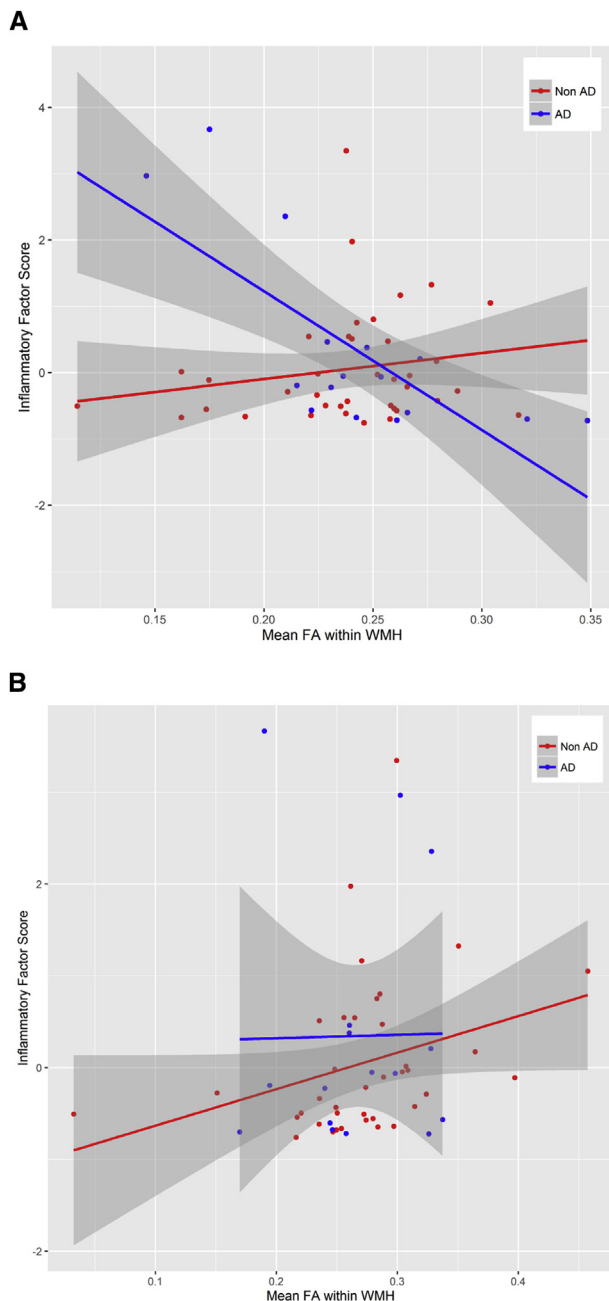


Fig. 2. Correlations between a peripheral inflammatory factor and microstructural integrity within (A) periventricular WMH and (B) deep WMH. Abbreviations: AD, Alzheimer's disease; FA, fractional anisotropy; WMH, white matter hyperintensity.

study, peripheral TNF responses predicted poorer cognitive status specifically in the presence of vascular disease, whereas predominating IL-10 responses were associated with better cognitive status [15]. Both IL-23 and IL-21 have been implicated in AD [8,16] and in cerebral hypoxic responses [9,17], although their roles in small vessel disease have not been described. IL-23 stabilizes T cells expressing IL-17A and IL-17F, but IL-17A and IL-17F did not appear to be part of the inflammatory factor modeled here, suggesting little shared variance between peripheral IL-17 effector cytokines and the others included. This and other potential factor structures should be tested and confirmed in future studies. Regardless, these preliminary data suggest that expression of several intercorrelated pleiotropic cytokines may constitute an immune signature of vulnerability to cerebral small vessel disease in the periventricular white matter of those with AD.

Although this cohort was recruited carefully such that demographics did not differ between AD and non-AD groups, the small sample size precluded control for potential demographic confounders; however, demographics did not correlate with FA or inflammatory factors. Larger studies will be required to determine if peripheral inflammation might also reflect WMH volumes. Although peripheral cytokines do not necessarily mirror microglial activity, inflammatory signals can be propagated across the blood-brain barrier by multiple known mechanisms [1], and increased permeability of the blood-brain barrier is seen in the vicinity of WMH at autopsy [4,5], which may alter peripheral inflammatory signatures. As a potential limitation, this inflammatory factor should be considered only one among many possible models; however, its validity was verified, demonstrating the utility of CFA to model and estimate immune activation as a latent variable using multiple cytokines as observed indicators. Larger replication studies might examine additional white matter characteristics in relation to inflammation (e.g., mean diffusivity in WMH lesions and in adjacent normal appearing white matter), alternative inflammatory factors (e.g., composed of other cytokines and growth factors), and potential relationships between these parameters and cognitive and functional decline or cerebral amyloid and tau.

## Acknowledgments

This study was supported by the Canadian Institutes of Health Research, the Heart and Stroke Foundation Canadian Partnership for Stroke Recovery, the Alzheimer Society of Canada, and the Heart and Stroke Foundation of Canada. W.S. gratefully acknowledges support from the Department of Pharmacology and Toxicology, University of Toronto; the Hurvitz Brain Sciences Program, Sunnybrook Research Institute; and the Department of Psychiatry, Sunnybrook Health Sciences Centre. S.E.B. gratefully acknowledges support from the Brill Chair in Neurology, Department of Medicine, Sunnybrook Health Sciences Centre, University

of Toronto; the Toronto Dementia Research Alliance, University of Toronto; the Department of Medicine, Sunnybrook Health Sciences Centre; and the Hurvitz Brain Sciences Program, Sunnybrook Research Institute.

Conflicts of interest: W.S. reports no conflicts of interest. S.E.B. reports institutional grants from Pfizer, GE Healthcare, Eli Lilly, Transition Therapeutics, Novartis, Roche, Cognoptix, and Biogen Idec and personal honoraria from Boehringer Ingelheim, Novartis, Merck, and Eli Lilly.

## RESEARCH IN CONTEXT

1. **Systematic review:** The authors identified from publicly available sources, abstracts, and presentations, publications that describe relationships between peripheral inflammatory activity and Alzheimer's disease (AD), and the potential relevance of cerebral small vessel disease in AD; however, relationships between peripheral inflammatory markers and small vessel disease characteristics have not been established *in vivo*.
2. **Interpretation:** Preliminary findings suggest that microstructural characteristics of the white matter affected by periventricular cerebral small vessel disease are related to peripheral inflammatory activity, specifically in patients with AD. A multimodal magnetic resonance imaging method, including T1, T2, fluid attenuated inversion recovery (FLAIR), and diffusion tensor imaging, may be needed to localize and quantify tissue characteristics related to inflammation.
3. **Future directions:** The results should be replicated and elaborated on through (1) further quantification of tissue characteristics relevant to inflammation using diffusion tensor imaging within and around white matter lesions, (2) more robust characterization of peripheral inflammatory responses related to cerebral small vessel disease, and (3) the utility of these imaging and peripheral inflammatory biomarkers to predict AD progression.

## References

- [1] Swardfager W, Lanctot K, Rothenburg L, Wong A, Cappell J, Herrmann N. A meta-analysis of cytokines in Alzheimer's disease. *Biol Psychiatry* 2010;68:930–41.
- [2] Holmes C, Cunningham C, Zotova E, Woolford J, Dean C, Kerr S, et al. Systemic inflammation and disease progression in Alzheimer disease. *Neurology* 2009;73:768–74.
- [3] Lee S, Viqar F, Zimmerman ME, Narkhede A, Tosto G, Benzinger TL, et al. White matter hyperintensities are a core feature of Alzheimer's disease: evidence from the dominantly inherited Alzheimer network. *Ann Neurol* 2016;79:929–39.

- [4] Black S, Gao F, Bilbao J. Understanding white matter disease: imaging-pathological correlations in vascular cognitive impairment. *Stroke* 2009;40:S48–52.
- [5] Fernando MS, Simpson JE, Matthews F, Brayne C, Lewis CE, Barber R, et al. White matter lesions in an unselected cohort of the elderly: molecular pathology suggests origin from chronic hypoperfusion injury. *Stroke* 2006;37:1391–8.
- [6] Maniega SM, Valdes Hernandez MC, Clayden JD, Royle NA, Murray C, Morris Z, et al. White matter hyperintensities and normal-appearing white matter integrity in the aging brain. *Neurobiol Aging* 2015;36:909–18.
- [7] Ramirez J, Gibson E, Quidus A, Lobaugh NJ, Feinstein A, Levine B, et al. Lesion Explorer: a comprehensive segmentation and parcellation package to obtain regional volumetrics for subcortical hyperintensities and intracranial tissue. *Neuroimage* 2011;54:963–73.
- [8] Vom Berg J, Prokop S, Miller KR, Obst J, Kalin RE, Lopategui-Cabezas I, et al. Inhibition of IL-12/IL-23 signaling reduces Alzheimer's disease-like pathology and cognitive decline. *Nat Med* 2012;18:1812–9.
- [9] Swardfager W, Winer DA, Herrmann N, Winer S, Lanctot KL. Interleukin-17 in post-stroke neurodegeneration. *Neurosci Biobehav Rev* 2013;37:436–47.
- [10] Iadecola C, Anrather J. The immunology of stroke: from mechanisms to translation. *Nat Med* 2011;17:796–808.
- [11] Marsh HW, Hau KT, Wen Z. In search of golden rules: comment on hypothesis-testing approaches to setting cutoff values for fit indexes and dangers in overgeneralizing Hu and Bentler's (1999) findings. *Struct Equ Modeling* 2004;11:320–41.
- [12] Aribisala BS, Wiseman S, Morris Z, Valdes-Hernandez MC, Royle NA, Maniega SM, et al. Circulating inflammatory markers are associated with magnetic resonance imaging-visible perivascular spaces but not directly with white matter hyperintensities. *Stroke* 2014;45:605–7.
- [13] Origlia N, Crisculo C, Arancio O, Yan SS, Domenici L. RAGE inhibition in microglia prevents ischemia-dependent synaptic dysfunction in an amyloid-enriched environment. *J Neurosci* 2014;34:8749–60.
- [14] Spolski R, Leonard WJ. Interleukin-21: a double-edged sword with therapeutic potential. *Nat Rev Drug Discov* 2014;13:379–95.
- [15] van Exel E, de Craen AJ, Remarque EJ, Gussekloo J, Houx P, Bootsma-van der Wiel A, et al. Interaction of atherosclerosis and inflammation in elderly subjects with poor cognitive function. *Neurology* 2003;61:1695–701.
- [16] Saresella M, Calabrese E, Marventano I, Piancone F, Gatti A, Alberoni M, et al. Increased activity of Th-17 and Th-9 lymphocytes and a skewing of the post-thymic differentiation pathway are seen in Alzheimer's disease. *Brain Behav Immun* 2011;25:539–47.
- [17] Gelderblom M, Weymar A, Bernreuther C, Velden J, Arunachalam P, Steinbach K, et al. Neutralization of the IL-17 axis diminishes neutrophil invasion and protects from ischemic stroke. *Blood* 2012;120:3793–802.