

# Treat-and-extend regimen for management of neovascular age-related macular degeneration: recommendations from the Hong Kong Retina Expert Panel

Ian YH Wong<sup>1</sup>, MBBS, FCOphthHK, FHKAM(Ophth), Danny SC Ng<sup>2</sup>, MBBS, FCOphthHK, FHKAM(Ophth), Nicholas SK Fung<sup>1</sup>, MBChB, FCOphthHK, FHKAM(Ophth), Yvonne Chan<sup>3</sup>, MBBS, Derek CY Chung<sup>3</sup>, MBBS, FCOphthHK, FHKAM(Ophth), Mary Ho<sup>4</sup>, MBChB, FCOphthHK, FHKAM(Ophth), Callie KL Ko<sup>5</sup>, MBBS, FCOphthHK, FHKAM(Ophth), Joy WY Leung<sup>5</sup>, MBBS, FCOphthHK, FHKAM(Ophth), Shaheeda Mohammed<sup>6</sup>, MBBS, FCOphthHK, FHKAM(Ophth), Helena PY Sir<sup>4</sup>, MBBS, FCOphthHK, FHKAM(Ophth), Heather HY Tang<sup>3</sup>, MBChB, FCOphthHK, FHKAM(Ophth), Raymond LM Wong<sup>6</sup>, MBBS, FCOphthHK, FHKAM(Ophth), Timothy YY Lai<sup>2,7</sup>, MBBS, FCOphthHK, FHKAM(Ophth)

<sup>1</sup>Eye Institute, The University of Hong Kong

<sup>2</sup>Department of Ophthalmology & Visual Sciences, The Chinese University of Hong Kong, Hong Kong

<sup>3</sup>Department of Ophthalmology, United Christian Hospital, Hong Kong

<sup>4</sup>Department of Ophthalmology & Visual Sciences, Prince of Wales Hospital, Hong Kong

<sup>5</sup>Department of Ophthalmology, Tung Wah Eastern Hospital, Hong Kong

<sup>6</sup>Hong Kong Eye Hospital, Hong Kong

<sup>7</sup>2010 Eye & Cataract Centre, Tsim Sha Tsui, Hong Kong

## Correspondence and reprint requests:

Dr Timothy YY Lai, Department of Ophthalmology & Visual Sciences, The Chinese University of Hong Kong, Hong Kong.

Email: tyylai@cuhk.edu.hk

## Abstract

Antivascular endothelial growth factor (anti-VEGF) agents are a safe and effective treatment option for neovascular age-related macular degeneration (nAMD). However, undertreatment related to the costs and route of administration of anti-VEGF agents remains a common problem for nAMD patients. The treat-and-extend (T&E) regimen for nAMD has proven to balance clinical effectivity with reduced numbers of injections. However, implementation of the T&E regimen depends on the capacity and resources of clinics and patient compliance. To determine the optimal T&E regimen for Hong Kong, a

panel of retina specialists was initiated by MediPaper Medical Communications Limited to discuss the benefits and hurdles in adopting the T&E regimen and to develop recommendations for patient selection based on clinical needs, dosing criteria, and dosing regimen. Key recommendations included selecting patients with only-eye or recurrence for the T&E regimen, pre-booking clinic appointments to reduce patient visits, communicating the T&E regimen with non-vitreoretinal physicians and trainees, extending the maximum dose interval to 16 weeks, and actively engaging patients in decision making.

*Key words:* Aflibercept; Macular degeneration; Ranibizumab; Vascular endothelial growth factors

## Introduction

Neovascular age-related macular degeneration (nAMD) owing to leakage or bleeding from choroidal neovascularization is a common cause of central vision loss in the developed world.<sup>1</sup> A meta-analysis in 2010 reported that the prevalence of nAMD among those aged 40 to 79 years was 6.8% for Asians and 8.8% for Caucasians.<sup>2,3</sup> Both of these populations share similar risk factors for nAMD, such as old age, smoking, obesity, sun exposure, and cardiovascular disease.<sup>2</sup>

Treatment goals for nAMD are to maximize and maintain visual acuity, reduce fluid and blood leakage, and induce regression of choroidal neovascularization.<sup>2</sup> The current gold standard treatment for nAMD is intraocular injection of anti-vascular endothelial growth factor (anti-VEGF) agents to inhibit the development of abnormal blood vessels.<sup>4</sup> Commonly used on-label anti-VEGF agents include ranibizumab and aflibercept.<sup>5</sup> These drugs are effective<sup>4</sup> but expensive and require frequent intraocular injections.

Based on pivotal phase-3 clinical trials, the initial recommended injection regimen was monthly or bi-monthly.<sup>2,6-9</sup> However, repeat injections put pressure on the overburdened eye clinics, and patients with reduced symptoms may halt the treatment. It is not uncommon for patients to be treated *reactively* (ie, as needed) upon symptom exacerbation. This may result in undertreatment and suboptimal outcomes.<sup>10-12</sup>

Therefore, physicians aim to balance the injection frequency with clinical outcomes and to determine an optimal, clinically feasible regimen. One strategy for patients responding well to anti-VEGF therapy is to use the treat-and-extend (T&E) regimen, which is a *proactive* regimen that allows for extension of visit intervals in patients without clinical evidence of recurring or worsening disease activity.<sup>13</sup> The T&E regimen has shown favorable results. The TREX-AMD and TREND studies using ranibizumab revealed that both monthly and T&E regimens achieved comparable visual acuity outcomes.<sup>14,15</sup> In the FLUID study, patients with significantly fewer ranibizumab injections had similar mean change in visual acuity.<sup>16</sup> The ALTAIR study reported similar efficacy between 2-week and 4-week adjustment of aflibercept.<sup>17</sup> A 1-year interim study of early versus late T&E regimen using aflibercept for nAMD showed similarly good visual acuity results.<sup>18</sup> The Fight Retinal Blindness! registry revealed that the T&E regimen using either ranibizumab or aflibercept resulted in improvements in visual acuity by 24 months.<sup>19,20</sup> Compared with the reactive regimen upon symptom exacerbation that may result in undertreatment and suboptimal outcomes,<sup>10-12</sup> the proactive T&E regimen enables significant visual improvement and significantly fewer clinic visits and injections, thus reducing the cost of treatment.<sup>21</sup>

In view of the similar effectiveness of T&E and monthly regimens, this position paper aims to summarize Hong

Kong's T&E regimens in managing patients with nAMD and propose strategies for its implementation in the local setting.

## Hong Kong Retina Expert Panel Selection

In October 2018, an expert panel comprising retina specialists from public, private, and academic institutions across Hong Kong was initiated by MediPaper Medical Communications Limited to discuss the current management of nAMD and implementation of T&E regimen in Hong Kong. The objectives were to investigate how the T&E regimen is practiced in Hong Kong and to identify benefits and hurdles of practicing the T&E regimen for nAMD patients. This paper presents the recommendations of the panel, which are based on a series of presentations and round-table discussions during the meeting.

## Recommendations

### General recommendations for T&E regimen in Hong Kong

In Hong Kong, different hospitals have different practices depending on capacity and resources. The proactive T&E regimen is beneficial as it provides better visual outcomes than reactive regimen and reduces the number of visits, patient expenses, and clinic burden compared with gold standard monthly or bimonthly regimens. The burden on facilities, including optical coherence tomography (OCT), varies among different hospitals.

Careful management of resources is recommended. All procedures performed in the operating theater are associated with additional workload related to admission and discharge; therefore, outpatient treatment is recommended unless clinically contraindicated. To reduce the number of visits and clinical workload, OCT assessment and anti-VEGF drug injection should preferably be performed on the same day and thus appointments should be scheduled 2 months in advance to ensure adequate resources and facilities available. Different specialists may be involved in the treatment of the same patient. The treatment plan may be considered complex to non-vitreoretinal physicians and trainees; retinal specialists are recommended to document the treatment plan in the case management system to enable non-vitreoretinal physicians or trainees to adhere.

### Selection of patients for the T&E regimen

Identifying patients for the T&E regimen is based on clinical needs and patient preferences. Clinics may establish a set of criteria for patients to switch from the as-needed regimen to T&E regimen. In the current clinical setting, the T&E regimen is recommended for patients with only-eye or recurrent diseases.

### Loading period - initiation of doses

All patients should receive three loading doses in the first 3 months.<sup>2</sup> The injection should preferably be performed

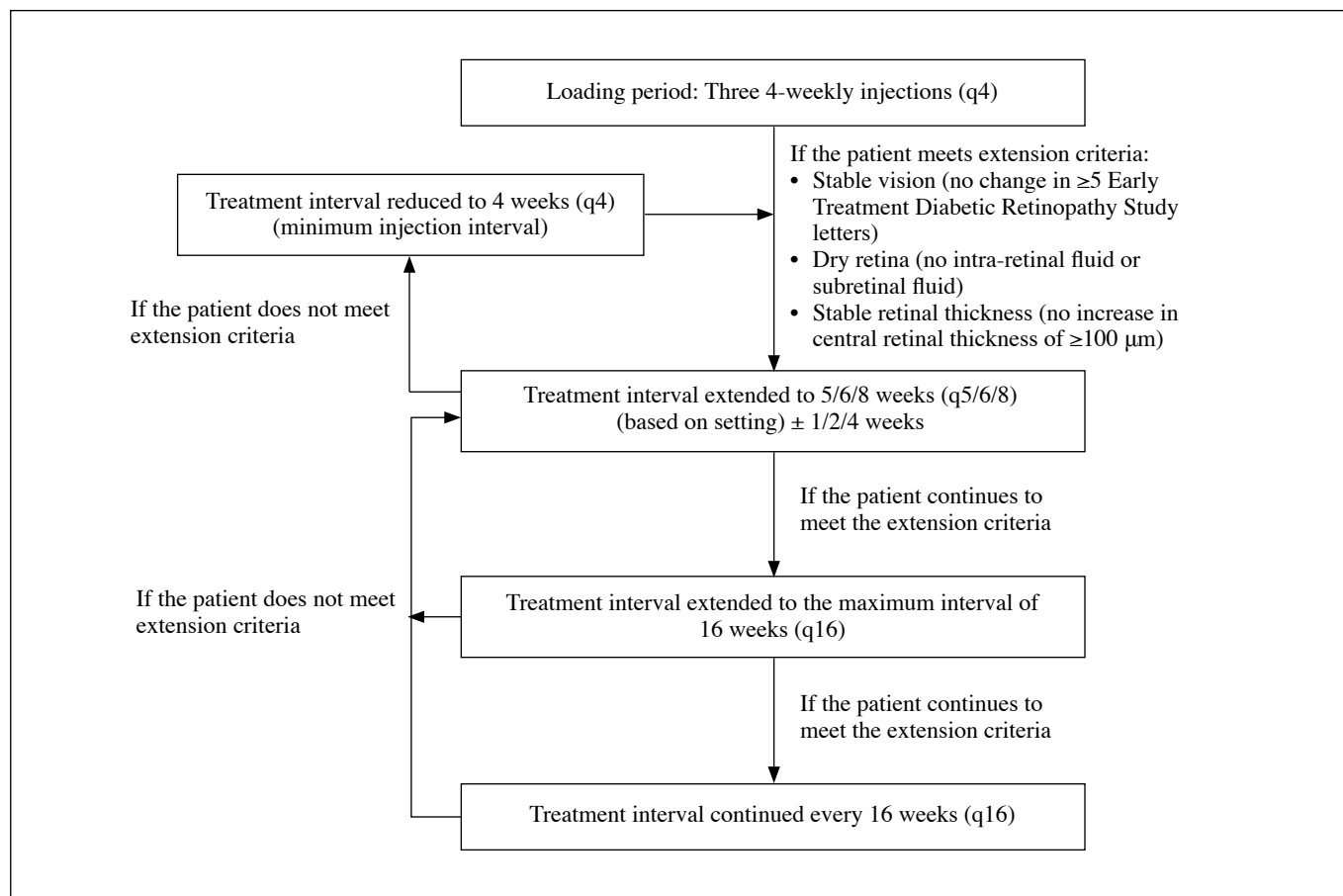


Figure. Proposed treat-and-extend regimen.

on the day of OCT assessment. If an OCT assessment is not feasible on the day of injection, it should be performed within 1 week before the injection date to assess the presence of any new or persistent fluid and to adjust the T&E regimen schedule when clinically indicated. Clinics should make efforts to fulfil the injection schedule, which may require careful scheduling of the operating theater. After three loading doses, patients are scheduled for an appointment 3 to 4 weeks later. Patients are briefed about the importance of adherence to the injection schedule to minimize rescheduling, which results in delayed schedule and interferes with the logistical planning.

**Extension of treatment interval**

A minimal interval for subsequent injections of 4 weeks (±1/2/4 weeks) is recommended.<sup>2</sup> In patients with stable vision (ie, no change in ≥5 Early Treatment Diabetic Retinopathy Study letters) and dry retina or stable retinal thickness (no increase in central retinal thickness of ≥100 μm), the treatment interval can be extended by 4 weeks (Figure). The treatment interval should either be maintained or reduced when fluid is present. The interval can be extended up to 16 weeks in patients who continue to meet the extension criteria.

**Reduction of treatment interval**

In patients not meeting the extension criteria or with presence of intraretinal fluid or subretinal fluid, the treatment interval should be reduced to 4 weeks (Figure).<sup>2</sup> Intraretinal cysts secondary to injection do not need to be treated. Pigment epithelial detachment may cause an increase in fluid, but it is not an immediate reason for reduction. However, such patients should be carefully monitored.

**Maintenance criteria**

In patients extended to the maximum interval of one injection per 16 weeks, the treatment interval should be maintained if the patient maintains a dry macula, has no loss of ≥5 Early Treatment Diabetic Retinopathy Study letters, has no increase in central retinal thickness of ≥100 μm, has no new neovascularization, and has no new macular hemorrhage.

**Cessation of treatment**

Neovascular age-related macular degeneration is a chronic condition and prolonged treatment for at least 2 to 3 years is recommended. All patients, including those who have ceased treatment, should be followed up indefinitely at least every 4 to 6 months and are advised to return for assessments upon symptom exacerbation. Even patients asymptomatic for

years may require treatment in later years owing to aging and further deterioration.

### Limitations

These recommendations are limited to patients with only-eye or recurrent diseases. Patient selection should be based on clinical needs and patients' preferences. Patients with a non-resolving vitreous hemorrhage requiring vitrectomy are considered a special population,<sup>22</sup> although they are not excluded from the T&E regimen. Vitrectomy after anti-VEGF drug injection may reduce the effectiveness of the drug,<sup>23</sup> whereas anti-VEGF drug injection after vitrectomy may increase the risk of leakage.<sup>24</sup>

### Conclusion

Adopting set criteria for selecting patients, improving

patient retention, and optimizing resources will improve treatment outcomes and standard of care of patients with nAMD.

### Acknowledgements

Medical writing assistance was provided by MediPaper Medical Communications and was funded by Bayer Healthcare.

### Declaration

Dr Timothy Lai has received consultancy honoraria and lecture fees from AbbVie, Allergan, Bayer, Genentech, Heidelberg Engineering, Novartis Pharmaceuticals, and Roche. Other authors have no conflict of interests to disclose.

### References

1. World Health Organization. *Vision 2020: The Right to Sight. Global initiative for the elimination of avoidable blindness. Action plan 2006-2011.* Geneva: World Health Organization; 2007.
2. Koh A, Lanzetta P, Lee WK, et al. *Recommended Guidelines for Use of Intravitreal Aflibercept with a Treat-and-Extend Regimen for the Management of Neovascular Age-Related Macular Degeneration in the Asia-Pacific Region: Report from a Consensus Panel.* *Asia Pac J Ophthalmol (Phila)* 2017;6:296-302. [Crossref](#)
3. Kawasaki R, Yasuda M, Song SJ, et al. *The prevalence of age-related macular degeneration in Asians: a systematic review and meta-analysis.* *Ophthalmology* 2010;117:921-7. [Crossref](#)
4. Solomon SD, Lindsley K, Vedula SS, Krzystalik MG, Hawkins BS. *Anti-vascular endothelial growth factor for neovascular age-related macular degeneration.* *Cochrane Database Syst Rev* 2014;8:CD005139. [Crossref](#)
5. Zhang X, Lai TYY. *Baseline predictors of visual acuity outcome in patients with wet age-related macular degeneration.* *Biomed Res Int* 2018;2018:9640131. [Crossref](#)
6. Brown DM, Kaiser PK, Michels M, et al. *Ranibizumab versus verteporfin for neovascular age-related macular degeneration.* *N Engl J Med* 2006;355:1432-44. [Crossref](#)
7. Rosenfeld PJ, Brown DM, Heier JS, et al. *Ranibizumab for neovascular age-related macular degeneration.* *N Engl J Med* 2006;355:1419-31. [Crossref](#)
8. Heier JS, Brown DM, Chong V, et al. *Intravitreal aflibercept (VEGF trap-eye) in wet age-related macular degeneration.* *Ophthalmology* 2012;119:2537-48. [Crossref](#)
9. Busbee BG, Ho AC, Brown DM, et al. *Twelve-month efficacy and safety of 0.5 mg or 2.0 mg ranibizumab in patients with subfoveal neovascular age-related macular degeneration.* *Ophthalmology* 2013;120:1046-56. [Crossref](#)
10. Holz FG, Tadayoni R, Beatty S, et al. *Multi-country real-life experience of anti-vascular endothelial growth factor therapy for wet age-related macular degeneration.* *Br J Ophthalmol* 2015;99:220-6. [Crossref](#)
11. Kim LN, Mehta H, Barthelmes D, Nguyen V, Gillies MC. *Metaanalysis of real-world outcomes of intravitreal ranibizumab for the treatment of neovascular age-related macular degeneration.* *Retina* 2016;36:1418-31. [Crossref](#)
12. Writing Committee for the UK Age-Related Macular Degeneration EMR Users Group. *The neovascular age-related macular degeneration database: multicenter study of 92976 ranibizumab injections: report 1: visual acuity.* *Ophthalmology* 2014;121:1092-101. [Crossref](#)
13. Amoaku W, Balaskas K, Cudrnak T, et al. *Initiation and maintenance of a Treat-and-Extend regimen for ranibizumab therapy in wet age-related macular degeneration: recommendations from the UK Retinal Outcomes Group.* *Clin Ophthalmol* 2018;12:1731-40. [Crossref](#)
14. Wykoff CC, Ou WC, Brown DM, et al. *Randomized trial of treat-and-extend versus monthly dosing for neovascular age-related macular degeneration.* *Ophthalmol Retina* 2017;1:314-21. [Crossref](#)
15. Silva R, Berta A, Larsen M, et al. *Treat-and-extend versus monthly regimen in neovascular age-related macular degeneration: results with ranibizumab from the TREND Study.* *Ophthalmology* 2018;125:57-65. [Crossref](#)
16. Guymer RH, Markey CM, McAllister IL, et al. *Tolerating sub-retinal fluid in neovascular age-related macular degeneration treated with ranibizumab using a treat-and-extend regimen: FLUID Study 24-month results.* *Ophthalmology* 2018;S0161-6420(18)32316-9. [Crossref](#)
17. Ohji M, Ayame A, Takahashi K, Kobayashi M, Terano Y. *Two different treat-and-extend dosing regimens of intravitreal aflibercept in Japanese patients with wet age-related macular degeneration: 96-week results of the ALTAIR study.* Abstract presented at EURETINA 2018; Vienna, Austria, September 20-23, 2018.
18. Mitchell P, Australia E, Souied E, Midena F, Holz P, Hykin S. *Efficacy of intravitreal aflibercept administered using treat and extend regimen over 2 years in patients with neovascular age-related macular degeneration: baseline characteristics of ARIES.* Abstract presented at EURETINA 2018; Vienna, Austria, September 20-23, 2018.
19. Arnold JJ, Campain A, Barthelmes D, et al. *Two-year outcomes of "treat and extend" intravitreal therapy for neovascular age-related macular degeneration.* *Ophthalmology* 2015;122:1212-9. [Crossref](#)

20. Barthelmes D, Nguyen V, Daien V, et al. Two year outcomes of “treat and extend” intravitreal therapy using aflibercept preferentially for neovascular age-related macular degeneration. *Retina* 2018;38:20-8. [Crossref](#)
21. Gupta OP, Shienbaum G, Patel AH, Fecarotta C, Kaiser RS, Regillo CD. A treat and extend regimen using ranibizumab for neovascular age-related macular degeneration clinical and economic impact. *Ophthalmology* 2010;117:2134-40. [Crossref](#)
22. El Annan J, Carvounis PE. Current management of vitreous hemorrhage due to proliferative diabetic retinopathy. *Int Ophthalmol Clin* 2014;54:141-53. [Crossref](#)
23. Edington M, Connolly J, Chong NV. Pharmacokinetics of intravitreal anti-VEGF drugs in vitrectomized versus non-vitrectomized eyes. *Expert Opin Drug Metab Toxicol* 2017;13:1217-24. [Crossref](#)
24. Lee SS, Ghosn C, Yu Z, et al. Vitreous VEGF clearance is increased after vitrectomy. *Invest Ophthalmol Vis Sci* 2010;51:2135-8. [Crossref](#)