

Bilateral segmental accessory iris membrane with narrow anterior chamber angle

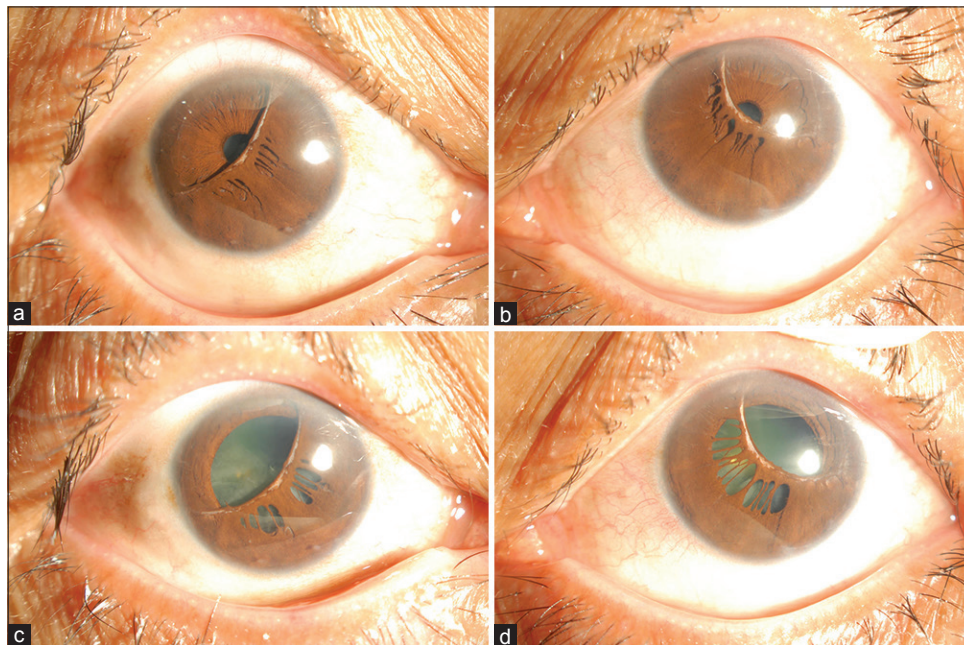


Figure 1: Anterior segment photography by slit lamp of bilateral accessory iris membrane (a and c right eye, b and d left eye)

Accessory iris membrane (AIM) is a rare anomaly characterized by hyperplasia of the superficial mesodermal layer of the iris.^[1-4] Unlike previously described cases with circumferential involvements, this is the first reported case of segmental AIM, with both eyes demonstrating duplicated iris tissue confined to the inferonasal part of the pupil and a shallow anterior chamber. A whitish band is present along the free margin of the membrane [Fig.1a and b], which appears non-contractile on pupil dilation with mydriatic [Fig.1c and d]. Ultrasound biomicroscopy and anterior segment optical coherence tomography both confirmed the location of the membranous structure anterior to the iris plane.

Financial support and sponsorship

Nil.

Conflicts of interest

There are no conflicts of interest.

*Bonnie Nga Kwan Choy, Ming Ming Zhu,
Jonathan Cheuk Hung Chan*

Department of Ophthalmology, LKS Faculty of Medicine,
The University of Hong Kong, Hong Kong

Correspondence to: Dr. Jonathan Cheuk Hung Chan,
Department of Ophthalmology, LKS Faculty of Medicine,
The University of Hong Kong, Room 301, Block B, Cyberport 4,
Hong Kong, Hong Kong S.A.R.
E-mail: jonochan@hku.hk

References

1. Bhatti SM, Kapoor HK. Bilateral accessory iris membrane. *Indian J Ophthalmol* 1998;46:110-1.
2. Levy WJ. Congenital iris lesion. *Br J Ophthalmol* 1957;41:120-3.
3. Luxenburg MN. Hyperplasia of the anterior layer of the iris stroma. *Br J Ophthalmol* 1965;49:516-20.
4. Espandar L, Allingham RR, Afshari NA. Stromal duplication of the iris. *JAMA Ophthalmol* 2013;131:1442.

This is an open access journal, and articles are distributed under the terms of the Creative Commons Attribution-NonCommercial-ShareAlike 4.0 License, which allows others to remix, tweak, and build upon the work non-commercially, as long as appropriate credit is given and the new creations are licensed under the identical terms.

Access this article online	
Quick Response Code:	Website: www.ijo.in
	DOI: 10.4103/ijo.IJO_68_19

Cite this article as: Choy BN, Zhu MM, Chan JC. Bilateral segmental accessory iris membrane with narrow anterior chamber angle. *Indian J Ophthalmol* 2019;67:1727.