

# Responding to Intraoperative Neuromonitoring Changes During Pediatric Coronal Spinal Deformity Surgery

Stephen J. Lewis, MD<sup>1,2</sup>, Ian H. Y. Wong<sup>1</sup> , Samuel Strantzas, MSc, D.ABNM<sup>1</sup>, Laura M. Holmes, MSc, CNIM<sup>1</sup>, Ian Vreugdenhil<sup>1</sup>, Hailey Bensky<sup>1</sup>, Christopher J. Nielsen, MD<sup>1</sup>, Reinhard Zeller, MD<sup>1</sup>, David E. Lebel, MD, PhD<sup>1</sup>, Marinus de Kleuver, MD<sup>2</sup>, Niccole Germscheid, MSc<sup>2</sup>, Ahmet Alanay, MD<sup>2</sup>, Sigurd Berven, MD<sup>2</sup>, Kenneth M. C. Cheung, MD<sup>2</sup>, Manabu Ito, MD<sup>2</sup>, David W. Polly, MD<sup>2</sup>, Christopher I. Shaffrey, MD<sup>2</sup>, Yong Qiu, MD<sup>2</sup>, and Lawrence G. Lenke, MD<sup>2</sup>

## Abstract

**Study Design:** Retrospective case study on prospectively collected data.

**Objectives:** The purpose of this explorative study was: 1) to determine if patterns of spinal cord injury could be detected through intraoperative neuromonitoring (IONM) changes in pediatric patients undergoing spinal deformity corrections, 2) to identify if perfusion based or direct trauma causes of IONM changes could be distinguished, 3) to observe the effects of the interventions performed in response to these events, and 4) to attempt to identify different treatment algorithms for the different causes of IONM alerts.

**Methods:** Prospectively collected neuromonitoring data in pre-established forms on consecutive pediatric patients undergoing coronal spinal deformity surgery at a single center was reviewed. Real-time data was collected on IONM alerts with >50% loss in signal. Patients with alerts were divided into 2 groups: unilateral changes (direct cord trauma), and bilateral MEP changes (cord perfusion deficits).

**Results:** A total of 97 pediatric patients involving 71 females and 26 males with a mean age of 14.9 (11-18) years were included in this study. There were 39 alerts in 27 patients (27.8% overall incidence). All bilateral changes responded to a combination of transfusion, increasing blood pressure, and rod removal. Unilateral changes as a result of direct trauma, mainly during laminotomies for osteotomies, improved with removal of the causative agent. Following corrective actions in response to the alerts, all cases were completed as planned. Signal returned to near baseline in 20/27 patients at closure, with no new neurological deficits in this series.

**Conclusion:** A high incidence of alerts occurred in this series of cases. Dividing IONM changes into perfusion-based vs direct trauma directed treatment to the offending cause, allowing for safe corrections of the deformities. Patients did not need to recover IONM signal to baseline to have a normal neurological examination.

## Keywords

scoliosis, neuromonitoring, motor evoked potentials, incomplete spinal cord injuries, Brown-Sequard syndrome, anterior cord syndrome, perfusion, anemia, transfusion, pediatric

## Introduction

Intraoperative multimodality neuromonitoring (IONM) has been established as the standard adjunct to spinal deformity surgery.<sup>1-6</sup> Despite its universal acceptance and use, there remains significant controversy into what constitutes a neuromonitoring change, what significance does that change represent, what actions should be taken in response to the change, and which factors led to the changes.

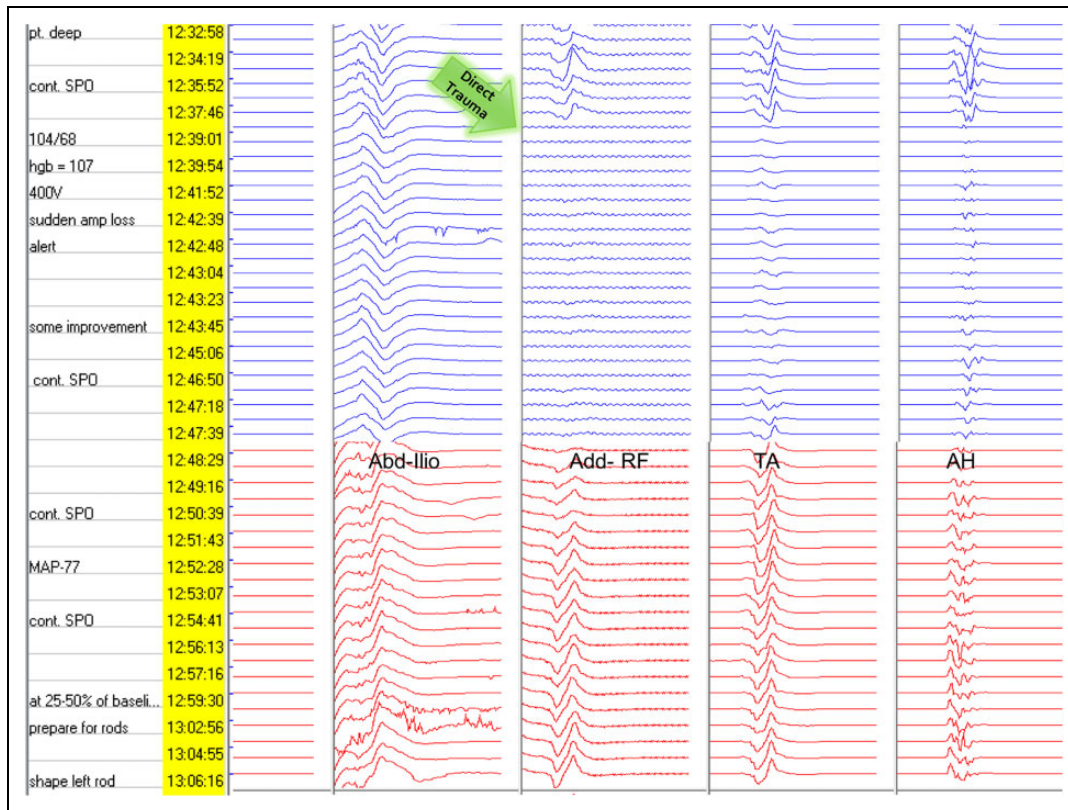
<sup>1</sup> Hospital for Sick Children, University of Toronto, Toronto, Ontario, Canada

<sup>2</sup> AOSpine Knowledge Forum Deformity, Davos, Switzerland

### Corresponding Author:

Stephen J. Lewis, Toronto Western Hospital, Division of Orthopaedic Surgery, 399 Bathurst Street 1E442, Toronto, Ontario, M5M 1K2, Canada.  
Email: stephen.lewis@uhn.ca





**Figure 1.** Example of left (blue tracing) unilateral motor-evoked potential (MEP) signal drop following trauma to the spinal cord from a Kerrison rongeur during decompression for a posterior column osteotomy. Consistent improvement in signal occurred within 5 minutes with full return occurring within 30 minutes.

There are common incomplete spinal cord syndromes that are well described, which include Brown-Sequard, anterior, posterior, and central cord syndromes.<sup>7</sup> Each of these have classic patterns of neurological deficit and represent injuries to specific regions of the spinal cord. As such, intraoperative maneuvers that injure the cord would be expected to follow these established patterns. For example, perfusion-based deficits to the spinal cord would be expected to affect the anterior circulation of the spinal cord, manifesting as bilateral loss of motor-evoked potential (MEP) signal, with preserved somatosensory-evoked potential (SSEP). Passing a sublaminar implant or instrument may injure the posterior cord, showing a loss of SSEP signal, without affecting the MEP. Placing a Kerrison rongeur laterally in the canal may produce a Brown-Sequard injury, manifesting as a unilateral loss of MEP and/or SSEP signal (Figure 1). Finally, closing an osteotomy could lead to a central cord syndrome, resulting in bilateral SSEP and MEP changes. Understanding these patterns of signal loss could alert the surgeon to the type of spinal cord injury occurring, allowing for the performance of appropriate maneuvers to reverse or address the causative event.

The purpose of this explorative study was (1) to determine if these patterns of spinal cord injury could be detected through IONM changes in pediatric patients undergoing spinal deformity corrections, (2) to identify if perfusion based or direct trauma causes of IONM changes could be distinguished,

(3) to observe the effects of the interventions performed in response to these events, and (4) to attempt to identify different treatment algorithms for the different causes of IONM alerts.

## Material and Methods

A retrospective review was performed of prospectively collected neuromonitoring data using standard forms on consecutive pediatric patients undergoing coronal plane spinal deformity surgery. The standardized forms were developed by the principle author with input from other authors providing a comprehensive functional mode of registering IONM events and the effect of interventions performed in response to IONM events. In the event of signal change, the neuromonitoring form was completed detailing surgical and/or systemic causes for the alert, actions taken in response to the alert, and outcome of the signal recovery to the alert. The inclusion criteria included pediatric patients with a minimum of 50° primary coronal deformity for idiopathic or syndromic scoliosis, undergoing primary or revision procedure, and correction facilitated with posterior column osteotomy (PCO) and/or underwent intraoperative skull-skeletal traction. The use of traction and choice of weight was at the discretion of the treating surgeon. As well, the number and level of posterior column osteotomies was determined by the surgeon.

**Table 1.** Demographic, Radiographic, and Surgical Features of the Study Patients With Comparison of Cases With and Without MEP Changes.

	All (n = 97)	No MEP Change (n = 70)	MEP Change (n = 27)	P
Age, years, mean $\pm$ SD	14.9 $\pm$ 1.7	15.1 $\pm$ 1.6	14.2 $\pm$ 1.8	.04
Sex, male:female, n	26:71	21:49	5:22	.319
Primary-Revision, n	95-2	70-0	25-2	.07
Diagnosis, n (%)				
Idiopathic	85 (87.6)	60 (85.7)	25 (92.6)	.51
Syndromic	12 (12.4)	10 (14.3)	2 (7.4)	.50
Maximum coronal Cobb angle, deg, mean $\pm$ SD	78.8 $\pm$ 17.3	76.6 $\pm$ 15.9	84.4 $\pm$ 19.8	.07
Coronal balance, mm, mean $\pm$ SD	16.7 $\pm$ 11.9	17.2 $\pm$ 12.4	15.3 $\pm$ 10.4	.47
Coronal DAR, deg/level, mean $\pm$ SD	13.2 $\pm$ 4.3	12.7 $\pm$ 3.5	14.6 $\pm$ 5.8	.13
Maximum sagittal Cobb angle, deg, mean $\pm$ SD	39.4 $\pm$ 21.2	39.7 $\pm$ 20.4	38.7 $\pm$ 23.7	.85
Sagittal balance, mm, mean $\pm$ SD	19.3 $\pm$ 29.8	20.8 $\pm$ 26.8	15.4 $\pm$ 36.6	.49
Lower extremity motor score, mean $\pm$ SD	50 $\pm$ 0	50 $\pm$ 0	50 $\pm$ 0	1
Levels fused, mean $\pm$ SD	12.9 $\pm$ 1.6	12.7 $\pm$ 1.7	13.4 $\pm$ 1.2	.02
Intraoperative traction, n (%)	44 (45.4)	33 (47.1)	11 (40.7)	.65
Osteotomy				
PCO, n (%)	32 (33.0)	18 (25.7)	14 (51.9)	.02
Number <sup>a</sup> of PCOs (mean)	4.1 $\pm$ 1.4	3.6 $\pm$ 1.1	4.8 $\pm$ 1.5	.11

Abbreviations: MEP, motor-evoked potential; DAR, deformity angle ratio; PCO, posterior column osteotomy.

<sup>a</sup>For those undergoing osteotomies.

IONM was performed with transcranial MEP, SSEP, free run electromyography (EMG), and pedicle screw stimulation EMG under total intravenous anesthesia. Patients were divided into 2 groups based on the presence or absence of MEP alerts during the surgery. Alerts were defined as a drop in MEP or SSEP signal of at least 50% from baseline signal. The precipitating event was then assessed to determine the observed neuromonitoring pattern that correlated with the IONM change.

Neurological examinations were performed once the patient awoke from anesthesia. Neurological examinations continued every 4 hours for the first 24 hours postoperatively and daily after that while in hospital.

## Results

A total of 97 paediatric patients (Table 1) involving 71 females and 26 males with a mean age of 14.9 years (range 11-18 years) were included in this study. There were 39 alerts in 27 patients (27.8% overall incidence). The patients with MEP alerts (n = 27) had a mean Cobb angle of 84.4° compared with 76.6° ( $P = .07$ ) in the group without MEP changes (n = 70). Significantly greater amount of mean number of levels fused (13.4 vs 12.7), and percent of patients treated with PCOs (51.9% vs 25.7%) were noted in the group with IONM changes. IONM alerts were divided into 2 subgroups: cases involving unilateral MEP changes and those with bilateral MEP changes (Table 2).

A single episode of a unilateral alert was observed in 9 patients and 1 patient had multiple unilateral alerts. Bilateral changes were seen in 14 patients, with 5 of these having more than one occurrence of a bilateral alert. Three patients had unilateral alerts during the laminectomy for the PCOs followed by bilateral alerts during or after rod insertion and correction maneuvers. Patients with bilateral alerts had a lower mean arterial pressure (MAP) at the time of the alert (67.6 mm Hg)

compared with the MAP observed in the unilateral alerts (77.1 mm Hg,  $P = .009$ ).

## Perfusion-Based IONM Changes

Bilateral loss in MEP amplitude was observed in 23 cases with 2 cases demonstrating concomitant SSEP amplitude losses as well. The bilateral changes were observed during the use of intra-operative traction or following deformity correction with rod insertion and compression and distraction maneuvers (Figure 2). Forty actions taken in response to these 23 IONM changes included increasing the blood pressure (n = 15), transfusing the patient (n = 6), removing the rod (n = 2), decreasing or removing the traction weight (n = 8), adjusting the anesthesia (n = 6), and administering steroids (n = 3).

Following the actions taken in response to the IONM signal loss, recovery of some MEP signal varied between 5 minutes to over an hour. In all cases, the IONM signal returned or improved sufficiently to allow for completion of the procedure. Patients with perfusion-based changes were monitored closely postoperatively for spinal cord function, and maintenance of blood pressure near their preoperative baseline pressure. Difficulties maintaining an adequate blood pressure in the setting of a low hemoglobin was treated with blood transfusion. There were no postoperative neurological deficits in this series.

## Direct Trauma

Direct trauma (n = 16) resulted in unilateral MEP alerts with 2 cases having SSEP changes as well. The changes followed pedicle screw insertion in 2 patients, laminar hook placement in 1 patient, during the decompression while performing PCOs in 6 cases, following a slip with an instrument during bone grafting (n = 1), following osteotomy closure (n = 1).

**Table 2.** Motor-Evoked Potential (MEP) Changes (n = 39).

Type of MEP Change	Unilateral (n = 16)	Bilateral (n = 23)	P
Partial MEP loss, n (%)	13 (81.2)	13 (56.5)	.17
Complete MEP loss, n (%)	3 (18.8)	10 (43.5)	.17
Associated SSEP loss, n (%)	2 (12.5)	2 (8.7)	.1
Time from start of surgery, min, mean $\pm$ SD	219.1 $\pm$ 87.1	254.5 $\pm$ 133.3	.33
<i>Action preceding alert</i>			
Traction related	0	6	.06
Pre-incision	0	2	.5
Pre-implant placement	0	2	.5
Post rod insertion	0	2	.5
Implant insertion	3	0	.06
Pedicle screw	2	0	.16
Sublaminar hook	1	0	.41
Decompression for osteotomy	6	0	.003
Post rod insertion	4	17	.004
Osteotomy closure	1	0	.41
Correction maneuver	1	0	.41
Bone graft placement	1	0	.41
<i>Hemodynamics</i>			
Mean arterial pressure, mm Hg, mean $\pm$ SD	77.1 $\pm$ 9.8	67.6 $\pm$ 11.6	.009
<i>Action taken, n</i>			
Increase blood pressure	5	15	.54
Anesthesia adjusted	1	6	.21
Steroids administered	1	3	.63
Transfused	1	8	.056
Traction weight adjusted	3	8	.47
Implant removed/adjusted	1	6	.21
Rod removed	0	2	.5
Osteotomy opened	1	0	.41
Correct kyphosis	1	0	.41
None	4	0	.02
<i>Recovery time to improved signal, min</i>			
0-5	8	8	.51
5-10	7	7	.5
10-20	1	4	.63
20-60	0	4	.13
>60	0	0	.1

Abbreviation: SSEP, somatosensory-evoked potential.

Unilateral changes as a result of direct trauma, mainly during decompressions, resolved with removal of the causative agent and time. Following the alerts, maneuvers to increase the blood pressure were performed in 5 patients, the osteotomy opened in 1 patient, traction adjusted in 3 patients, and implant removed in 1 patient.

### Recovery Time

Following the IONM alert, maneuvers performed in response to the alert led to some signal recovery in all cases of bilateral changes. In the unilateral, 8 (50%) showed some recovery within 5 minutes, a further 7 (44%) by 10 minutes and the last case showed some recovery within 20 minutes. In the bilateral, some signal return occurred in 8 (35%) within 5 minutes, in 7

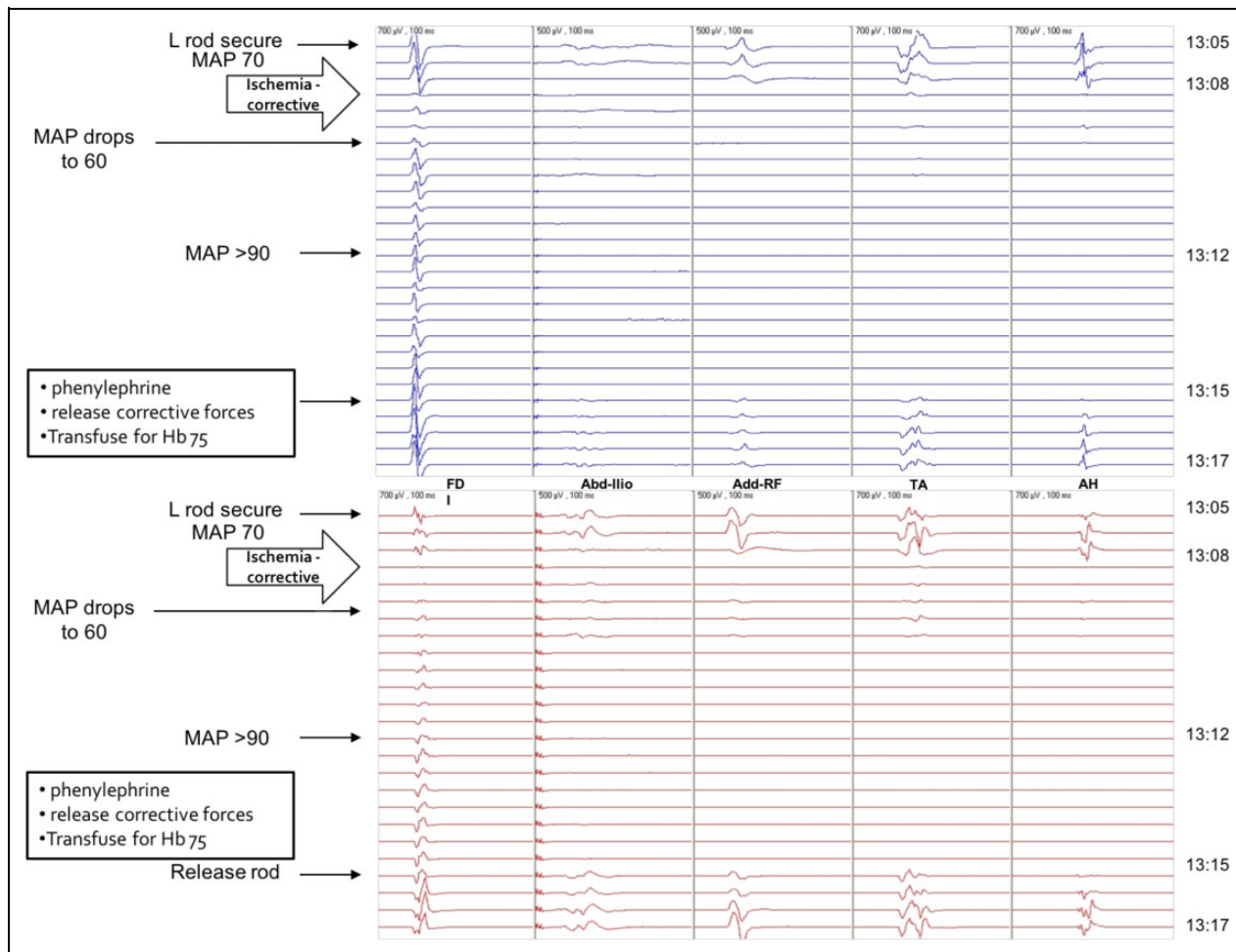
(30%) by 10 minutes, in 4 (17%) by 20 minutes, and in 4 (17%) by 60 minutes. In all, 27 patients (Table 3) at skin closure, the signal recovered to baseline (BL) in 20 (74%) patients, between 75% and 100% of BL in 3 (11%) patients, between 50% and 75% of BL in 2 (7%) patients, and between 25% and 50% of BL in 2 (7%) patients (Table 3).

### Discussion

In this series of pediatric patients undergoing deformity corrections, unilateral and bilateral changes in the transcranial MEP occurred. The unilateral changes occurred following direct trauma to the spinal cord, whereas, the bilateral changes were associated with perfusion deficits to the spinal cord. Restoring the perfusion locally through release of the traction, release of the rod, or systemically through increasing the blood pressure and/or reversing the anemia through blood transfusion, successfully addressed these changes in all patients allowing for the safe correction of the deformity and completion of the cases (Figure 3). Unilateral changes associated with direct trauma to the spinal cord were relieved by reversing the causative agent and allowing time for recovery. Repeat bilateral loss of MEP signal was the result of inadequately addressing the spinal cord perfusion deficiencies prior to obtaining the desired correction.

Yoshida et al,<sup>8</sup> in a prospective multicenter review, observed 57 alerts in 1009 deformity cases occurring with rod rotation (n = 21), pedicle screw insertion (n = 7), osteotomy closing (n = 6), compression, distraction, cantilever, or translation (n = 10), decompression (n = 3), and root sacrifice (n = 3). There were 6 other significant drops in signal that they state were unrelated to the surgery. They were able to successfully reverse these changes with counter maneuvers in 61% of these cases, with an overall rate of 2.2% new neurological deficits. Jarvis et al<sup>9</sup> described the monitoring data on 37 pediatric 3 column osteotomies. Alerts were classified into 3 types: type 1—prior to osteotomy, type 2—during decompression for osteotomy, and type 3—following osteotomy closure. Alerts were observed in 21(57%) cases, with reversing the cause of the loss in signal resulting in improved signal in all cases. There were 5 new postoperative neurological deficits (14%) with all regaining full function within 3 months of surgery. In a series of 36 pediatric patients undergoing intraoperative skull skeletal traction for scoliosis, Lewis et al<sup>10</sup> describe a reduction in transcranial MEP signal of greater than 50% in 48% of cases. The loss in MEP occurred at a mean of 94 minutes from the onset of the surgery. Decreasing or removing the traction resulted in improved signal and algorithms for managing traction related MEP changes were provided. Anemia may have played a part in some of these cases but was not measured in that series.

The importance of the MAP on spinal cord perfusion has been well established.<sup>4,11-13</sup> MAP would be expected to have the greatest impact on perfusion based IONM changes, as seen in this series with a lower MAP observed in bilateral changes as compared with unilateral changes. Most of the literature regarding MAP has been described in cervical spine pathologies, where significant blood loss is generally not a major



**Figure 2.** Bilateral MEP signal loss following rod insertion for severe scoliosis. Despite resuscitation attempts with increasing the mean arterial blood pressure, changes persisted until the rods were removed. Following blood transfusion, the rods were successfully reinserted with maintenance of the MEP signal.

**Table 3.** Final Recorded MEP signal at Time of Closure Relative to the Type of MEP Signal Loss Observed During Surgery.

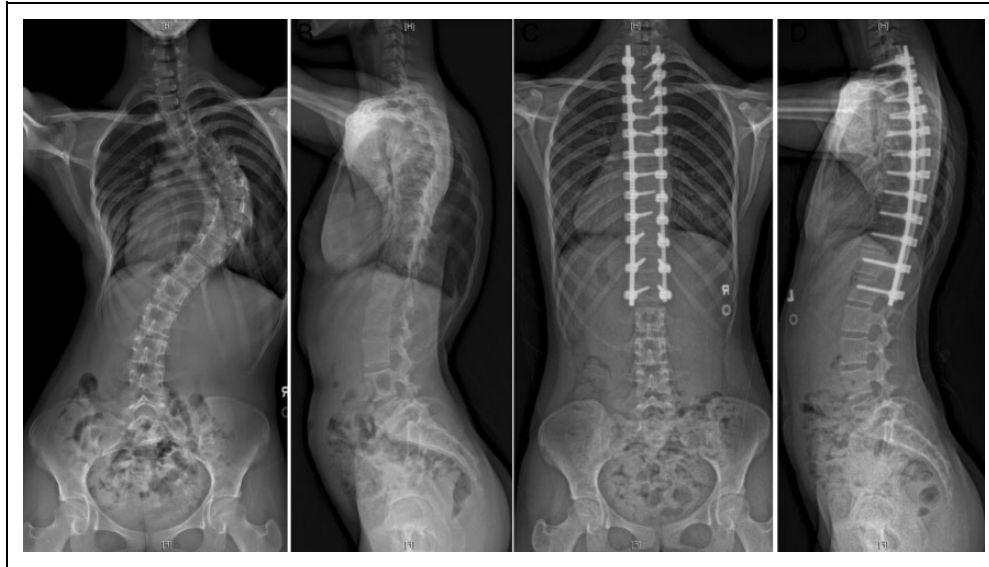
MEP Signal at Closure	Single Unilateral (n = 9)	Multiple Unilateral (n = 1)	Single Bilateral (n = 9)	Multiple Bilateral (n = 5)	Combination Unilateral/Bilateral (n = 3)
0% of baseline	0	0	0	0	0
25% of baseline	1	0	0	0	1
50% of baseline	0	0	1	0	1
75% of baseline	0	1	1	1	0
100% of baseline	8	0	7	4	1

Abbreviation: MEP, motor-evoked potential.

factor.<sup>14-24</sup> This is different from spinal deformity surgeries where blood loss can be more substantial, especially, when osteotomies are used. A low hemoglobin contributed to a decrease in MAP in a number of cases, and addressing the anemia helped to elevate the MAP.

As the series went on, we came to appreciate the importance of anemia on both the MEP signal and the blood pressure. Blood transfusion was therefore instituted as an important

component of the management of bilateral MEP amplitude loss associated with major correction maneuvers. A hemoglobin transfusion threshold value, however, could not be determined from our data for a number of reasons: blood samples were not taken routinely with each MEP loss, and factors affecting spinal cord perfusion such as curve magnitude, the acuity of the curve, the amount of correction achieved, and maneuvers performed were variable. A generalized definition of anemia in



**Figure 3.** Patient in Figure 2 following a T2 to L1 posterior fusion with posterior column osteotomies at T6-7, T7-8, T8-9, T9-10, T10-11. Complete signal loss occurred following rod insertion, which resolved following rod removal and transfusion. Successful correction was achieved without compromising the final correction following appropriate management of the intraoperative neuromonitoring changes.

this setting seemed to be associated with a value of hemoglobin unable to maintain adequate MEP signal during the correction of a spinal deformity. Strict transfusion thresholds using hemoglobin levels of 70 g/L prior to giving blood<sup>14,25-27</sup> should be reconsidered in the face of hypotension and bilateral MEP signal loss unresponsive to the usual measures.

Unlike in perfusion based neuromonitoring changes, unilateral MEP declines following a traumatic event, such as release of the concave apical facet joint with a Kerrison rongeur during a PCO, require removing concave apical facet joint with a Kerrison rongeur, require removing the offending agent and allowing for time for recovery. If the incident is not of the severity to cause permanent injury to the spinal cord, recovery of the signal was observed in less than 20 minutes in two-thirds of the events in this series.

The presence of an alert did not preclude the successful completion of the surgery. MEP signal was checked after each important step in the procedure so that the timing of the causative event could be most accurately isolated. By identifying and addressing the relevant factors, unnecessary maneuvers could be avoided. For example, checking the MEP after each pedicle screw is placed on the concave apex could isolate a malpositioned screw as opposed to checking the MEP only once after all the screws have been inserted. With the more frequent transcranial stimulation, only the offending screw would be removed as opposed to removing screws that are appropriately placed.

While we were unable to achieve all the goals of this study through this series, the findings observed can form the basis for a larger multicenter prospective series. Increasing the number of included patients, obtaining timely bloodwork, standardizing MEP protocols, identifying transfusion thresholds, and MAP targets, can provide the necessary information to better

understand the causes of the observed IONM changes. This can lead to developing management algorithms to guide surgeons through the IONM changes and improve the safety of spinal deformity surgeries. With the significant progress made in surgical implants, instruments, and techniques, the need to clearly understand and perform appropriate maneuvers in response to IONM changes will provide the safest environment to achieve the best possible corrections for our patients.

## Conclusions

A high incidence of IONM alerts occurred in this prospective series of 97 pediatric patients, in whom IONM changes were very accurately registered using a standardized detailed reporting form. Two patterns of IONM changes were identified, namely perfusion-based (bilateral changes, usually with a low MAP and hemoglobin) versus direct trauma (usually unilateral changes in response to a surgical event, with normal MAP). This helped identify different treatment algorithms to direct treatment to the offending cause, allowing for safe corrections of the deformities. Signal recovery to some degree occurred in all patients. No postoperative neurological deficits occurred. Patients do not need to recover intraoperative signal to baseline to have a normal neurological examination postoperatively. Careful monitoring and management helped to maintain spinal cord perfusion in the perioperative period. The data and findings from this explorative study will form the basis of a multicenter prospective study, which will provide further direction on the interpretation of IONM changes.

## Declaration of Conflicting Interests


The author(s) declared no potential conflicts of interest with respect to the research, authorship, and/or publication of this article.



## Funding

The author(s) disclosed receipt of the following financial support for the research, authorship, and/or publication of this article: This study was organized and funded by AOSpine International through the AOSpine Knowledge Forum Deformity, a focused group of international spine deformity experts acting on behalf of AOSpine. Study support was provided directly through the AOSpine Research Department.

## ORCID iD

Ian H. Y. Wong  <https://orcid.org/0000-0002-5381-5962>

## References

- Fehlings MG, Brodke DS, Norvell DC, Dettori JR. The evidence for intraoperative neurophysiological monitoring in spine surgery: does it make a difference? *Spine (Phila Pa 1976)*. 2010; 35(9 suppl):S37-S46.
- Padberg AM, Wilson-Holden TJ, Lenke LG, Bridwell KH. Somatosensory- and motor-evoked potential monitoring without a wake-up test during idiopathic scoliosis surgery. An accepted standard of care. *Spine (Phila Pa 1976)*. 1998;23:1392-1400.
- Pelosi L, Lamb J, Grevitt M, Mehdian SM, Webb JK, Blumhardt LD. Combined monitoring of motor and somatosensory evoked potentials in orthopaedic spinal surgery. *Clin Neurophysiol*. 2002; 113:1082-1091.
- Schwartz DM, Auerbach JD, Dormans JP, et al. Neurophysiological detection of impending spinal cord injury during scoliosis surgery. *J Bone Joint Surg Am*. 2007;89:2440-2449.
- Vitale MG, Skaggs DL, Pace GI, et al. Best practices in intraoperative neuromonitoring in spine deformity surgery: development of an intraoperative checklist to optimize response. *Spine Deform*. 2014;2:333-339.
- Lall RR, Lall RR, Hauptman JS, et al. Intraoperative neurophysiological monitoring in spine surgery: indications, efficacy, and role of the preoperative checklist. *Neurosurg Focus*. 2012;33:E10.
- Marino RJ, Barros T, Biering-Sorensen F, et al; ASIA Neurological Standards Committee 2002. International standards for neurological classification of spinal cord injury. *J Spinal Cord Med*. 2003;26(suppl 1):S50-S56.
- Yoshida G, Ando M, Imagama S, et al. Alert timing and corresponding intervention with intraoperative spinal cord monitoring for high risk spinal surgery [published online October 11, 2018]. *Spine (Phila Pa 1976)*. doi:10.1097/BRS.0000000000002900
- Jarvis JG, Strantzas S, Lipkus M, et al. Responding to neuromonitoring changes in 3-column posterior spinal osteotomies for rigid pediatric spinal deformities. *Spine (Phila Pa 1976)*. 2013; 38:E493-E503.
- Lewis SJ, Gray R, Holmes LM, et al. Neurophysiological changes in deformity correction of adolescent idiopathic scoliosis with intraoperative skull-femoral traction. *Spine (Phila Pa 1976)*. 2011;36:1627-1638.
- Yang J, Skaggs DL, Chan P, et al. Raising mean arterial pressure alone restores 20% of intraoperative neuromonitoring losses. *Spine (Phila Pa 1976)*. 2018;43:890-894.
- Catapano JS, John Hawryluk GW, Whetstone W, et al. Higher mean arterial pressure values correlate with neurologic improvement in patients with initially complete spinal cord injuries. *World Neurosurg*. 2016;96:72-79.
- Dakson A, Brandman D, Thibault-Halman G, Christie SD. Optimization of the mean arterial pressure and timing of surgical decompression in traumatic spinal cord injury: a retrospective study. *Spinal Cord*. 2017;55:1033-1038.
- Levi L, Wolf A, Belzberg H. Hemodynamic parameters in patients with acute cervical cord trauma: description, intervention, and prediction of outcome. *Neurosurgery*. 1993;33:1007-1017.
- Martin ND, Kepler C, Zubair M, Sayadipour A, Cohen M, Weinstein M. Increased mean arterial pressure goals after spinal cord injury and functional outcome. *J Emerg Trauma Shock*. 2015;8:94-98.
- Readdy WJ, Whetstone WD, Ferguson AR, et al. Complications and outcomes of vasopressor usage in acute traumatic central cord syndrome. *J Neurosurg Spine*. 2015;23:574-580.
- Saadeh YS, Smith BW, Joseph JR, et al. The impact of blood pressure management after spinal cord injury: a systematic review of the literature. *Neurosurg Focus*. 2017;43:E20.
- Vale FL, Burns J, Jackson AB, Hadley MN. Combined medical and surgical treatment after acute spinal cord injury: results of a prospective pilot study to assess the merits of aggressive medical resuscitation and blood pressure management. *J Neurosurg*. 1997; 87:239-246.
- Walters BC, Hadley MN, Hurlbert RJ, et al; American Association of Neurological Surgeons; Congress of Neurological Surgeons. Guidelines for the management of acute cervical spine and spinal cord injuries: 2013 update. *Neurosurgery*. 2013; 60(suppl 1):82-91.
- Wolf A, Levi L, Mirvis S, et al. Operative management of bilateral facet dislocation. *J Neurosurg*. 1991;75:883-890.
- Bible JE, Mirza M, Knaub MA. Blood-loss management in spine surgery. *J Am Acad Orthop Surg*. 2018;26:35-44.
- Hébert PC, Wells G, Blajchman MA, et al. A multicenter, randomized, controlled clinical trial of transfusion requirements in critical care. Transfusion requirements in Critical Care Investigators, Canadian Critical Care Trials Group. *N Engl J Med*. 1999;340: 409-417.
- Tse EY, Cheung WY, Ng KF, Luk KD. Reducing perioperative blood loss and allogeneic blood transfusion in patients undergoing major spine surgery. *J Bone Joint Surg Am*. 2011;93:1268-1277.
- Vaglio S, Prisco D, Biancofiore G, et al. Recommendations for the implementation of a Patient Blood Management programme. Application to elective major orthopaedic surgery in adults. *Blood Transfus*. 2016;14:23-65.
- Hawryluk G, Whetstone W, Saigal R, et al. Mean arterial blood pressure correlates with neurological recovery after human spinal cord injury: analysis of high frequency physiologic data. *J Neurotrauma*. 2015;32:1958-1967.
- Inoue T, Manley GT, Patel N, Whetstone WD. Medical and surgical management after spinal cord injury: vasopressor usage, early surgeries, and complications. *J Neurotrauma*. 2014;31: 284-291.
- Kepler CK, Schroeder GD, Martin ND, Vaccaro AR, Cohen M, Weinstein MS. The effect of preexisting hypertension on early neurologic results of patients with an acute spinal cord injury. *Spinal Cord*. 2015;53:763-766.