

Suprachoroidal Hemorrhage with Delayed Rebleeding as the First Presentation of Bullous Pemphigoid Associated Acquired Hemophilia

Anthony Kwan Ho Mak^{*}, Jennifer Wei Huen Shum, Bonnie Nga Kwan Choy, Alex Lap Ki Ng and Jimmy Shiu Ming Lai

Department of Ophthalmology, Grantham Hospital, 125 Wong Chuk Hang Road, Hong Kong SAR

^{*}Corresponding author: Anthony Kwan Ho Mak, Department of Ophthalmology, Grantham Hospital, 125 Wong Chuk Hang Road, Hong Kong SAR, Tel: +852 9477 3094; E-mail: dr.anthonymak.19@gmail.com

Received date: May 26, 2016; Accepted date: Jun 02, 2016; Published date: Jun 06, 2016

Copyright: © 2016 Mak AKH, et al. This is an open-access article distributed under the terms of the Creative Commons Attribution License, which permits unrestricted use, distribution, and reproduction in any medium, provided the original author and source are credited.

Abstract

We report a case of phacoemulsification conversion complicated by suprachoroidal haemorrhage (SCH) and delayed rebleeding at day 5 postoperation, as the first presentation of bullous pemphigoid associated acquired hemophilia. This association has been reported sparingly in the past, and almost exclusively only in hematology literature. To the best of our knowledge, this is the first case of delayed SCH rebleed presenting in a patient with previously undiagnosed Acquired Hemophilia reported. Although exceedingly rare, acquired hemophilia leads to drastic complications and has a high mortality rate. Advice to allow early recognition and prevention of complications is summarized.

Keywords: Suprachoroidal haemorrhage; Delayed rebleed; Acquired haemophilia; Phacoemulsification complication; Bullous pemphigoid association

Introduction

Suprachoroidal hemorrhage (SCH) is a rare but devastating complication of cataract surgery. We report a case of phacoemulsification conversion complicated by SCH and delayed rebleeding, as the first presentation of previously undiagnosed bullous pemphigoid associated acquired hemophilia. This association has been reported sparingly in the past, and almost exclusively only in hematology literature. To the best of our knowledge, this is the first case of delayed SCH rebleed presenting in a patient with previously undiagnosed Acquired Hemophilia reported.

Case Presentation

A 66-year-old Chinese man was electively admitted for phacoemulsification surgery and intraocular lens (IOL) insertion of the left eye. For past medical history, the patient suffered from bullous pemphigoid with mucosal involvement, hypertension, hyperlipidemia, and recurrent metachronous colorectal cancer with multiple resections. The patient has borderline renal function. He was not on any anticoagulants and there was no reported history of coagulation disorder.

He has known high myopia with a long axial length of 30.63mm in the operating eye (Axial length biometry A-Scan, Eyecubed[™], Ellex). Autorefractometer was -19.25 over the right eye and the machine failed to obtain a reading in the left eye. His pre-operative best-corrected visual acuity (BCVA) was 20/100 in both eyes. Slit lamp examination revealed dense nuclear sclerosis of grade IV in both eyes.

A peri-bulbar block was performed with an injection of 2% lignocaine mixed with hyaluronidase before the start of surgery. Paracentesis and a 2.75 mm superior corneal wound were made, followed by continuous curvilinear capsulorhexis (CCC), which was

halted by a run-away at 5 o'clock position. The operation was converted to extracapsular cataract extraction. After removal of the anterior capsule, relaxing incisions were made at the superior CCC rim. Corneal wound extension, nucleus expression and cortex removal with irrigation and aspiration were completed uneventfully. The lens capsule was inflated with viscoelastic, and the anterior capsular rim could still be visualized.

An EZE60 IOL (Bausch & Lomb) was inserted, which was complicated by a posterior capsular rupture (PCR). Loss of vitreous was noted and the IOL was removed. At this point, the patient complained of urinary urgency, followed by severe ocular pain. Loss of red reflex was noted, with further anterior displacement of vitreous and mild iris prolapse. With the suspicion of suprachoroidal hemorrhage (SCH) in mind, viscoelastic was injected to arrest further protrusion of intraocular contents, followed by immediate wound closure with 10-0 nylon sutures. The anterior chamber (AC) was well formed after successful wound closure. Limited anterior vitrectomy was performed and no vitreous or retinal incarceration in wound was noted at the end of operation. Intra-cameral Zinacef was injected at the end of the operation and IOP was maintained at around mid-20 mmHg. On binocular indirect ophthalmoscopy immediately post-operation, there was loss of red reflex and a superior ciliary body bulge was seen behind iris.

On postoperative day, visual acuity of the left eye was hand motion only and the left eye intraocular pressure (IOP) was 19. Slit lamp examination showed stable wounds with negative Seidel test, significant injection with chemosis, corneal edema, descemet membrane folds, a well formed anterior chamber with vitreous at the pupillary plane and a superior ciliary body bulge behind the superior pupil plane.

B-scan (Figure 1) confirmed superior and inferior suprachoroidal hemorrhage without significant central choroidal apposition. Post-operative treatment included: 1% Prednisolone Forte (prednisolone acetate ophthalmic suspension, USP) and 0.5% Cravit (Levofloxacin) eye drops given hourly during daytime; 10 mg of oral prednisolone; and maximal anti-glaucoma medications including oral acetazolamide

250 mg twice daily, topical 0.5% timolol, 0.1% alphagan-P (Brimonidine Tartrate) and 1% azopt (brinzolamide ophthalmic suspension). The intraocular pressure was kept within mid to late teens over the first 4 days.

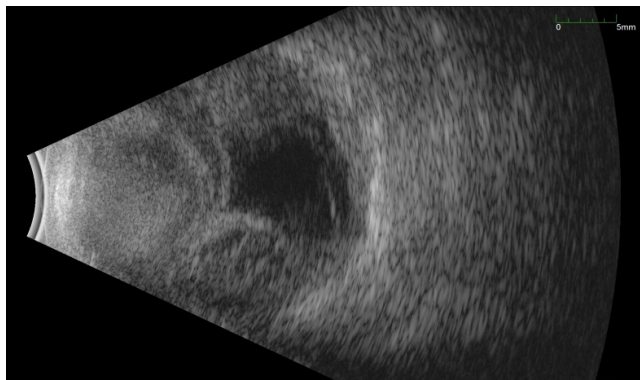


Figure 1: B-scan: Suprachoroidal haemorrhage.

On postoperative day 5, the patient did not complain of any pain but the intraocular pressure suddenly increased to 43 mmHg. Left eye reverse relative afferent pupillary defect was positive. There was increase in chemosis. The wounds remained stable but the anterior chamber became shallow. A repeat B-scan showed an increase in size of SCH, now with kissing choroidal.

In view of the rarity of a rebleed on postoperative day 5 in the context of stable wounds, the patient was asked about history of bleeding tendencies. The patient revealed that he suffered from a spontaneous lip hematoma 6 months prior to this admission, and had been experiencing significant bruising after routine blood tests over the same time period. Blood tests for complete blood count and clotting were taken. Immediately after venesection, the patient developed continuous oozing from the puncture site, which required prolonged pressure compression, and ultimately resulted in extensive swelling over the left anterior cubital fossa (Figure 2).

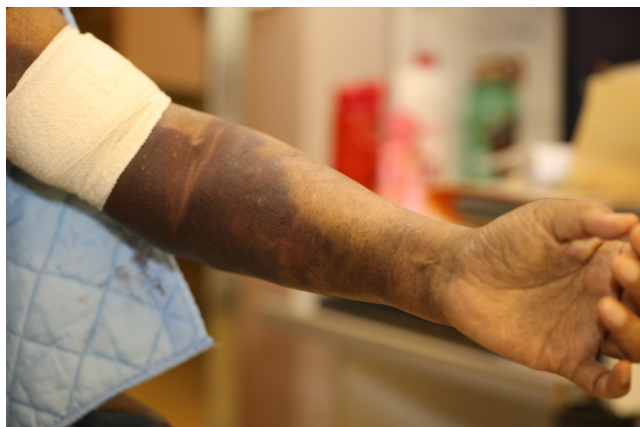

Figure 2: Hematoma of left anterior cubital fossa, after blood taking.

Blood tests revealed a hemoglobin level of 7.8 g/dL (normal range 13.8-18.0), prolonged activated partial thromboplastin time (APTT) of

64 seconds (normal range: 23-35 seconds), with a normal Prothrombin time (PT) of 12.9 (normal range: 9.5-13.5) and a normal International normalized ratio of 1.1 (normal range 0.8-1.2). These results were suggestive of an acquired coagulation disorder.

Urgent referral to the hematologist and further blood tests were done to establish a definitive diagnosis. The Factor VIII level of the patient was <0.01 IU/ml (reference range: 0.5-1.75 IU/ml), Factor VIII inhibitor was 57.3 Bethesda Unit (normal range: <10), which lead to the diagnosis of Acquired Hemophilia.

He was treated with 5 mg of NovoSeven (recombinant human coagulation Factor VIIa) injections pro re nata during acute bleeding episodes post-venesection. A total of 15 NovoSeven injections were given over the course of his admission. Four units of blood transfusions were given to normalize hemoglobin levels. Oral prednisolone 60 mg and Cyclophosphamide 50 mg daily were initiated. The APTT remained high but showed a decreasing trend, reducing to 46.7 after one week of treatment.

His chemosis resolved quickly after commencement of oral steroids and NovoSeven (Figure 3), and the IOP gradually returned to normal. At 16 days postoperation, the patient was noted to develop early band keratopathy. At postoperation day 12, the visual acuity was reduced to no light perception (NLP). In view of poor visual prognosis and significant bleeding risk, surgical drainage was not recommended.

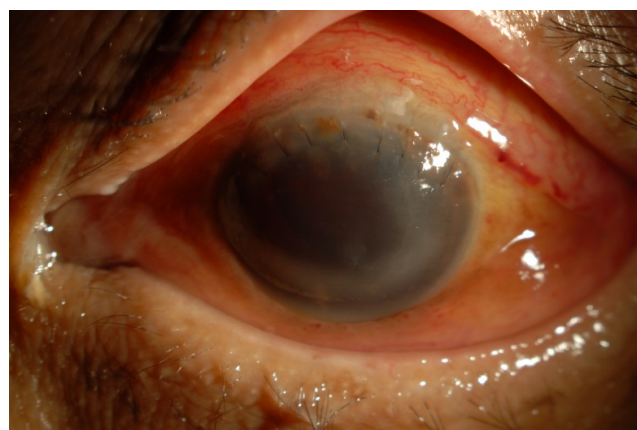

Figure 3: Postoperative day 12-Chemosis resolved.

Discussion

Acquired hemophilia (AH) is an exceedingly rare condition, with an incidence of approximately 1.5 persons per million each year [1] and a mortality rate of 9-22% [2]. The condition is caused by spontaneous development of inhibitory autoantibodies against endogenous coagulation factors in individuals with no previous history of bleeding disorders [2]. All coagulation factors have been implicated, with the most commonly affected one being Factor VIII [3,4]. Approximately 50% of cases are idiopathic; 12-18% is associated with autoimmune diseases-the most common ones being systemic lupus erythematosus, rheumatoid arthritis and Sjögren's syndrome [5-8]. The rest of AH cases are associated with malignancies, pregnancy, infections, adverse drug reactions and dermatological conditions. According to our literature review, only 17 documented cases of bullous pemphigoid (BP) associated AH have been reported hitherto. Presenting symptoms

of BP associated AH include hematomas, ecchymosis, gastrointestinal bleeding and oral mucosal bleeding. This was compatible with the history of lip hematoma in our patient [9-19].

To the best of our knowledge, there has been no previous report of SCH in patients suffering from AH, although there was one case report of uncontrolled bleeding following eyelid tumor resection in a patient with previously undiagnosed AH [20]. A few cases of ocular bleeding associated with Congenital Hemophilia have been reported, with delayed bleeding as a recurrent feature [21-24]. Delayed, uncontrolled or otherwise suspicious bleeding should raise the suspicion of coagulopathies.

The goal of treatment in AH is twofold: to achieve hemostasis in acute bleeding episodes, and to eradicate coagulation inhibitors to prevent life-threatening haemorrhage [25,26]. In our case, recombinant Factor VIIa (NovoSeven) was used to achieve temporary hemostasis. It was effective, albeit short-acting, in controlling the continuous oozing from needle puncture sites. To achieve complete remission of AH, data from the European Acquired Hemophilia Registry has shown that the combination of Cyclophosphamide and steroids is the most effective regime, compared with steroids alone or steroids with Rituximab [27].

SCH can be classified into postoperative and spontaneous. The incidence of SCH complicating phacoemulsification and ECCE is 0.03% and 0.13% respectively [28,29]. Risk factors for postoperative SCH include high myopia, glaucoma, diabetes, hypertension and atherosclerosis. Intraoperative risk factors include PCR (52.3% of SCH cases), ECCE, and phacoemulsification conversion [30]. A study auditing 55,567 cataract operations concluded that anti-coagulant use was not associated with an increased risk [31]. The risk factors for spontaneous SCH are almost identical to postoperative SCH, with the exception of anti-coagulant use. A meta-analysis showed that abnormal coagulopathy and the use of anti-coagulants were both major risk factors in spontaneous SCH in patients aged over 60, associated with 82.6% and 69.6% of the cases respectively [32]. With regards to use of warfarin, spontaneous SCH can occur when the INR is within or over therapeutic range [33,34].

Management of SCH is controversial, with different sources of evidence-based arguments supporting both conservative and surgical treatment) [35,36]. Intraoperative steps taken to manage SCH include from wound closure alone, intravenous mannitol, intravenous Diamox, anterior vitrectomy and trans-scleral drainage of suprachoroidal blood [37]. There is, however, a general consensus that immediate drainage of SCH is difficult and potentially detrimental [38,39]. One large case series of patients with SCH showed that there is no statistically significant difference in visual outcome between conservative and surgical management [40]. In contrast, a more recent case report of 4 patients with massive SCH who underwent surgical intervention showed promising results [41]. The procedure entailed trans-scleral suprachoroidal drainage, pars plana vitrectomy, use of perfluorocarbon liquid to displace the hemorrhage from the posterior pole and silicone oil tamponade. All 4 patients had a pre-operative visual acuity of light perception, but had variable postoperative visual acuity of 20/20, 20/320, hand motion and no light perception.

Poorer visual outcome has been shown to be significantly correlated with the severity of SCH. Features associated with poorer outcomes include central retinal apposition, and vitreous or retinal incarceration in the wound [42]. Our patient developed central retinal apposition after SCH rebleed on postoperation day 5. This feature has generally

been regarded as a relative indication for surgical intervention, [40,43] although one case report has shown visual acuity improvement from hand motion to 20/50 by conservative management alone [44].

The mean SCH clot lysis time has been shown to be around 2 weeks via ultrasonography, and thus, the traditional school of thought is to delay drainage by 1 to 2 weeks [36,45-47]. Multiple reports have observed that the time interval for intervention should not exceed two weeks [38,40,41]. During the optimum surgical window of 7 to 14 days, our patient had prolonged APTT and continued to suffer from uncontrolled bleeding from simple venesection. In view of this increased risk of bleeding and poor visual potential, secondary drainage was not pursued. Unfortunately, our patient had central retinal apposition which persisted for over 2 weeks postoperatively, with no signs of clot lysis on ultrasonography. This is generally associated with dismal visual outcome, regardless of the type of management [40].

Whilst it is not practical to perform blood tests on every patient undergoing cataract surgery to screen for rare bleeding disorders such as AH, this case highlights the importance of further history taking in those who are at high risk for developing SCH, e.g. to ask about history of spontaneous bleeding, easy bruising or prolonged bleeding episodes. Patients with any suspicion of a bleeding disorder should then be further worked up with clotting blood tests. Cases of SCH with delayed postoperative rebleeding should raise suspicion of a bleeding disorder, especially if there is no history of anticoagulant use. Urgent coagulation blood tests and timely referral to a hematologist could prevent life-threatening hemorrhagic death in those with acquired hemophilia.

Acknowledgements

This paper has not been presented at any meeting. This paper has not received any financial support. The authors have no financial or proprietary interest to disclose.

References

1. Collins P, Macartney N, Davies R, Lees S, Giddings J, et al. (2004) A population based, unselected, consecutive cohort of patients with acquired haemophilia A. *Br J Haematol* 124: 86-90.
2. Collins P, Baudo F, Huth-Kühne A, Ingerslev J, Kessler CM, et al. (2010) Consensus recommendations for the diagnosis and treatment of acquired hemophilia A. *BMC Res Notes* 3: 161.
3. Franchini M, Lippi G, Favaloro EJ (2012) Acquired inhibitors of coagulation factors: part II. *Semin Thromb Hemost* 38: 447-453.
4. Coppola A, Favaloro EJ, Tufano A, Di Minno MN, Cerbone AM, et al. (2012) Acquired inhibitors of coagulation factors: part I-acquired hemophilia A. *Semin Thromb Hemost* 38: 433-446.
5. Knoebl P, Marco P, Baudo F, Collins P, Huth-Kühne A, et al. (2012) Demographic and clinical data in acquired hemophilia A: results from the European Acquired Haemophilia Registry (EACH2). *J Thromb Haemost* 10: 622-631.
6. Green D, Lechner K (1981) A survey of 215 non-hemophilic patients with inhibitors to Factor VIII. *Thromb Haemost* 45: 200-203.
7. Morrison AE, Ludlam CA, Kessler C (1993) Use of porcine factor VIII in the treatment of patients with acquired hemophilia. *Blood* 81: 1513-1520.
8. Söhngen D, Specker C, Bach D, Kuntz BM, Burk M, et al. (1997) Acquired factor VIII inhibitors in nonhemophilic patients. *Ann Hematol* 74: 89-93.
9. Makita S, Aoki T, Watarai A, Aida A, Katayama T, et al. (2013) Acquired hemophilia associated with autoimmune bullous diseases: a report of two cases and a review of the literature. *Intern Med* 52: 807-810.

10. Ammannagari N, Kathleen L, Sara G (2013) Acquired Hemophilia in the Setting of Bullous Pemphigoid: A Case Report. *J Hematol* 2: 74-75.
11. Zhang X, Guo J, Guo X, Pan J (2012) Successful treatment of acquired haemophilia in a patient with Bullous pemphigoid with single-dosing regimen of rituximab. *Haemophilia* 18: e393-395.
12. Gupta S, Mahipal A (2007) A case of acquired hemophilia associated with bullous pemphigoid. *Am J Hematol* 82: 502.
13. Chen CY CY, Ho JC, Wu CS (2010) Bullous pemphigoid associated with acquired hemophilia. *Dermatologica Sinica* 28:173-176.
14. Nguyen CGJ, Chang ALS (2012) A Little Known but Potentially Life-threatening Association of Bullous Pemphigoid and Acquired Hemophilia: Case Report and Review of the Literature. *J Clin Exp Dermatol Res* 6:003.
15. Aljasser MI, Sladden C, Crawford RI, Au S (2014) Bullous pemphigoid associated with acquired hemophilia a: a rare association of autoimmune disease. *J Cutan Med Surg* 18: 123-126.
16. Patel RS, Harman KE, Nichols C, Burd RM, Pavord S (2006) Acquired haemophilia heralded by bleeding into the oral mucosa in a patient with bullous pemphigoid, rheumatoid arthritis, and vitiligo. *Postgrad Med J* 82: e3.
17. Qiu X, Zhang G, Xiao R, Zhang J, Zhou Y, et al. (2012) Acquired hemophilia associated with bullous pemphigoid: a case report. *Int J Clin Exp Pathol* 5: 102-104.
18. Soria A, Matichard E, Descamps V, Crickx B (2007) [Bullous pemphigoid and acquired hemophilia]. *Ann Dermatol Venereol* 134: 353-356.
19. Lightburn E, Morand JJ, Graffin B, Molinier S, Raphenon G, et al. (2001) [Pemphigoid and acquired hemophilia]. *Ann Dermatol Venereol* 128: 1229-1231.
20. Mormile S, Marbet GA, Haefliger IO (2008) Unexpected bleeding following eyelid tumor resection leading to the rare diagnosis of acquired haemophilia. *Klin Monbl Augenheilkd.* 225: 424-426.
21. Guirgis ME, Segal WA, Lueder GT (2002) Subperiosteal orbital hemorrhage as initial manifestation of Christmas disease (factor IX deficiency). *Am J Ophthalmol* 133: 584-585.
22. Oh JY, Khwarg SI (2004) Orbital subperiosteal hemorrhage in a patient with factor VIII and factor XII Deficiency. *J Pediatr Ophthalmol Strabismus* 41: 367-368.
23. Wang TY, Horng CT, Cheng SN, Li CH, Chen JT, et al. (2008) Optic disc hemorrhages in a patient with hemophilia A. *Int J Hematol* 87: 550-552.
24. Maguluri S, Bueno CL, Fuller IB, Eagle RC Jr, Spell DW (2005) Delayed suprachoroidal hemorrhage and factor VIII deficiency. *Am J Ophthalmol* 139: 195-197.
25. W Collins P, Chalmers E, Hart D, Jennings I, Liesner R, et al. (2013) Diagnosis and management of acquired coagulation inhibitors: a guideline from UKHCDO. *Br J Haematol* 162: 758-773.
26. Huth-Kühne A, Baudo F, Collins P, Ingerslev J, Kessler CM, et al. (2009) International recommendations on the diagnosis and treatment of patients with acquired hemophilia A. *Haematologica* 94: 566-575.
27. Collins P, Baudo F, Knoebl P, Levesque H, Nemes L (2012) Immunosuppression for acquired hemophilia A: results from the European Acquired Haemophilia Registry (EACH2). *Blood* 120: 47-55.
28. Eriksson A, Koranyi G, Seregard S, Philipson B (1998) Risk of acute suprachoroidal hemorrhage with phacoemulsification. *J Cataract Refract Surg* 24: 793-800.
29. Obuchowska I, Mariak Z (2005) Risk factors of massive suprachoroidal hemorrhage during extracapsular cataract extraction surgery. *Eur J Ophthalmol.* 15: 712-717.
30. Ling R, Kamalarajah S, Cole M, James C, Shaw S (2004) Suprachoroidal haemorrhage complicating cataract surgery in the UK: a case control study of risk factors. *Br J Ophthalmol.* 88: 474-477.
31. Benzimra JD, Johnston RL, Jaycock P, Galloway PH, Lambert G, et al. (2009) The Cataract National Dataset electronic multicentre audit of 55,567 operations: antiplatelet and anticoagulant medications. *Eye (Lond).* 23: 10-16.
32. Hsiao SF SM, Huang FC (2014) Spontaneous suprachoroidal hemorrhage: Case report and review of the literature. *Taiwan Journal of Ophthalmology* 6: 36-41.
33. Chen YY, Chen YY, Sheu SJ (2009) Spontaneous suprachoroidal hemorrhage associated with age-related macular degeneration and anticoagulation therapy. *J Chin Med Assoc* 72: 385-387.
34. Haridas A, Litwin AS, Coker T (2011) Perioperative spontaneous bilateral suprachoroidal hemorrhage. *Digit J Ophthalmol* 17: 9-11.
35. Reynolds MG, Haimovici R, Flynn HW Jr, DiBernardo C, Byrne SF, et al. (1993) Suprachoroidal hemorrhage. Clinical features and results of secondary surgical management. *Ophthalmology* 100: 460-465.
36. Chu TG, Green RL (1999) Suprachoroidal hemorrhage. *Surv Ophthalmol* 43: 471-486.
37. Beatty S, Lotery A, Kent D, O'Driscoll A, Kilmartin DJ, et al. (1998) Acute intraoperative suprachoroidal haemorrhage in ocular surgery. *Eye (Lond)* 12: 815-820.
38. Lakhnpal V (1993) Experimental and clinical observations on massive suprachoroidal hemorrhage. *Trans Am Ophthalmol Soc* 91: 545-652.
39. Chandra A WT (2014) Surgical Management of Suprachoroidal Hemorrhage. *Retinal Physician* 11: 65-69.
40. Scott IU, Flynn HW Jr, Schiffman J, Smiddy WE, Murray TG, et al. (1997) Visual acuity outcomes among patients with appositional suprachoroidal hemorrhage *Ophthalmology* 104: 2039-2046.
41. Laube T BC, Bornfeld N (2015) Massive suprachoroidal hemorrhage: Surgical management and outcome. *GMS Ophthalmol Cases.* 5: 10.
42. Wiroszko WJ, Han DP, Mieler WF, Pulido JS, Connor TB Jr, et al. (1998) Suprachoroidal hemorrhage: outcome of surgical management according to hemorrhage severity. *Ophthalmology.* 105: 2271-2275.
43. Meier P, Wiedemann P (2000) Massive suprachoroidal hemorrhage: secondary treatment and outcome. *Graefes Arch Clin Exp Ophthalmol* 238: 28-32.
44. Lee SJ, Lee JH, Park SW, Kim M, Han SB (2015) Spontaneous resolution of massive expulsive suprachoroidal hemorrhage with good long-term visual outcome: a case report. *Int Med Case Rep J* 8: 185-187.
45. Lakhnpal V, Schocket SS, Elman MJ, Nirankari VS (1989) A new modified vitreoretinal surgical approach in the management of massive suprachoroidal hemorrhage. *Ophthalmology.* 96: 793-800.
46. Lambrou FH Jr, Meredith TA, Kaplan HJ (1987) Secondary surgical management of expulsive choroidal hemorrhage. *Arch Ophthalmol* 105: 1195-1198.
47. Welch JC, Spaeth GL, Benson WE (1988) Massive suprachoroidal hemorrhage. Follow-up and outcome of 30 cases. *Ophthalmology* 95: 1202-1206.