

CASE REPORT

in Renal Failure

# Transcatheter Leadless Cardiac Pacing with Limited Venous Access

CHU-PAK LAU, M.D., F.H.R.S.\*,<sup>†</sup> and KATHY LAI-FUN LEE, M.B.B.S., F.A.C.C.\*

From the \*Cardiology Division, Department of Medicine, Queen Mary Hospital, the University of Hong Kong, Hong Kong SAR, China; and <sup>†</sup>Research Center of Heart, Brain, Hormone and Healthy Ageing, Li Ka Shing Faculty of Medicine, the University of Hong Kong, Hong Kong SAR, China

*Entirely leadless cardiac pacemakers that are delivered transvenously required the use of large diameter delivery sheath and femoral venous approach. The complexity of external femoral and iliac venous anatomy may limit their implantation. We describe a patient without subclavian venous access and a conventional pacemaker with a failed right ventricular lead, which was also compressed by an external endovascular abdominal aortic aneurysm. Implantation of a Micra™ (Medtronic Inc) was accomplished with a strong support wire that was guided by venography. (PACE 2016; 00:1–4)*

**leadless cardiac pacing, heart block, aortic stent graft**

## Introduction

Transcatheter deployed entirely leadless cardiac pacemaker (LPM) avoids the complications associated with pacing leads and pacemaker pockets.<sup>1,2</sup> Current LPMs require large diameter sheaths that are introduced through the femoral veins. There is limited information on the implantation of LPM in patients with difficult venous anatomy.

## Patient and Method

An 81-year-old woman with atrial fibrillation and complete heart block had a DDDR pacemaker implanted over her left infraclavicular area 10 years ago. She had chronic renal failure for 7 years, and hemodialysis (HD) using arteriovenous fistulae on either arm, right subclavian and right internal jugular veins failed because of tortuosity and repeated infection. She was finally dialysed from a right femoral HD catheter. In 2010, she developed a leaking infrarenal abdominal aortic aneurysm and underwent an emergency endovascular repair with aortic stent graft (EVAR: Enduran 26/13/145 + 16/24/80R and 16/24/120L) in the lower abdominal aorta straddling into the two common iliac arteries. At the time of pacemaker replacement in 2012, the ventricular

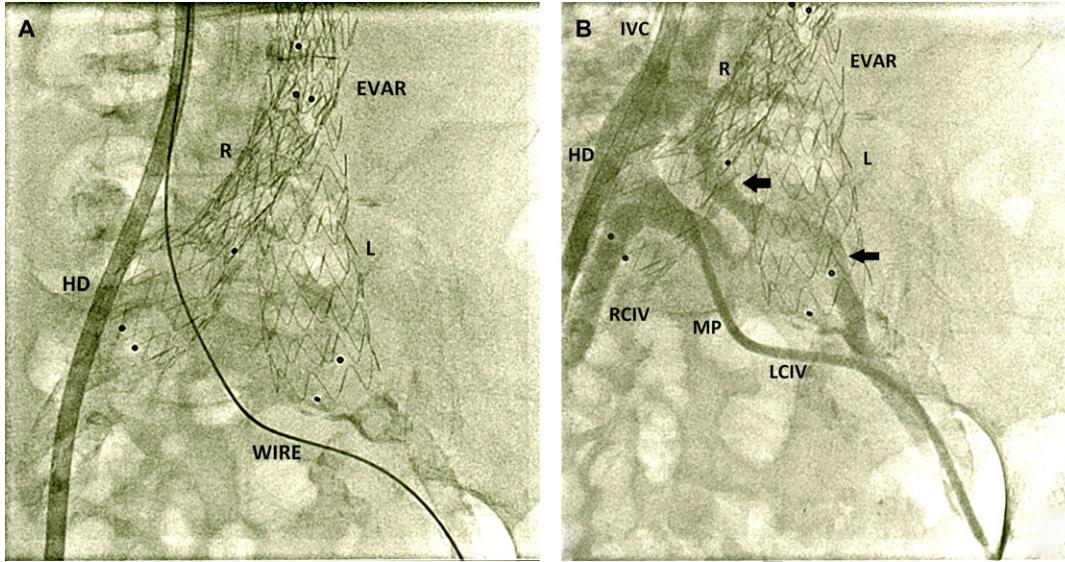
lead had a threshold of 4 V at 0.4 ms. An attempt to introduce a new ventricular lead failed and a Boston Scientific Altrua™ was implanted using the original high threshold ventricular lead. The device was programmed at 6.5 mV at 0.9 ms and its battery became depleted in 2015. Lead extraction or an epicardial lead placement was declined both because of patient preference. A decision was made to use an LPM for permanent pacing.

Implantation of a subcutaneous purse string pacemaker through the common femoral venous site, the common femoral vein was punctured and a stiff support wire was inserted and placed at the level of the right atrium. The support wire had a tortuous course through the common iliac vein (LCIV) and a hydrophilic sheath and dilator failed to track across (Fig. 1A). A hand injection cine-angiogram was then performed with multipurpose catheter tracked over this wire. The injection showed that the whole LCIV was severely compressed by the right and left iliac extensions of EVAR, and that the multipurpose catheter was in the lower tortuous patent channel (Fig. 1B). The wire was, therefore, repositioned to the straighter patent upper channel. The sheath and dilator was then tracked over the wire but was caught between the left and right common iliac extensions of the EVAR stent in front, and the pelvic bone behind. Using a series of progressively larger dilators, the venous passage was dilated up to 27F size. With gentle but sustained pushing and pulling on the support wire (push and pull technique), the venous sheath and dilator finally achieved a right atrial position, and crossed the tricuspid valve without problem or interference

Address for reprints: Chu-Pak Lau, M.D., F.H.R.S., Cardiac Health Heart Centre, The University of Hong Kong, Suite 1303, Central Building, 1 Pedder Street, Central, Hong Kong. Fax: 852-21795114; e-mail: cplau@hkucc.hku.hk

Received February 2, 2016; revised May 3, 2016; accepted May 17, 2016.

doi: 10.1111/pace.12895



**Figure 1.** (A) Cine-angiogram in the anteroposterior view of the pelvis showing the placement of a support wire from the left femoral vein, through the left common iliac vein (LCIV) into the inferior vena cava. Shown also are the endovascular aortic repair stent graft (EVAR) with its right (R) and left iliac (L) extensions. The Micra™ deployment sheath could not track over the wire because of venous tortuosity. (B) Hand-injection cine-angiogram in the same position using a 5F MP catheter in the LCIV tracked over the support wire. The LCIV was severely compressed by the MP catheter, which was opacified with this injection, with its entry into the right common iliac vein (RCIV) and reflux of contrast to the inferior vena cava (IVC). An upper channel of the LCIV has a straighter course (arrows), and the Micra™ deployment sheath was successfully tracked over the support wire subsequently placed in this channel.

by the right ventricular lead. A Medtronic Micra™ TCP was implanted in the right ventricle from the sheath identified to minimize the risk of lead fracture. There was no mechanical interference with the implanted right ventricular lead. A threshold of 0.88 V at 0.24 ms was achieved. The post procedure chest radiograph is shown in Figure 2.

**Discussion**

Current LPMs are relatively large in diameter, and require large diameter delivery sheaths for transcatheter deployment (21F in St. Jude Medical LCP™ and 27F in Medtronic Micra™ TCP). These devices are implanted in a femoral

venous approach. Because the right common iliac artery crosses in front of the LCIV, the vein is naturally compressed and in some patients venous drainage of the left leg may be compromised (May-Thurner syndrome).<sup>3</sup> In this case, the venous passage for the delivery sheath is compressed even further by the rigid EVAR metal stent in both the left and right common iliac arteries. A right femoral venous approach should be easier as the vein is not compressed in front, but is not possible in this patient due to an indwelling HD catheter. By choosing the less obstructed upper venous channel in the LCIV, and using sequentially upsized venous dilators, a stiff support wire, and push and pull technique, the slippery hydrophilic sheath and dilator was successfully passed across the compressed LCIV into the superior vena cava.

We did not find difficulty in physical interference of the delivery catheter and the indwelling ventricular lead across the tricuspid valve. Passage across the tricuspid valve is facilitated by deflectable sheath. With careful positioning and contrast injection, there is no physical interference between the implanted right ventricular lead or the LPM. In a cadaveric study,<sup>4</sup> 3 Micra™ TCPs were implanted in the right ventricle with no physical interference.

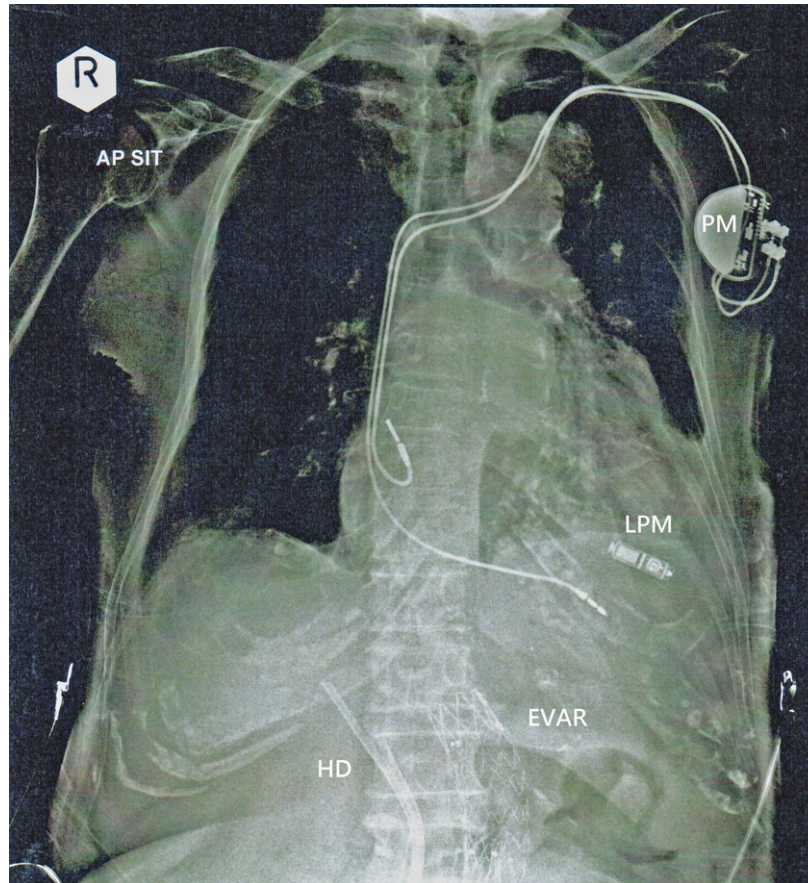
COLOUR ONLINE, B&W IN PRINT

1  
2  
3  
4  
5  
6  
7  
8  
9  
17  
18  
19  
20  
21  
22  
23  
24  
25  
26  
27  
28  
29  
30  
31  
32  
33  
34  
35  
36  
37  
38  
39  
40  
41  
42  
43  
44  
45  
46  
47  
48  
49  
50  
51  
52  
53  
54  
55  
56  
57  
58  
59  
60

Leadless cardiac pacemaker (LCP™)

TPS

TPS



**Figure 2.** Chest and upper abdomen x-ray showing four implanted devices. EVAR = endovascular aortic repair stent graft; HD = hemodialysis catheter; LPM = leadless cardiac pacemaker; PM = conventional permanent pacemaker.

Patients with ESRF also have increased bleeding and infection risks with pacemaker implantation. Thus our

There was no physical or electrical interference in our patient both during supine or standing when she was ambulant. An implanted pacemaker is an exclusion criteria in the published Micra™ TCP. However, this patient demonstrates that avoid multiple ventricular leads across the tricuspid valve in patients whose right ventricular lead has failed and who are not candidates for lead extraction. Upper limb venography may still review patent subclavian veins and enable a repeat transvenous pacing. However, our patient, with her multiple venous failures was reluctant to any further approach from the upper chest. Indeed, LPM has been reported as an alternative to conventional pacing in a patient with recurrent pocket infection of both sides of the chest, using the St. Jude Medical LCP™ LPM.<sup>5</sup> In another case, Micra™ TCP was used in a patient with persistent left superior vena cava and right subclavian vein that drained to the

abnormal superior vena cava system was infected.<sup>6</sup> Our patient with multiple comorbidities and requiring anticoagulation made leadless pacing a good alternative.<sup>7</sup>

### Conclusion

The case exemplifies the following. (1) Implantation of LPM is an alternative in patients who do not have subclavian venous access for permanent VVI pacemaker. (2) Contrast venography is useful to identify the best site for the LPM, and for its placement in the right ventricle. (3) In patients with large bore catheters requiring removal, LPM may be difficult to implant. Downsizing of LPM and delivery sheath and catheters will be useful, and (4) LPM is an option to avoid multiple right ventricular leads across the tricuspid valve in case of right ventricular lead failure.

VVI pacemaker, such as in ESRF patients.

1  
2  
3  
4  
5  
6  
7  
8  
9  
10  
11  
12  
13  
14  
15  
16  
17  
18  
19  
20  
21  
22  
23  
24  
25  
26  
27  
28  
29  
30  
31  
32  
33  
34  
35  
36  
37  
38  
39  
40  
41  
42  
43  
44  
45  
46  
47  
48  
49  
50  
51  
52  
53  
54  
55  
56  
57  
58  
59  
60

4. Omdahl P, Eggen MD, Bonner MD, laizzo PA, Wika K. Right Ventricular Anatomy Can Accommodate Multiple Micra Transcatheter Pacemakers. Pacing Clin Electrophysiol. 2016;39:393-7.

**References**

1. Reddy VY, Exner DV, Cantillon DJ, Doshi R, Bunch TJ, Tomasson Friedman PA, et al. LEADLESS II Study Investigators. Percutaneous implantation of an entirely intracardiac leadless pacemaker. N Engl J Med 2015; 373:1125–1135.  
2. Reynolds D, Duray GZ, Omar R, Soejima K, Neuzil P, Zhang S, Narasimhan C, et al. Micra Transcatheter Pacing Study Group. A leadless intracardiac transcatheter pacing system. N Engl J Med 2015; ~~373:1125–1135~~.  
3. May R, Thurner occurrence of thro

Q4

2. Reynolds D, Duray GZ, Omar R, Soejima K, Neuzil P, Zhang S, Narasimhan C, et al. Micra Transcatheter Pacing Study Group. A Leadless Intracardiac Transcatheter Pacing System. N Engl J Med. 2016 Feb 11;374(6):533-41.

42804].  
5. Tjong FV, Kooiman KM, de Groot JR, Knops RE. A leadless solution. Europace 2015; 17:800.  
6. Garweg C, Ector J, Willems R. Leadless cardiac pacemaker as alternative in case of congenital vascular abnormality and pocket infection. Europace 2016. (pii: euw023).  
7. Fisher JD. Leadless pacemakers. Pacing Clin Electrophysiol

Q5

First published online 18 Feb 2016

UNCORRECTED PROOF