



Comparing accuracy of obstetric sonography and fetal echocardiography during paediatric cardiology consultation in prenatal diagnosis of congenital heart disease



瑪麗醫院
QUEEN MARY HOSPITAL

Carman W.S. Lai¹, Adolphus KT Chau², C.P. Lee¹

¹ Department of Obstetrics and Gynaecology, the University of Hong Kong, Queen Mary Hospital, Hong Kong SAR, China.

² Department of Paediatric Cardiology, the University of Hong Kong, Queen Mary Hospital, Hong Kong SAR, China.

Objective: Compare the diagnostic accuracy of fetal echocardiogram performed by obstetrician alone and that performed jointly by obstetrician and paediatric cardiologist for congenital heart disease.

Method: All cases of suspected fetal congenital heart disease referred to Prenatal Diagnostic Clinic in Tsan Yuk Hospital, Hong Kong during the period 2006 to 2011 were reviewed. Prenatal fetal echocardiogram findings were compared with postnatal diagnosis. Cases of incorrect prenatal diagnosis with significant difference in prognosis were analyzed qualitatively. For simplicity of terminology, “obstetric sonography” refers to fetal echocardiogram performed by obstetricians and “fetal echocardiography” refers to fetal echocardiogram performed during joint consultation with paediatric cardiologists in this article.

Results: 111 cases of fetal congenital heart disease were analyzed. Complete agreement between prenatal and postnatal diagnosis of congenital heart disease was seen in 69.4% by fetal echocardiogram performed by obstetrician and 83.8% by fetal echocardiogram performed during paediatric cardiology consultation ($p=0.001$). Collaboration with paediatric cardiologist also improved detection of ductal-dependent cardiac lesions (77.4% vs 86%, $p<0.001$). There were five cases with incorrect diagnosis associated with different prognosis. Three of the cases involved outflow tract abnormalities with incorrect identification of outflow vessels.

A	Total match between prenatal and postnatal diagnosis
B	Correct diagnosis, with additional abnormality found in postnatal examination
C	Correct diagnosis, with difference in severity of diagnosis
D	Incorrect diagnosis but not significant difference in prognosis
E	Incorrect diagnosis with significant difference in prognosis of lesions

Table 1.
Grading of accuracy of prenatal diagnosis

Comparing accuracy of obstetric sonography and joint consultation with paediatric cardiologist (all cases, n=111)

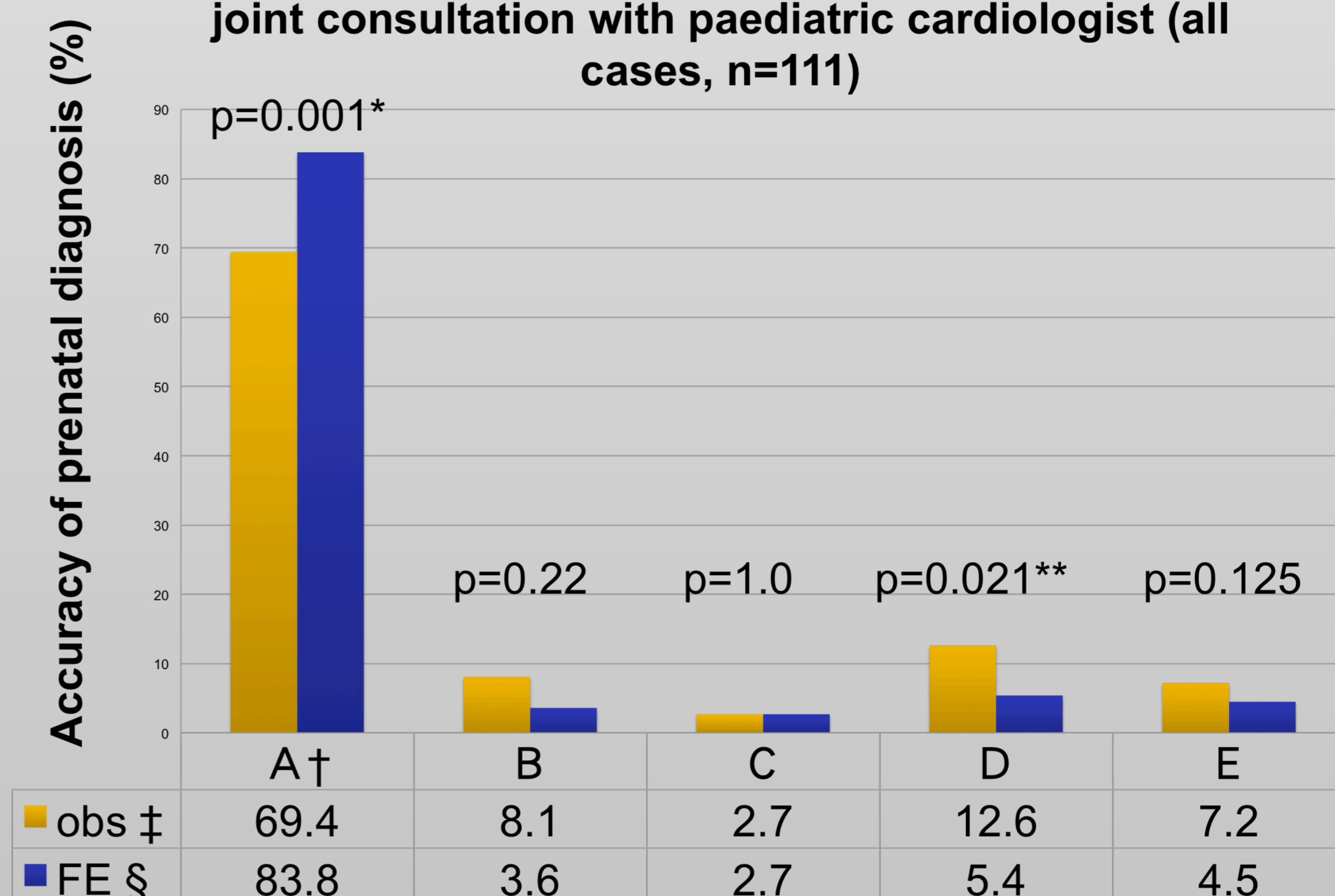


Figure 1

† A to E: grading of diagnostic accuracy as shown in table 1

‡ obs: obstetric sonography

§ FE: fetal echocardiography

Conclusion: Collaboration with paediatric cardiologist can significantly improve accuracy of prenatal diagnosis of congenital heart disease. In particular, joint consultation is associated with significantly better detection of ductal-dependent lesions. Outflow tract abnormalities remain a diagnostic challenge in prenatal diagnosis. Incorrect identification of outflow tract vessels is the major cause of incorrect diagnosis in our series. This illustrate importance of correct identification of outflow vessels during fetal echocardiography.