

Diabetic retinopathy screening: global and local perspective

Rita A Gangwani *, JX Lian, Sarah M McGhee, David Wong, Kenneth KW Li

ABSTRACT

Diabetes mellitus has become a global epidemic. It causes significant macrovascular complications such as coronary artery disease, peripheral artery disease, and stroke; as well as microvascular complications such as retinopathy, nephropathy, and neuropathy. Diabetic retinopathy is known to be the leading cause of blindness in the working-age population and may be asymptomatic until vision loss occurs. Screening for diabetic retinopathy has been shown to reduce blindness by timely detection and effective laser treatment. Diabetic retinopathy screening is being done worldwide either as a national screening programme or hospital-based project or as a community-based screening programme. In this article, we review different methods of screening including grading used to detect the severity of sight-threatening retinopathy and the newer screening methods. This review also includes the method of systematic screening being carried out in Hong Kong, a system that has helped to identify diabetic

retinopathy among all attendees in public primary care clinics using a Hong Kong-wide public patients' database.

Hong Kong Med J 2016;22:486–95

DOI: 10.12809/hkmj164844

¹ **RA Gangwani** *, FRCS (Edin), FHKAM (Ophthalmology)

¹ **JX Lian**, MPH, PhD

² **SM McGhee**, PhD, FFPH(UK)

^{1,3} **D Wong**, FRCOphth, FRCS

^{1,4} **KKW Li**, FRCS (Edin), FHKAM (Ophthalmology)

¹ Department of Ophthalmology, The University of Hong Kong, Pokfulam, Hong Kong

² School of Public Health, The University of Hong Kong, Pokfulam, Hong Kong

³ Royal Liverpool University, Liverpool, United Kingdom

⁴ Department of Ophthalmology, United Christian Hospital, Kwun Tong, Hong Kong

* Corresponding author: dr.rita_gangwani@hotmail.com

This article was published on 26 Aug 2016 at www.hkmj.org.

Introduction

Diabetes mellitus (DM) is becoming a global epidemic. In 2010, the World Health Organization (WHO) estimated that the global prevalence of DM is approximately 6.4% or 280 million people worldwide.¹ The figures from 2014 are even more alarming: approximately 347 million people globally are diagnosed to have DM.² Sedentary lifestyles, lack of physical activity, obesity, and lack of awareness have contributed to an increased prevalence of DM, particularly in developing countries.²

Diabetes mellitus is a chronic disease characterised by hyperglycaemia. Of the two types of DM, type 1 (insulin-dependent or juvenile type) is characterised by a total lack of insulin due to destruction of islets of Langerhans in the pancreas, due to an autoimmune process the cause of which may be unknown, and is not preventable with current knowledge.^{3,4} Type 2 DM, the more common type (non-insulin-dependent or adult-onset) characterised by resistance to the action of insulin and failure of insulin production, usually occurs due to excess body weight and lack of physical activity and is preventable.^{3,4}

Diabetes mellitus causes both macrovascular complications such as coronary artery disease, peripheral arterial disease, and stroke; and

microvascular complications such as diabetic nephropathy, neuropathy, and retinopathy.⁵ Diabetic retinopathy (DR) is one of the most common microvascular complications and one of the most common causes of blindness in populations of working age (20-70 years). While certain risk factors for DR, like the type and duration of DM, cannot be modified, control of other modifiable risk factors such as glycaemic control (haemoglobin A1c [HbA1c]), hypertension, and hyperlipidaemia is effective and essential to reduce DR-related blindness.⁶⁻⁹

Diabetic retinopathy consists of the early non-proliferative diabetic retinopathy (NPDR) stage, which can be mild, moderate, or severe; the advanced stage as proliferative DR (PDR); and maculopathy or diabetic macular oedema. Vision loss in DR occurs mainly due to macular oedema and PDR. Some studies consider PDR and diabetic macular oedema or diabetic maculopathy to be sight-threatening DR (STDR) while some other studies include moderate-to-severe NPDR additionally within the category of STDR. Blindness caused by DR is preventable. Since DR is usually asymptomatic, early detection and timely treatment are essential to prevent blindness.¹⁰⁻¹² The Diabetic Retinopathy Study and The Early Treatment Diabetic Retinopathy Study (ETDRS) showed the effectiveness of scatter laser

photocoagulation in patients with severe NPDR and PDR, and focal laser treatment in patients with diabetic macular oedema.¹⁰⁻¹² Diabetic macular oedema is associated with the breakdown of the blood-retinal barrier. Inflammation plays a significant role and is mediated by multiple cytokines including inflammatory cytokines and vascular endothelial growth factor (VEGF).¹³ Several clinical trials have demonstrated the effectiveness of anti-VEGF drugs (such as ranibizumab, bevacizumab, pegaptanib and aflibercept) in restoring the integrity of the blood-retinal barrier and effectively reducing diabetic macular oedema and improving vision.¹⁴

Blindness due to DR has important implications for the individual and is a huge socio-economic burden on the health care system and society.^{15,16} Although new treatments with anti-VEGF therapy for diabetic macular oedema and PDR can be very effective, they are very costly considering most people need maintenance treatment over some months and years.¹⁶ Additionally, chronic cases do not respond well to anti-VEGF therapy.

The WHO recommends that screening should be done for any condition that is an important health problem, has an effective treatment that can be delivered early, usually before symptoms of the condition are apparent, when facilities for diagnosis and treatment are available, when screening is feasible and cost-effective, and when subjects can be followed up longitudinally.¹⁷ Diabetic retinopathy fulfils most of these criteria and some studies have shown that screening can reduce the rate of blindness due to DR.^{18,19}

Since photocoagulation is effective to treat retinopathy and prevent blindness, it has been considered unethical to conduct a randomised controlled trial of screening versus no screening.²⁰ Therefore, few studies have examined the cost-effectiveness of screening for DR directly and most have used computer-based cost-effectiveness models to simulate the experience of cohorts of diabetic patients.^{20,21} Such studies have calculated the cost-effectiveness of screening and treatment in terms of cost per quality-adjusted life year gained, sight year saved, or case of blindness avoided.^{21,22} One study carried out in Hong Kong showed that systematic screening at no charge to the subject is more cost-effective from the societal perspective than screening with a small co-payment.²³

The important measures to prevent vision loss due to DR therefore include: (1) early detection of retinopathy by some form of screening, (2) subsequent monitoring of the condition with regular fundus examination, and (3) timely and effective laser treatment when deemed necessary.

Screening of DR is carried out at most places throughout the world, but there is no single recommended method that is suitable for every

糖尿病視網膜病變篩查：全球視野、本地情景

Rita A Gangwani、連金曉、Sarah M McGhee、
黃世雄、李啟煌

糖尿病經已發展成為全球性的流行病，它會導致如冠狀動脈病、外週動脈疾病和中風等的大血管疾病，以及如視網膜病、腎病和神經性疾病等小血管併發症。糖尿病視網膜病變是成人致盲的首要原因，而患者出現視力減退前可以沒有明顯病徵。糖尿病視網膜病變可以通過篩查及早發現並進行有效的激光治療以降低失明的機會。全球多個國家都透過全國篩查計劃，以醫院為基礎的篩查項目，或者以社區為基礎的篩選程序來進行糖尿病視網膜病變篩查。本文回顧不同的篩查方法，包括用於檢測威脅視力的視網膜病變的嚴重程度分級制，以及一些新的篩查方法。本文並探討香港正使用的一套篩查系統，利用全港基層醫療診所的病人資料庫來識別糖尿病視網膜病變患者。

country. The DR classification and grading method, particularly for STDR, has minor differences across different countries too. The aim of this paper was to review the methods of screening for DR from both a global and local perspective.

History of diabetic retinopathy screening

In 1989, the St Vincent Declaration in Europe aimed to reduce DM-related blindness by one third in 5 years.²⁴ The Diabetes 2000 programme of the American Academy of Ophthalmology (AAO) was implemented to promote screening and treatment for DR.²⁵ The English national screening programme (ENSP) started systematic DR screening in 2003 and aimed to reduce blindness by 40% within 5 years.^{26,27} Systematic screening means that every eligible person is contacted and offered screening regularly and every effort is made to screen the whole group at risk. This usually requires a register of all those with DM and the maintenance of active contact with them. In 2004, 15 years after the St Vincent Declaration, the Liverpool declaration aimed to reduce DR-related blindness further by ensuring that systematic screening reached at least 80% of the diabetic population in all European countries. As a result, there is now universal access to laser therapy in these countries.²⁸ In South-East Asia, Thailand has launched the new Thailand Healthy Lifestyle Strategy Plan (2011-2020) to decrease the prevalence, complications, and disability of five major non-communicable diseases including DM and is now introducing a mobile eye care project to enable people from rural communities to have access to DM screening.^{29,30}

In order to ensure standardisation and quality of DR screening, guidelines have been developed by national organisations such as the American

Diabetes Association (ADA), the AAO, and the ENSP, and many screening programmes are now being carried out worldwide.^{25,26,30,31}

Recommendations for diabetic retinopathy screening

According to ADA and AAO, adults and children of ≥ 10 years of age who had type 1 DM should have an initial and comprehensive eye examination by an ophthalmologist or optometrist within 5 years of the diagnosis. Similarly, type 2 DM patients should undergo DR screening within 5 years of the diagnosis. An initial comprehensive eye examination should include dilated fundal examination and follow-up examinations at least yearly thereafter.^{25,28,31} In the presence of any retinopathy (NPDR, PDR, or macular oedema), referral to an ophthalmologist is required and more frequent examinations are recommended. Pregnant women with pre-existing DM should undergo dilated fundus examination in the first trimester with close follow-up throughout pregnancy and for 1 year postpartum.²⁵ Women who develop gestational DM do not require an eye examination during pregnancy and are not at increased risk of developing DR during pregnancy.²⁵ Patients with mental and physical disability are not excluded from DR screening; ENSP has special provision for such groups.³²

Many of the current guidelines, such as AAO and ENSP, recommend annual screening for DR.^{25,31,32} Iceland is one of the pioneers in DR screening and introduced a risk-adjusted screening interval for DR. The Icelandic model adjusts the screening interval from 6 months up to 60 months according to the individual risk of STDR taking into account the level of HbA1c, systolic blood pressure, type of DM, stage of DR, gender, and duration of DM.³³ Screening intervals in the Icelandic model could therefore be more variable than the fixed intervals in the AAO or ENSP in the UK.^{33,34}

Types of diabetic retinopathy screening

Opportunistic versus systematic screening

Opportunistic screening is sporadic and occurs when a test is offered by a doctor or health care professional or when the patient asks the doctor for the test. Opportunistic screening may not be checked for quality assurance and may not include all those at risk. In contrast and as previously described, systematic screening consists of quality-assured pre-determined screening processes that include the active identification of those at risk, maintenance of a register of eligible subjects, and invitation to attend the screening programme. Everyone who participates in the systematic screening undergoes the same method of screening. The selection, invitation, and

follow-up processes are determined in advance and constitute a system that provides feedback and/or referral with call and recall for screening at specified intervals.

Historically, opportunistic screening has been done. Systematic screening, which includes the whole population at risk in its target group, ensures much better coverage of DM patients.

Methods used for screening

Screening for DR has been performed using different methods. This includes direct ophthalmoscopy, dilated stereoscopic funduscopy, fundus analogue photography and now, more commonly, the use of digital photography with wide-angle imaging. The digital fundus photography can be performed with pupil dilatation (mydriatic) or without pupil dilatation (non-mydriatic) and also with a stereoscopic or non-stereoscopic technique. Non-mydriatic fundus cameras have been commonly employed in DR screening as they have the advantage of not requiring pupil dilatation and can capture a wide angle of the retina. In the presence of media opacity such as cataract, however, the image quality of non-mydriatic cameras is less satisfactory and may lead to ungradable images. For this reason, mydriatic fundus photography is preferred in the diabetic population given that cataract is more prevalent as it has the advantage of having a lower percentage of ungradable images due to media opacity. Nevertheless, pupil dilatation is more time-consuming and carries a small risk of precipitating an acute angle-closure glaucoma attack.

The previously accepted gold standard for DR screening is dilated seven-field 30° stereoscopic fundus photographs with grading by experienced readers using the recommended ETDRS process (Fig 1).³⁵ This procedure remains the gold standard for academic research but is seldom adopted for population screening because it is time-consuming. Furthermore, seven-field stereoscopic fundus photographs give rise to too many screening failures and are therefore not suitable for mass screening, especially in a population with a high prevalence of cataract. Slit-lamp biomicroscopic fundus examination by an ophthalmologist is also considered the clinical gold standard and is equally effective but not practical for large-scale screening. Additionally, clinical verification and validation are difficult because of the problem of accurate clinical documentation. The detection ability of colour fundus photography using a fundus camera to detect DR was compared with that of doctors in diabetic clinics using ophthalmoscopy. The camera detection rate was 4 times higher through undilated pupils and more than twice as high through dilated pupils.³⁶ Although improved detection rates by ophthalmoscopy may improve clinical detection or

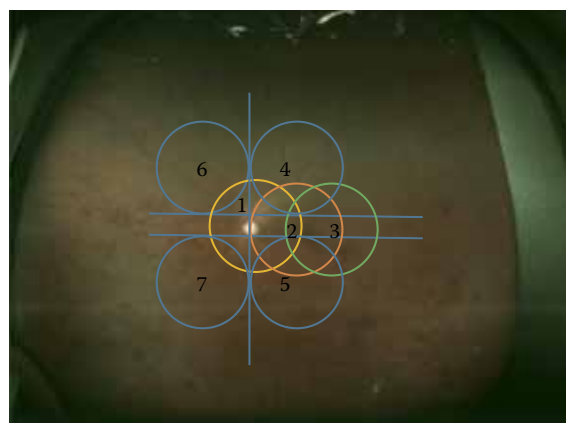


FIG 1. Seven standard fields of colour fundus photography shown in an ultrawide field fundus image (Optos image)

diagnosis of DR, ophthalmoscopy can easily overlook signs of early DR in a busy diabetic clinics.³⁶

Various studies have compared single-field and two-field screening retinal photographs to seven-field stereo photographs.³⁷⁻⁴⁰ Single-field 45° photographs centred at the fovea, when compared with seven-field photographs, had a sensitivity of 74% to 86% and specificity of 92% to 95%.^{37,38} Some other studies have shown high sensitivity and specificity to detect DR using two-field fundus photographs.^{39,40} Two-field 45° to 50° photographs consist of images covering the temporal area including the macula and optic disc and the second-field covering the nasal area including the optic disc (Fig 2). Two-field photography has the advantage of detecting DR in the nasal retina that could otherwise have been missed by single-field photography.

The ENSP for diabetic eye disease in the UK developed a screening protocol for DR using non-stereoscopic 45°, two-field fundus photography (centred at the macula and optic disc).^{26,41} Other studies have also utilised single- or three-field digital fundus photography as a screening tool for DR screening.^{42,43}

Recently, ultrawide field fundus imaging (UWFI) has shown that a 100° to 200° field view of the retina can be acquired without pupil dilatation (Optos P₂₀₀ MA and Optos P₂₀₀ C imagers; Optos, Fife, UK) [Fig 3]. It has the benefits of reducing ungradable images, increasing disease detection, and shortening image evaluation times.^{44,45} Since it can detect more retinopathy and can detect other peripheral retinal pathology, such as retinal detachment and ocular tumours, UWFI provides a more 'complete' retinal examination. Although the image quality of the photo is not as good as traditional fundus photography, it is gradually improving. It is also very expensive and there is colour distortion of the images. With further

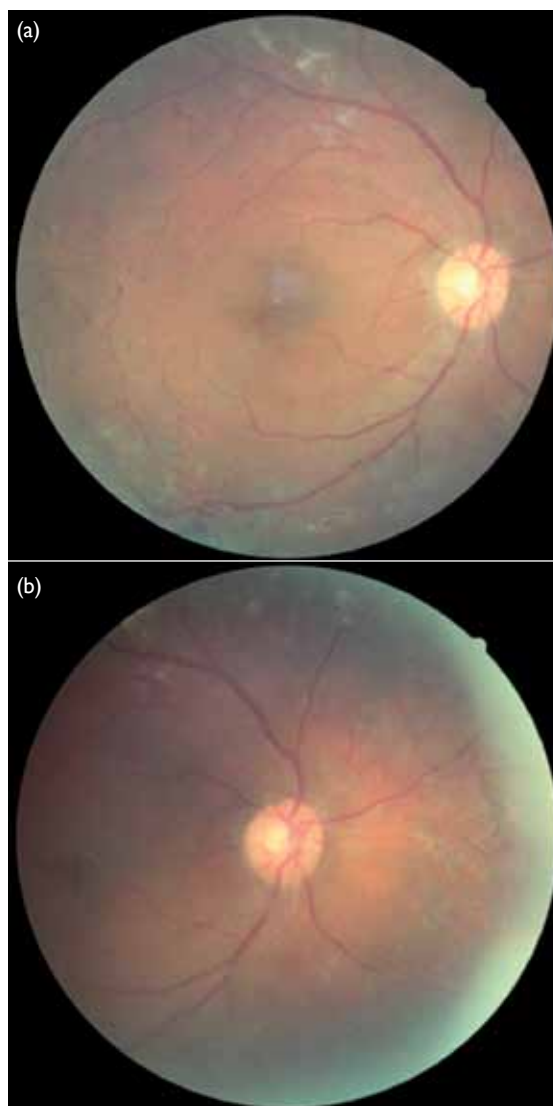


FIG 2. Two-field fundus photographs of the right eye of a patient with diabetic retinopathy Centred at (a) fovea and (b) optic disc

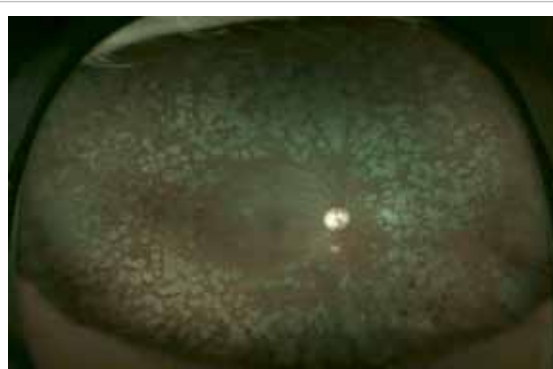


FIG 3. Ultrawide field fundus imaging (Optos image) of the right eye of a patient with diabetic retinopathy treated with pan-retinal photocoagulation

advancements, it may play a role in DR screening in the future.

Another recent technique, cell phone-based technique, has been used in which a handheld condensing lens paired with a smartphone camera can capture images at low cost.⁴⁶

Methods used in screening programmes

Several countries have implemented national screening programmes including Iceland, ENSP in the UK, and the OPHDIAT (a telemedical network screening system for DR) in France.⁴⁷⁻⁴⁹ In the OPHDIAT programme, fundus photographs are first taken with non-mydratic cameras at satellite screening centres by technicians before they are transferred via a telemedicine network to ophthalmologists for grading.⁴⁹ In India, similar telescreening is being carried out for DR in South India, in which 45° single-field digital fundus photographs are taken and images transmitted digitally for grading by retina specialists.⁵⁰ In the UK, DR graders are not medically trained but they undergo vigorous training by ophthalmologists and have to carry out a minimum number of grading episodes. There are also very stringent quality control processes, top-up training, and revalidation processes in place to guarantee quality. Once patients enter the screening programme, most are not required to undergo clinical examination by an ophthalmologist unless in cases of STDR or if there are ungradable fundus photographs or there is any other eye disease that warrants management by an ophthalmologist.

There is an additional role for general practitioners, diabetic nurses, dieticians, and others in a DR-related programme, such as the risk assessment and management programme (RAMP) in the Hospital Authority, Hong Kong. The RAMP is a primary health care programme that aims to screen patients for chronic systemic diseases including, in particular, hypertension and DM including DR.⁵¹ Type 2 DM is a disease of multiple aetiologies in which both genetic and environmental factors, particularly lifestyle, play a significant role. Lifestyle modification is therefore important. The RAMP in Hong Kong tries to implement a comprehensive package by being holistic—screening for renal diseases, examining feet and eyes, monitoring blood pressure and other cardiovascular risk factors, and educating patients about lifestyle modification. The RAMP programme in Hong Kong has been successful in controlling HbA1c and blood pressure in many subjects and should help to reduce the incidence, prevalence, and severity of DR.⁵²

Thus, DR screening can be effectively performed by ophthalmologists, optometrists, or specially trained graders, and other professionals play an important part in its wider aspects.

Classification of diabetic retinopathy in screening programmes

The most commonly adopted clinical classification of DR is NPDR and PDR. From a screening perspective, however, DR is best classified as (1) STDR or vision-threatening diabetic retinopathy (VTDR) or (2) non-STDR (or non-VTDR), as STDR warrants referral to an ophthalmologist for further management while patients with non-STDR can remain in the screening programme for further monitoring. Yau et al⁶ highlighted the methods of screening and DR grading used in various clinical studies and found that most studies use ETDRS and its modification or the AAO International Clinical Diabetic Retinopathy Disease Severity Scale. Using this classification, DR severity is categorised as NPDR (levels 20-53) or PDR (\geq level 60). For diabetic macular oedema, there is more diversity. Some studies consider diabetic macular oedema to be present if there is retinal thickening within one disc diameter of the centre of the macula or if there is a history of macular oedema with a history of photocoagulation.⁶ Other studies consider the presence of macular oedema if there are hard exudates within one disc diameter of the macula or in addition to hard exudates, presence of microaneurysm and blot haemorrhage within one disc diameter from the foveal centre or the presence of focal photocoagulation scars in the macular area.^{53,54}

The ENSP grading system has grades of no DR (R0), mild NPDR (R1), pre-PDR (R2) that includes moderate and severe NPDR grades, and PDR (R3) [Table 1].⁵⁵ Maculopathy is said to be present when there is hard exudate within one disc diameter of the centre of the fovea or microaneurysm or dot haemorrhage within one disc diameter of the centre of fovea in the presence of visual acuity of $\leq 6/12$ in the absence of any other obvious cause.⁵⁵ The screening outcomes in ENSP include: annual screening, referral to an ophthalmologist (for pre-PDR, which could be moderate or severe NPDR, and maculopathy), and fast-track referral (for PDR). Although there are different DR classifications, most can be converted using a conversion table (Table 2).⁵⁶

Systematic diabetic retinopathy screening in Hong Kong

Screening procedure

Diabetes is prevalent in Hong Kong with an estimated 10% of the population afflicted.⁵⁷ As previously described, the Hospital Authority, the major public health care provider in Hong Kong, started a multidisciplinary RAMP for patients receiving DM care in primary care out-patient clinics known as general out-patient clinics. All enrolled patients in RAMP undergo comprehensive screening for diabetic complications including systematic DR

screening, following the ENSP guideline, which was started in Hong Kong in 2010. As well as RAMP attempting to educate and modify the patient risk factors such as blood sugar level (HbA1c), blood pressure, blood lipids, body weight and smoking habit, patients receive treatment from doctors and further counselling from nurses about the results of tests including the retinopathy result.

The DR screening procedure consists of checking habitual and pinhole visual acuity in each eye using an ETDRS chart. Pupils are dilated and non-stereoscopic digital colour retinal fundus

photographs are taken for each patient: two photographs are taken for each eye—one centred at the macula and the other centred at the optic disc.

Grading procedure in diabetic retinopathy screening in risk assessment and management programme in Hong Kong

Based on the ENSP, all fundus photographs are graded on the digital monitors with a spatial resolution of 1024 x 768 pixels, by trained optometrists and an ophthalmologist, for presence/absence and severity of DR.^{26,55} The fundus photographs undergo

TABLE 1. Grading of diabetic retinopathy^{55*}

Grade of retinopathy	Description	Features
Retinopathy	R0	None
	R1	Background Microaneurysms Retinal haemorrhages
	R2	Pre-proliferative Venous beading Venous loop or reduplication Intraretinal microvascular abnormality Multiple deep, round, or blot haemorrhages, and hard exudates Cotton wool spots in addition to the above features
	R3	Proliferative New vessels on disc New vessels elsewhere Preretinal or vitreous haemorrhage Extensive fibrovascular proliferation Preretinal fibrosis ± tractional retinal detachment
Maculopathy	M	- Exudate within 1 DD of centre of fovea Circinate or group of exudates within the macula Retinal thickening of ≤1 DD of centre of fovea Any microaneurysm or haemorrhage within 1 DD of centre of fovea only if VA ≤6/12
Photocoagulation	P	- Focal or scatter laser scars
Other lesions	OL	- Non-diabetic lesions as ARMD
Unclassifiable	U	Ungradable For example, if media opacity, poor photographs

Abbreviations: ARMD = age-related macular degeneration; DD = disc diameter; VA = visual acuity

* Sight-threatening diabetic retinopathy includes R2, R3, M, presence of focal or scatter laser scars

TABLE 2. Different classifications of diabetic retinopathy⁵⁶

ETDRS	NSC (UK)	AAO	RCOphth
10 None	R0 none	No apparent retinopathy	None
20 Microaneurysms only	R1 background	Mild NPDR	Low risk
35 Mild NPDR	-	Moderate NPDR	-
43 Moderate NPDR	R2 pre-proliferative	-	High risk
47 Moderately severe NPDR	-	-	-
53 A-D severe NPDR	-	Severe NPDR	-
53 E very severe NPDR	-	-	-
61 Mild PDR	R3 proliferative	PDR	PDR
65 Moderate PDR	-	-	-
71,75 High-risk PDR	-	-	-
81,85 Advanced PDR	-	-	-

Abbreviations: AAO = American Academy of Ophthalmology; ETDRS = Early Treatment Diabetic Retinopathy Study; NPDR = non-proliferative diabetic retinopathy; NSC (UK) = National Screening Committee (United Kingdom); PDR = proliferative diabetic retinopathy; RCOphth = Royal College of Ophthalmologists

grading by a primary grader, secondary grader, and arbitration grader as per ENSP. Fundus photographs that are not assessable are considered as ungradable. Patients with STDR (grades R2, R3, maculopathy, and ungradable) are referred to specialist ophthalmology clinics of the Hospital Authority for further management. By applying the Icelandic model, patients with grades R0 or R1 are usually scheduled for their next screening appointment in 12 months or later unless they are considered at high risk for STDR, based on risk factors including HbA1c and blood pressure, in which case, they will be screened at a shorter screening interval. Some RAMP clinics use the Icelandic model as a reference to stratify the individual risk of STDR based on the level of risk factors.

Grader requirements and quality assurance

The graders undergo a structured training programme to identify different features of DR, periodic assessments, and continuous monitoring of grading performance. The graders are required to achieve and maintain sensitivity of $\geq 95\%$ and specificity of $\geq 85\%$ at all levels of grading. For quality assurance, a set of images were sent to an international DR grading centre, the Ophthalmic Reading Centre, Royal Liverpool University Hospital, Liverpool, UK, and the grades given were compared with those given by the local Hong Kong graders. There was a high level of agreement between the local graders and those from the international grading centre (unpublished data).

This screening system in Hong Kong has the advantage of taking digital fundus photographs, which is feasible, affordable in terms of time and cost, reproducible, and allows a relatively easy grading process. The major challenge in this method is the number of referrals generated—particularly for patients with maculopathy. In ENSP, patients who have a single-dot haemorrhage or exudate close to the fovea are referred to the specialist ophthalmology clinic. Most of these patients, particularly mild cases who do not have clinically significant macular oedema, do not require treatment or intervention. In addition, patients with grade R2, which includes grades of moderate and severe NPDR, may or may not need immediate treatment. Nevertheless, the system used in Hong Kong is cautious in that the patients with STDR who require treatment will be identified earlier rather than later.

Prevalence of diabetic retinopathy/sight-threatening diabetic retinopathy from systematic screening

From August 2010 to March 2014, a total of 262 661 screening episodes were performed with a total number of 174 532 patients receiving DR screening. The prevalence of any DR at first screening

was 39% (68 058/174 532) and of STDR 9.8% (17 116/174 532).⁵⁸

The future of diabetic retinopathy screening

Screening of DR is currently performed by trained professionals, such as ophthalmologists, optometrists, or specially trained graders. Since it requires screening of large populations and is time-consuming, the role of automated grading is currently being explored. In this, a computer system uses image processing and pattern recognition techniques to detect the lesions of DR. The pattern recognition consists of two distinct methods: the digital image processing method and the neural network method. The image processing method is suitable for detecting and counting early lesions of DR such as haemorrhages, microaneurysms, hard exudates, and cotton wool spots. The neural network method is suitable for solving pattern recognition problems such as lesion patterns of various stages of severity of DR; thus the neural network method is helpful in grading DR.⁵⁹ Results from computer-aided analysis of the retina or automated analysis of diabetic subjects, based on the appearance of blood vessels in their ocular fundus, are encouraging.^{60,61} An internet-based tele-ophthalmology system could correctly identify clinically significant macular oedema and PDR based on Joint Photographic Experts Group-compressed stereoscopic photographic files when compared with standard ETDRS-graded stereoscopic slide film photography.⁶² Researchers are now focusing on automated diagnosis of retinopathy by content-based image retrieval that is the process of retrieving related images from a large database collection based on their pictorial content.⁶²

Use of optical coherence tomography in screening

Optical coherence tomography (OCT) provides high-resolution in-vivo imaging of the different cellular layers of the macula (Fig 4).²⁵ It is an important non-invasive procedure that has revolutionised the management of diabetic macular oedema in a way that helps to assess and monitor macular thickness, monitor macular oedema, identify vitreomacular traction and other forms of macular abnormalities in patients with diabetic macular oedema.^{25,63} Classification by OCT of diabetic macular oedema helps to objectively quantify and monitor the severity of macular oedema (Table 3).⁶³⁻⁶⁵ In the DR screening programmes using non-stereoscopic digital retinal photos, the presence of maculopathy is judged using 2-dimensional fundus photographs and many cases identified in this way do not warrant treatment. Recently ENSP has started introducing

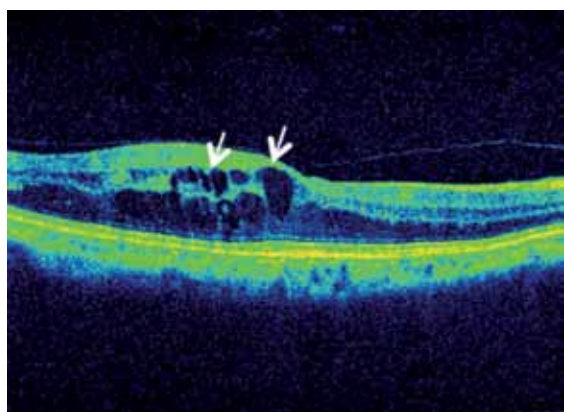


FIG 4. Optical coherence tomographic image of a patient with diabetic macular oedema demonstrating ovoid cystic spaces (white arrows)

TABLE 3. Optical coherence tomographic (OCT) classification of diabetic macular oedema⁶⁵

OCT features	
I	Diffuse retinal thickening
II	Cystoid macular oedema
III	Posterior hyaloid traction
IV	Subretinal fluid/serous retinal detachment
V	Tractional retinal detachment

OCT as a screening tool for maculopathy at their screening sites (unpublished data).

Conclusion

This review has summarised the recommendations and methods of DR screening adopted in various countries globally and in Hong Kong. Development of low-cost cameras with integration of DR screening in public health care programmes could facilitate the availability of DR screening to populations of different income groups in various countries, particularly in developing countries. Sustainability of a quality-assured screening programme, ensuring that patients are compliant with appropriate screening intervals and treatment, is one of the greatest challenges that can be overcome by educating the population and empowering primary eye care workers and health care workers. Continued efforts are required by all eye care professionals.

Declaration

All authors have disclosed no conflicts of interest.

References

1. Gakidou E, Mallinger L, Abbott-Klafter J, et al. Bulletin of

the World Health Organization. Management of diabetes and associated cardiovascular risk factors in seven countries: a comparison of data from national health examination surveys. Available from: <http://www.who.int/bulletin/volumes/89/3/10-080820/en/#>. Accessed 22 Oct 2015.

2. World Health Organization. Diabetes programme: diabetes. Available from: <http://www.who.int/diabetes/en/>. Accessed 13 Jan 2016.

3. World Health Organization. Media centre: diabetes. Available from: <http://www.who.int/mediacentre/factsheets/fs312/en/>. Accessed 13 Jan 2016.

4. Dodson PM. Diabetic retinopathy: screening to treatment. Oxford: Oxford University Press; 2008.

5. Fowler MJ. Microvascular and macrovascular complications of diabetes. Clin Diabetes 2008;26:77-82.

6. Yau JW, Rogers SL, Kawasaki R, et al. Global prevalence and major risk factors of diabetic retinopathy. Diabetes Care 2012;35:556-64.

7. Zhu CH, Zhang SS, Kong Y, Bi YE, Wang L, Zhang Q. Effects of intensive control of blood glucose and blood pressure on microvascular complications in patients with type II diabetes mellitus. Int J Ophthalmol 2013;6:141-5.

8. Stratton IM, Kohner EM, Aldington SJ, et al. UKPDS 50: risk factors for incidence and progression of retinopathy in Type II diabetes over 6 years from diagnosis. Diabetologia 2001;44:156-63.

9. Matthews DR, Stratton IM, Aldington SJ, Holman RR, Kohner EM, Group UKPDS. Risks of progression of retinopathy and vision loss related to tight blood pressure control in type 2 diabetes mellitus: UKPDS 69. Arch Ophthalmol 2004;122:1631-40.

10. Preliminary report on effects of photocoagulation therapy. The Diabetic Retinopathy Study Research Group. Am J Ophthalmol 1976;81:383-96.

11. Treatment techniques and clinical guidelines for photocoagulation of diabetic macular edema. Early Treatment Diabetic Retinopathy Study report number 2. Early Treatment Diabetic Retinopathy Study Research Group. Ophthalmology 1987;94:761-74.

12. Early photocoagulation for diabetic retinopathy. ETDRS report number 9. Early Treatment Diabetic Retinopathy Study Research Group. Ophthalmology 1991;98(5 Suppl):766S-785S.

13. Wenick AS, Bressler NM. Diabetic macular edema: current and emerging therapies. Middle East Afr J Ophthalmol 2012;19:4-12.

14. Stewart MW. Anti-VEGF therapy for diabetic macular edema. Curr Diab Rep 2014;14:510.

15. Garg S, Davis RM. Diabetic retinopathy screening update. Clin Diabetes 2009;27:140-5.

16. Happich M, Reitberger U, Breitschdel L, Ulbig M, Watkins J. The economic burden of diabetic retinopathy in Germany in 2002. Graefes Arch Clin Exp Ophthalmol 2008;246:151-9.

17. Wilson JM, Jungner G. Principles and practice of screening for disease. Geneva: World Health Organization; 1968.

18. Rohan TE, Frost CD, Wald NJ. Prevention of blindness by screening for diabetic retinopathy: a quantitative assessment. BMJ 1989;299:1198-201.

19. Stefánsson E, Bek T, Porta M, Larsen N, Kristinsson JK, Agardh E. Screening and prevention of diabetic blindness. Acta Ophthalmol Scand 2000;78:374-85.

20. Crijns H, Casparie AF, Hendrikse F. Continuous computer simulation analysis of the cost-effectiveness of screening and treating diabetic retinopathy. *Int J Technol Assess Health Care* 1999;15:198-206.
21. Jones S, Edwards RT. Diabetic retinopathy screening: a systematic review of the economic evidence. *Diabet Med* 2010;27:249-56.
22. Javitt JC, Aiello LP. Cost-effectiveness of detecting and treating diabetic retinopathy. *Ann Intern Med* 1996;124:164-9.
23. Lian J, McGhee SM, Gangwani RA, et al. The impact of a co-payment on the cost-effectiveness of screening for diabetic retinopathy. *J Public Health (Oxf)* 2015 Nov 14. Epub ahead of print.
24. Diabetes care and research in Europe: the Saint Vincent declaration. *Diabet Med* 1990;7:360.
25. American Academy of Ophthalmology. Diabetic retinopathy preferred practice pattern guidelines 2014. Available from: <http://one.aao.org/preferred-practice-pattern/diabetic-retinopathy-ppp-2014>. Accessed 10 Jan 2015.
26. Harding S, Greenwood R, Aldington S, et al. Grading and disease management in national screening for diabetic retinopathy in England and Wales. *Diabet Med* 2003;20:965-71.
27. Harding S, Garvican L, Talbot J. The impact of national diabetic retinopathy screening on ophthalmology: the need for urgent planning. *Eye (Lond)* 2005;19:1009-11.
28. Screening for diabetic retinopathy in Europe 15 years after the St. Vincent Declaration. Available from: <http://reseau-ophdiat.aphp.fr/Document/Doc/confliiverpool.pdf>. Accessed 6 Oct 2015.
29. Ministry of Public Health. Thailand healthy lifestyle strategic plan 2011-2020. Bangkok, Thailand: The War Veterans Organizations of Thailand; 2011: 58.
30. World Diabetes Foundation mobile eye care WDF08-395. Available from: <http://www.worlddiabetesfoundation.org/projects/thailand-wdf08-395>. Accessed 8 Apr 2013.
31. American Diabetes Association. Standards of medical care in diabetes—2014. *Diabetes Care* 2014;37 Suppl 1:S14-80.
32. Diabetes—diabetic eye screening. Available from: <http://www.nhs.uk/conditions/Diabetes/Pages/diabetic-eye-screening.aspx>. Accessed 13 Jan 2016.
33. Aspelund T, Thórnórisdóttir O, Olafsdóttir E, et al. Individual risk assessment and information technology to optimise screening frequency for diabetic retinopathy. *Diabetologia* 2011;54:2525-32.
34. McGhee S, Harding SP, Wong D. Individual risk assessment and information technology to optimise screening frequency for diabetic retinopathy by Aspelund et al. (2011) *Diabetologia* 54:2525-2532. *Graefes Arch Clin Exp Ophthalmol* 2012;250:477-8.
35. Grading diabetic retinopathy from stereoscopic color fundus photographs—an extension of the modified Airle House classification. ETDRS report number 10. Early Treatment Diabetic Retinopathy Study Research Group. *Ophthalmology* 1991;98(5 Suppl):786S-806S.
36. Ryder RE, Vora JP, Atiea JA, Owens DR, Hayes TM, Young S. Possible new method to improve detection of diabetic retinopathy: Polaroid non-mydratric retinal photography. *Br Med J (Clin Res Ed)* 1985;291:1256-7.
37. Ku JJ, Landers J, Henderson T, Craig JE. The reliability of single-field fundus photography in screening for diabetic retinopathy: the Central Australian Ocular Health Study. *Med J Aust* 2013;198:93-6.
38. Williams GA, Scott IU, Haller JA, Maguire AM, Marcus D, McDonald HR. Single-field fundus photography for diabetic retinopathy screening: a report by the American Academy of Ophthalmology. *Ophthalmology* 2004;111:1055-62.
39. Scanlon PH, Malhotra R, Greenwood RH, et al. Comparison of two reference standards in validating two field mydratric digital photography as a method of screening for diabetic retinopathy. *Br J Ophthalmol* 2003;87:1258-63.
40. Boucher MC, Gresset JA, Angioi K, Olivier S. Effectiveness and safety of screening for diabetic retinopathy with two nonmydratric digital images compared with the seven standard stereoscopic photographic fields. *Can J Ophthalmol* 2003;38:557-68.
41. Scanlon PH. The English national screening programme for sight-threatening diabetic retinopathy. *J Med Screen* 2008;15:1-4.
42. Lin DY, Blumenkranz MS, Brothers RJ, Grosvenor DM. The sensitivity and specificity of single-field nonmydratric monochromatic digital fundus photography with remote image interpretation for diabetic retinopathy screening: a comparison with ophthalmoscopy and standardized mydratric color photography. *Am J Ophthalmol* 2002;134:204-13.
43. Vujosevic S, Benetti E, Massignan F, et al. Screening for diabetic retinopathy: 1 and 3 nonmydratric 45-degree digital fundus photographs vs 7 standard early treatment diabetic retinopathy study fields. *Am J Ophthalmol* 2009;148:111-8.
44. Silva PS, Cavallerano JD, Tolls D, et al. Potential efficiency benefits of nonmydratric ultrawide field retinal imaging in an ocular telehealth diabetic retinopathy program. *Diabetes Care* 2014;37:50-5.
45. Kim JD, Warren C, Shachar T, Goldberg MR, Kim JE. Comparison of non-mydratric ultra-widefield fundus photography to standard early treatment of diabetic retinopathy study 7-fields in diabetic retinopathy screening. *Invest Ophthalmol Vis Sci* 2015;56:600.
46. Haddock LJ, Kim DY, Mukai S. Simple, inexpensive technique for high-quality smartphone fundus photography in human and animal eyes. *J Ophthalmol* 2013;2013:518479.
47. Olafsdóttir E, Stefánsson E. Biennial eye screening in patients with diabetes without retinopathy: 10-year experience. *Br J Ophthalmol* 2007;91:1599-601.
48. Kristinsson JK. Diabetic retinopathy. Screening and prevention of blindness. A doctoral thesis. *Acta Ophthalmol Scand Suppl* 1997;(223):1-76.
49. Massin P, Chabouis A, Erginay A, et al. OPHDIAT: a telemedical network screening system for diabetic retinopathy in the Ile-de-France. *Diabetes Metab* 2008;34:227-34.
50. Raman R, Bhojwani DN, Sharma T. How accurate is the diagnosis of diabetic retinopathy on telescreening? The Indian scenario. *Rural Remote Health* 2014;14:2809.
51. Fung CS, Chin WY, Dai DS, et al. Evaluation of the quality of care of a multi-disciplinary risk factor assessment and management programme (RAMP) for diabetic patients. *BMC Fam Pract* 2012;13:116.
52. Jiao FF, Fung CS, Wong CK, et al. Effects of the Multidisciplinary Risk Assessment and Management

- Program for Patients with Diabetes Mellitus (RAMP-DM) on biomedical outcomes, observed cardiovascular events and cardiovascular risks in primary care: a longitudinal comparative study. *Cardiovasc Diabetol* 2014;13:127.
53. Klein BE. Overview of epidemiologic studies of diabetic retinopathy. *Ophthalmic Epidemiol* 2007;14:179-83.
 54. Rema M, Premkumar S, Anitha B, Deepa R, Pradeepa R, Mohan V. Prevalence of diabetic retinopathy in urban India: the Chennai Urban Rural Epidemiology Study (CURES) eye study, I. *Invest Ophthalmol Vis Sci* 2005;46:2328-33.
 55. Kinshuck D. Examining and grading retinopathy, for professionals. Available from: <http://www.diabeticretinopathy.org.uk/gradingretinopathy.htm>. Accessed 20 Aug 2015.
 56. The Royal College of Ophthalmologists. Diabetic retinopathy guidelines. Available from: <https://www.rcophth.ac.uk/wp-content/uploads/2014/12/2013-SCI-301-FINAL-DR-GUIDELINES-DEC-2012-updated-July-2013.pdf>. Accessed 6 Nov 2015.
 57. International Diabetes Federation. IDF diabetes atlas 6th edition, 2013. Available from: <http://www.idf.org/diabetesatlas>. Accessed 20 Aug 2015.
 58. Lian JX, Gangwani RA, McGhee SM, et al. Systematic screening for diabetic retinopathy (DR) in Hong Kong: prevalence of DR and visual impairment among diabetic population. *Br J Ophthalmol* 2016;100:151-5.
 59. Lee SC, Lee ET, Kingsley RM, et al. Comparison of diagnosis of early retinal lesions of diabetic retinopathy between a computer system and human experts. *Arch Ophthalmol* 2001;119:509-15.
 60. Niemeijer M, van Ginneken B, Cree MJ, et al. Retinopathy online challenge: automatic detection of microaneurysms in digital color fundus photographs. *IEEE Trans Med Imaging* 2010;29:185-95.
 61. Li Q, You J, Zhang D. Vessel segmentation and width estimation in retinal images using multiscale production of matched filter responses. *Expert Syst Appl* 2012;39:7600-10.
 62. Chaum E, Karnowski TP, Govindasamy VP, Abdelrahman M, Tobin KW. Automated diagnosis of retinopathy by content-based image retrieval. *Retina* 2008;28:1463-77.
 63. Virgili G, Menchini F, Murro V, Peluso E, Rosa F, Casazza G. Optical coherence tomography (OCT) for detection of macular oedema in patients with diabetic retinopathy. *Cochrane Database Syst Rev* 2011;(7):CD008081.
 64. Al Kharousi N, Wali UK, Azeem S. Current applications of optical coherence tomography in ophthalmology. Available from: <http://www.intechopen.com/books/optical-coherence-tomography/current-applications-of-optical-coherence-tomography-in-ophthalmology>. Accessed 13 Jan 2016.
 65. Kim BY, Smith SD, Kaiser PK. Optical coherence tomographic patterns of diabetic macular edema. *Am J Ophthalmol* 2006;142:405-12.