

HOSTED BY



ELSEVIER

Available online at www.sciencedirect.com

ScienceDirect

journal homepage: www.elsevier.com/locate/ajur



CASE REPORT

Isolated penile urethral injury: A rare case following male coital trauma



Ka Wing Wong, Brian Sze Ho Ho, Chi Ho Ip, Ming Kwong Yiu*

Division of Urology, Department of Surgery, University of Hong Kong, Pokfulam, Hong Kong, China

Received 23 February 2015; received in revised form 7 April 2015; accepted 15 June 2015

Available online 6 July 2015

KEYWORDS

Penile fracture;
Urethral injury;
Penis;
Corpus spongiosum;
Urological trauma;
Urethroplasty

Abstract Penile fractures are an uncommon urological emergency. Typically, penile fractures involve the corpus cavernosum and are sometimes associated with urethral injury. Isolated corpus spongiosum and urethral injuries without concomitant corpus cavernosum injury are, however, rare. With proper knowledge of the management of penile fractures and urethral injuries, this distinct entity can be diagnosed, assessed and managed successfully without complications.

© 2015 Editorial Office of Asian Journal of Urology. Production and hosting by Elsevier (Singapore) Pte Ltd. This is an open access article under the CC BY-NC-ND license (<http://creativecommons.org/licenses/by-nc-nd/4.0/>).

1. Introduction

Penile fractures are an uncommon urological emergency [1] but are probably under-reported due to patients' embarrassment [2]. It often occurs during sexual intercourse or masturbation, although various other causes have been described. Typically, penile fractures involve the corpus cavernosum and are sometimes associated with urethral injury [3,4]. A common differential diagnosis is the isolated rupture of the superficial dorsal penile vein [5]. However, isolated corpus spongiosum and urethral injuries without concomitant corpus cavernosum injury are rare [6,7]. We

report a case of isolated penile urethral injury following coital trauma.

2. Case presentation

A 54-year-old male presented to the emergency department with penile injury. The trauma occurred when the patient was having sexual intercourse with his wife at around 2 o'clock in the early morning. His wife kneeled forward and he penetrated from behind. The patient then accidentally collided his penis into his wife's buttocks. He felt a popping sensation and reported rapid detumescence followed by severe penile pain and hematoma formation. He passed blood-stained urine mainly at the beginning of the stream, but was otherwise able to void. Subsequently, he presented to the emergency department 2 h after the accident. Physical examination revealed a flaccid, uncircumcised penis with a 4 cm preputial hematoma and

* Corresponding author.

E-mail address: yiumk2@ha.org.hk (M.K. Yiu).

Peer review under responsibility of Shanghai Medical Association and SMMU.

associated with blood stains on his urethral meatus (Fig. 1). With the probable diagnosis of a penile fracture with suspected urethral injury, the patient agreed for surgical exploration under general anesthesia.

Intraoperatively, flexible urethrocystoscopy revealed a distal penile urethral defect situated over the 6 to 10 o'clock position around 2 cm from urethral meatus (Fig. 2). After urethral catheterization, the penis was degloved with a subcoronal circumferential incision and the hematoma was evacuated. A transverse full-thickness tear of the right ventral aspect of the distal penile urethra and corpus spongiosum, involving nearly one-third of the circumference, was identified, compatible with the findings of urethrocystoscopy. There were no defects in the tunica albuginea over corpus cavernosa. The urethral defect was repaired primarily with 4-0 polyglyconate (Maxon) in an interrupted fashion (Fig. 3). The defect was covered with a small dartos flap (Figs. 4 and 5). Circumcision was performed and the skin was approximated with 4-0 polyglactin 910 (VICRYL Rapide) (Fig. 6). Urethral catheter was inserted for urinary diversion in order to protect the repair site.

The patient recovered well and the urethral catheter was removed 7 days after the operation. On his latest follow-up, his erectile function was preserved and he voided well with a good stream. There were no signs of stricture or fistula formation clinically.

3. Discussion

The true incidence of penile fractures has never been reported. Due to the rarity of the disease, discussion of the management depends mainly on retrospective case series. In one review article, 1331 cases were reported over 66 years in 183 publications. More than half of the cases were from Mediterranean countries including Turkey. "Taghaandan", referring to the practice of kneading an erected penis to achieve detumescence, is a common cause of penile fracture in that region [1,4]. Otherwise, sexual intercourse

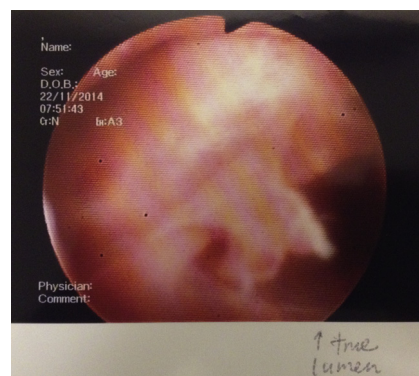


Figure 2 Endoscopic view of distal penile urethra. The true lumen was on the right side.

and masturbation are the most common etiologies of the disease [1–4].

Penile fractures can involve one or both of the corporal bodies [4]. Up to 38% of penile fractures are associated with urethral injury [8,10,11] and are more likely to have bilateral corpus cavernosal tear than unilateral tear [4,8–10]. Penile fractures usually occur on the ventral side of the proximal shaft [3,8,18]. This may be explained by the proximal location of the fulcrum of an erect penis [23]. Our patient suffered from corpus spongiosal and urethral injury at the very distal part of the penis, which may be due to his position during intercourse with direct blow of the distal part of penis into the buttock and pelvic bone of his partner, which is slightly different from the sudden and forceful angulation of the penis during intercourse or masturbation commonly experienced by other patients [1].

The diagnosis of penile fractures is mainly clinical. Patients commonly report a "pop" sound, followed by immediate detumescence, pain, hematoma and "egg-plant" penile deformity [3,12]. Different imaging modalities including cavernosography [13,14], urethrography [10,15], ultrasonography [16], color Doppler duplex [17], magnetic



Figure 1 Clinical photo of the injured penis.

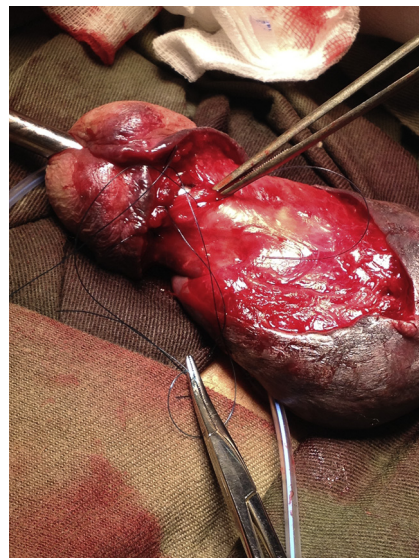


Figure 3 Repair of urethra.

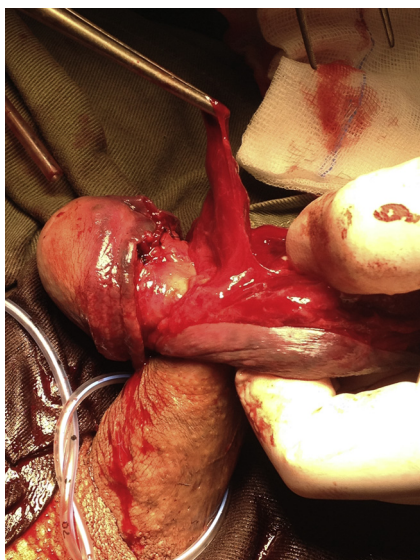

Figure 4 Dartos flap was prepared.

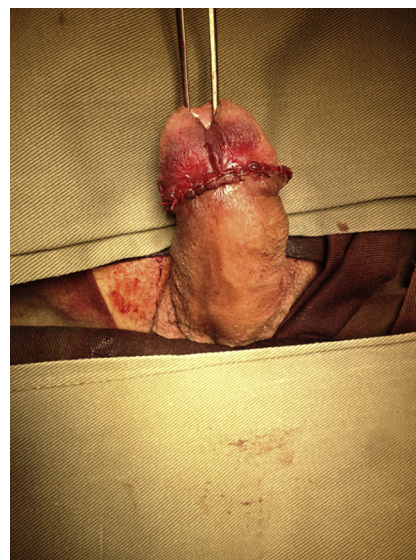

Figure 6 Postoperative appearance of the penis.

resonance imaging [18,19], and angiography [20] have been proposed as aids in the diagnosis in equivocal cases and in assessing the degree of injury. However, due to limited evidence, none of the investigations were widely adopted as a standard investigation of choice. Surgical exploration remains the definitive diagnostic procedure for suspected penile fractures [1]. Urethroscopy has also been described in the literature for the assessment of associated urethral injuries [20–22]. In our patient, the diagnosis of penile fracture was made due to the typical clinical features he presented with. No further imaging was performed because surgical exploration was already indicated and surgical repair was probably required. Urethroscopy performed intraoperatively confirmed the urethral injury.

Immediate surgical repair offers better long-term results than conservative treatment [3,24]. The principles of surgical repair include degloving of penile skin [3,13],

evacuation of hematoma [25], ligation of bleeding vessels [25], suturing of the lacerations in the tunica albuginea [26,27], end-to-end urethral anastomosis [20], and urethral stenting [9,27]. Degloving the penis allow for maximal exposure to both corpus cavernosa and corpus spongiosum [1,3,13]. Absorbable sutures were used for urethral repair in our patient to prevent stone formation in the urethra.

Complications of penile fractures, whether treated conservatively or by exploration, include penile deviation, penile plaques, painful erection, erectile dysfunction, wound infection, penile skin necrosis, urethral stricture, fistula formation and psychiatric disturbance [1]. Employing the principles of urethroplasty, dartos flap was used in our patient to cover the repair site in order to prevent possible fistula formation [28,29]. We have not observed any complications in our patient.

4. Conclusion

Penile fractures are uncommon. Isolated corpus spongiosum and urethral injuries after male coital trauma are even rarer. Adhering to the management principles of penile fractures and urethral injuries, this distinct entity of penile fractures can be diagnosed, assessed and managed successfully without complications.

Conflicts of interest

The authors declare no conflict of interest.

References

- [1] Eke N. Fracture of the penis. *BJS* 2002;89:555–65.
- [2] Redman JF, Miedema EB. Traumatic rupture of the corpus cavernosum: a case report and survey of the incidence in Arkansas. *J Urol* 1981;126:830–1.
- [3] Zargooshi J. Penile fracture in Kermanshah., Iran: report of 172 cases. *J Urol* 2000;164:364–6.

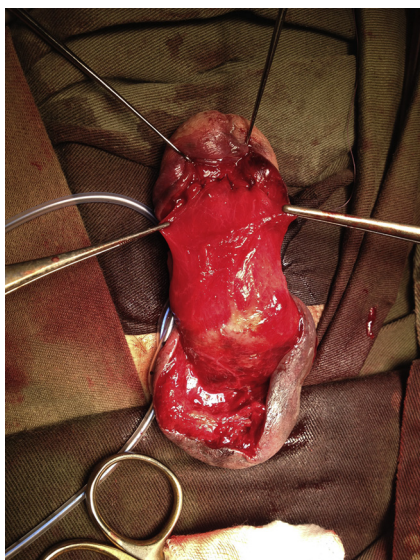


Figure 5 Repair site was covered with dartos flap.

- [4] Moslemi MK. Evaluation of epidemiology, concomitant urethral disruption and seasonal variation of penile fracture: a report of 86 cases. *Can Urol Assoc J* 2013;7:572–5.
- [5] Kurkar A, Elderwy AA, Orabi H. False fracture of the penis: different pathology but similar clinical presentation and management. *Urol Ann* 2013;6:23–6.
- [6] Patel A, Kolkin L. Isolated urethral injury after coitus-related penile trauma. *J Trauma* 2010;68:89–90.
- [7] Rigaud P, Toussaint B, Bittard H, Bittard M. Isolated urethral injury following coital faux pas. Report of a case with no associated injury of the corpora cavernosa. *Prog Urol* 1992;2:287–9.
- [8] Fergany AF, Angermeier KW, Montague DK. Review of Cleveland clinic experience with penile fracture. *Urology* 1999;54:352–5.
- [9] Kowalczyk J, Athens A, Grimaldi A. Penile fracture: an unusual presentation with lacerations of bilateral corpora cavernosa and partial disruption of the urethra. *Urology* 1994;44:599–601.
- [10] Godec CJ, Reiser R, Logush AZ. The erect penis – injury prone organ. *J Trauma* 1988;28:124–6.
- [11] Sant GR. Rupture of the corpus cavernosum of the penis. *Arch Surg* 1981;116:1176–8.
- [12] Gontero P, Sidhu PS, Muir GH. Penile fracture repair: assessment of early results and complications using color Doppler ultrasound. *Int J Impot Res* 2000;12:125–9.
- [13] Mydlo JH, Hayyeri M, Macchia RJ. Urethrography and cavernosography imaging in a small series of penile fractures: a comparison with surgical findings. *Urology* 1998;51:616–9.
- [14] Nane I, Esen T, Tellaloglu S, Selhanoglu M, Akinci M. Penile fracture: emergency surgery for preservation of penile functions. *Andrologia* 1991;23:309–11.
- [15] Ozen HA, Erkan I, Alkibay T, Kendi S, Remzi D. Fracture of the penis and long-term results of surgical treatment. *Br J Urol* 1986;58:551–2.
- [16] Hoekx L, Wyndaele JJ. Fracture of the penis: role of ultrasonography I localizing the cavernosal tear. *Acta Urol Belg* 1998;66:23–5.
- [17] Catala DL, Rapariz GMA, Valero PJ, Belon LJA, Martinez SI, Aleman FP. Fracture of the penis: value of echo-Doppler-color. *Arch Esp Urol* 1998;51:831–4.
- [18] Choi MH, Kim B, Ryu JA, Lee SW, Lee KS. MR imaging of acute penile fracture. *Radiographics* 2000;20:1397–405.
- [19] Fedel M, Venz S, Andreessen R, Sudhoff F, Loening SA. The value of magnetic resonance imaging in the diagnosis of suspected penile fracture with atypical clinical findings. *J Urol* 1996;155:1924–7.
- [20] Wespes E, Libert M, Simon J, Schulman CC. Fracture of the penis: conservative versus surgical treatment. *Eur Urol* 1987;13:166–8.
- [21] Naraynsingh V, Raju GC. Fracture of the penis. *Br J Surg* 1984;72:305–6.
- [22] Cumming J, Jenkins JD. Fracture of the corpora cavernosa and urethral rupture during sexual intercourse. *Br J Urol* 1991;67:327.
- [23] Ugwu BT, Yiltok SJ, Uba AF, Abdulmajid UF. Fracture of the penis – a rare injury on the Jos Plateau, Nigeria. *Cent Afr J Med* 1998;44:107–9.
- [24] Muentener M, Suter S, Hauri D. Long term experience with surgical and conservative treatment of penile fracture. *J Urol* 2004;172:576–9.
- [25] Cendron M, Whitmore KE, Carpiello V, Kurzweil SJ, Hanno PM, Snyder HM. Traumatic rupture of the corpus cavernosum: evaluation and management. *J Urol* 1990;144:987–91.
- [26] Esterlit A, Chaimowitsh G, Tzabari A, Shental J. Fracture of the penis: results of immediate surgical approach. *Urol Int* 1996;57:62–4.
- [27] Klein FA, Smith MJ, Miller N. Penile fracture: diagnosis and management. *J Trauma* 1985;25:1090–2.
- [28] Jiang ZY, Li XD, He QX, Fan SH, Wang ZX, Bi JH. Application of tunica dartos flap coverage to tubularized incised plate urethroplasty. *Zhonghua Nan Ke Xue* 2013;19:927–30.
- [29] Yutaro H, Yoshiyuki K, Akihiro N, Satoshi K, Keiichi T, Kenjiro K. Ventral based dartos flap for the prevention of the urethrocavitaneous fistula urethroplasty. *Int J Urol* 2007;14:725–7.