

# Management of Ovarian Masses During Pregnancy

1 POINT

Vincent Y.T. Cheung, MBBS, FRCOG, FRCSC

## INTRODUCTION

Ultrasonography has been widely used as a routine component of antenatal care. During the assessment of the fetus and the placenta, an adnexal mass may be discovered at the time of the ultrasound examination. Occasionally, an adnexal mass can also be suspected either on physical examination or as a result of clinical symptoms.

The identification of an adnexal lesion during pregnancy may pose a diagnostic and management challenge to the physician. Although most of these adnexal masses are functional ovarian cysts and generally will resolve during pregnancy, 0.7% to 1.7% of these masses will persist through the rest of the pregnancy.<sup>1,2</sup> Ovarian cyst complications such as torsion, haemorrhage, or rupture are uncommon during pregnancy. However, some women may require emergency surgery for these complications.

## The identification of an adnexal lesion during pregnancy may pose a diagnostic and management challenge

Familiarity with the natural history and sonographic features of common adnexal lesions such as simple cysts, mature cystic teratomas, endometriotic cysts, and ovarian conditions specific to pregnancy, such as ovarian hyperstimulation, hyperreactio luteinalis and lute-

## Key points

- Adnexal masses are commonly detected during pregnancy, and the majority of these masses will resolve.
- Most ovarian masses identified during pregnancy are benign. Rate of malignancy (including borderline tumours) for persistent masses is approximately 3%-4%.
- Ultrasound is often the best and the first-line imaging modality in the evaluating of adnexal masses in pregnancy.
- Ovarian torsion, although uncommon, may complicate patients who are managed expectantly.
- Observation is a reasonable approach in a pregnant woman with an asymptomatic adnexal mass with ultrasound features not concerning for malignancy.
- Laparoscopy in the second trimester can be safely performed, with some modification in techniques.
- Patients with ovarian cyst identified during pregnancy should be informed of the risks and benefits of intervention, and the ultimate management plan should be an informed decision by the patient based on the information provided by the physician.

omas, are important when evaluating a pregnant woman with an adnexal mass.

## PREVALENCE OF ADNEXAL MASSES DETECTED DURING PREGNANCY

In a study with more than 10,000 pregnant patients, it was shown that the prevalence of a simple cyst measuring 3 cm or greater was 5.3% at 8 to 10

weeks of gestational age; spontaneous regression began after 10 weeks, dropping to 1.5% prevalence by 14 weeks.<sup>3</sup> In a cross-sectional study of 2,245 women scanned at the end of the first trimester, 1.2% of the total number of cysts detected persisted beyond 16 weeks.<sup>4</sup> Also, according to two large prospective studies which followed close to 3,000 women with adnexal cysts till 6 to 8 weeks postpartum, the incidence of adnexal masses during pregnancy before 14 weeks of gestation varied from 6% to 25%.<sup>1,2</sup> Most of these adnexal masses were functional ovarian cysts

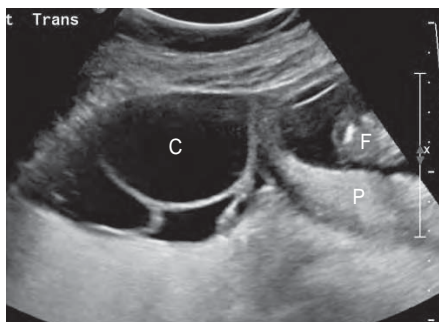


Figure A. Sonogram showing a multiloculated ovarian cyst (C) identified at the left side of the pregnant uterus. F = fetus, P = placenta.

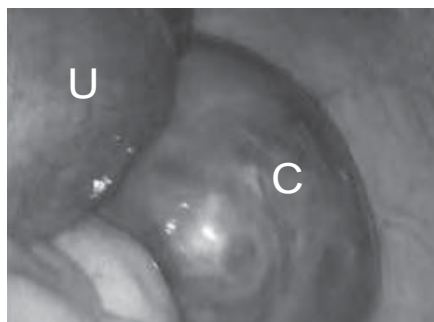


Figure B. Laparoscopic view showing a 15-week pregnant uterus (U) and a right ovarian cyst (C).

and resolved during pregnancy, leaving between 0.8% and 1.7% of women with persistent masses.<sup>1,2</sup> Ovarian cysts that have resolved spontaneously are presumed to be physiological cysts that a conservative management strategy can be considered. It is clear that the persistent masses require further diagnostic and management decisions.

## HISTOLOGICAL DIAGNOSES

### Ovarian lesions unique to pregnancy

Ovarian conditions unique to pregnancy include hyperstimulated ovaries and less commonly, hyperreactio luteinalis, theca lutein cysts, and luteomas. These conditions, with the exception of luteomas of pregnancy, are typically bilateral, aiding in their recognition.

## As in non-pregnant women, most ovarian masses identified during pregnancy are benign

Hyperstimulated ovaries represent a response to elevated circulating levels of human chorionic gonadotropin (hCG), typically occur in patients who have undergone ovulation induction, thus presenting in the first trimester. It can be associated with various degree of severity of ovarian hyperstimulation syndrome. Hyperreactio luteinalis is

an abnormal hypersensitive response to circulating levels of hCG, in the absence of any ovulation induction therapy. Up to 60% occur in a singleton pregnancy with normal circulating level of hCG. Theca lutein cysts are sonographically similar to the above conditions with bilateral enlarged ovaries with multiple cysts. They represent a normal response of the ovaries to elevated levels of hCG associated with gestational trophoblastic disease.

Luteoma is a rare benign process unique to pregnancy, in which the ovarian parenchyma is replaced by the proliferation of luteinized stromal cells that may be associated with the production of androgens. Virilization can occur in 25% to 30% of the women and in 50%

of the female fetus.<sup>5</sup> Conservative therapy is appropriate because the ovaries and serum testosterone levels usually return to normal by several weeks postpartum.

Ectopic ovarian pregnancy, although rare, can occur as an isolated condition or, in the context of this article, as part of heterotopic pregnancy

and should also be considered when an ovarian mass is identified during pregnancy.

### Benign ovarian lesions

As in non-pregnant women, most ovarian masses identified during pregnancy are benign, and among those, the most common ones reported are mature cystic teratoma (36.4% - 42.8%), endometrioma (7.3% - 24.2%), and serous and mucinous cystadenoma (13.0% - 15.2%).<sup>2,6,7</sup>

The corpus luteum of pregnancy, despite being typically described sonographically as a low-resistance Doppler pattern, and often called the “ring of fire”,<sup>8</sup> also has a varied appearance and can be inadvertently resected surgically during pregnancy. Occasionally it can be partially resected or biopsied during surgery for histological diagnosis and has been reported to be responsible for 8.6% - 13% of ovarian masses identified during pregnancy.<sup>6,7</sup>

### Malignant ovarian lesions

One of the main concerns with the identification of an adnexal mass during pregnancy is the risk of malignancy and the potential in the delay in the diagnosis and treatment of ovarian cancer. In most of the published series, the reported incidence of ovarian cancer in pregnancy ranges from 1 in 5,000 to 1 in 47,000 live births, with 2% to 6% of persistent adnexal masses found to be malignant.<sup>9</sup> From our own series of 35 pregnant women, the rate of malignancy was 1 in 10,000 live births, or 8.6% of persistent masses, which is comparable with the reported rates.<sup>6</sup> However, these reported rates depend on the selection criteria by which an adnexal mass would be removed during pregnancy. In a retrospective study of 60 adnexal masses resected during

pregnancies over a 12-year period, a malignancy rate of up to 13% had been reported,<sup>9</sup> whereas the rate of malignancy (including borderline tumours) obtained from longitudinal studies that followed the adnexal masses from early pregnancy till the postpartum period, was found to be lower (3.6% - 4.3%).<sup>1,10,11</sup>

### ULTRASOUND EVALUATION OF OVARIAN MASSES DURING PREGNANCY

Although the overall risk of ovarian malignancy among pregnant women with pelvic masses is low, the anxiety generated for both the patient and the health care team is substantial. Careful ultrasound evaluation of these masses is important to guide subsequent management. In addition, this information will become valuable if an acute clinical situation develops later in pregnancy. It is generally accepted that the ultrasound characteristics of different types of adnexal masses do not differ between pregnant and non-pregnant women.<sup>12</sup> It is beyond the scope of this article to review in detail the ultrasound appearances of different ovarian masses. Interested readers are advised to refer to related review articles, and the consensus opinion from the International Ovarian Tumor Analysis (IOTA) group.<sup>13,14</sup>

Tumour size, as well as architectural features including nodularities, excrescences, papillary projections, and septations appear to be important indicators of malignancy. Most studies have found that the majority of malignant masses in pregnant women are > 5 cm in diameter and are complex in appearance.<sup>10,11,15</sup> Schmeler et al. in their review reported that all malignant and borderline tumours were complex in appearance by ultrasound, compared to only 30% of

the benign masses.<sup>15</sup> However, despite a number of algorithms and mathematical models that have been developed in the evaluation of ovarian masses, many investigators have concluded that expert opinion on ultrasound remains more accurate than specific sonographic characteristics in differentiating benign and malignant tumours.<sup>16,17</sup>

### THE ROLE OF MRI

Although not routinely used in the assessment of ovarian masses, magnetic resonance imaging (MRI) may bring additional information to ultrasound and can be used as an adjunct in characterizing ovarian lesions found during pregnancy. However, when considering an MRI for a pregnant woman, physicians should evaluate the risk-benefit ratio before determining the necessity of this imaging modality.

### RISK OF COMPLICATIONS

Another concern with the finding of an adnexal mass during pregnancy is the possibility of complications, notably ovarian torsion. The reported rate of torsion is highly variable. While Condous et al. in their prospective study reported suspected and likely torsion rates of 2.5% and 0.6%, respectively,<sup>1</sup> and Yazbek et al. reported a 0% torsion rate,<sup>2</sup> some investigators have suggested a rate of up to 14.8%.<sup>18</sup> In a more recent observational study involving 803 women with ovarian masses identified before 24 weeks of pregnancy and with follow-up throughout the pregnancy and delivery, 5 women required emergency surgery: 3 (0.4%) for torsion and 2 (0.2%) for rupture of the mass.<sup>10</sup> The risk of torsion appeared to increase with the size of the mass and was greatest prior to 20 weeks of gestation.<sup>18</sup>

### MANAGEMENT ISSUES

The finding of an adnexal mass during pregnancy is particularly challenging, as the risks to the mother must be weighed against the potential fetal complications of surgery. In a review of over 2 million deliveries from the Swedish Health Registry, infants born after laparoscopy or laparotomy performed during pregnancy were more often preterm, low birth weight, and growth restricted.<sup>19</sup> These findings were also supported by another study which noted that 12% of deliveries after adnexal surgery were preterm, while 3% of the pregnancies ended with a spontaneous miscarriage and 5% with a perinatal death.<sup>20</sup>

The incidence of fetal loss after surgery for adnexal masses during pregnancy is difficult to assess as most studies are not prospective in nature with no comparative group. The time from operation to fetal loss is not defined. Koo et al. in 2012 reported a fetal loss rate of 1.9% within 3 weeks of surgery,<sup>7</sup> whereas Yuen et al. reported a fetal loss out of 67 cases (1.6%) which occurred 6 weeks after surgery.<sup>21</sup> In our own series, there was one fetal loss (2.9%) on the second day after surgery.<sup>6</sup>

Surgical removal of an adnexal mass is generally avoided during the first trimester of pregnancy as during this period spontaneous miscarriage is relatively more common and subsequent spontaneous resolution of the mass may occur. Although ovarian cyst torsion, haemorrhage, or rupture is uncommon, some women may require emergency surgery during pregnancy for these complications. Pregnant women with persistent masses may also prefer to have surgery in the second trimester if malignancy is suspected on sonography or to avoid cyst compli-

cations, which may necessitate emergency surgery, and potentially adds an increased risk for complications.<sup>22</sup> This was suggested in a study by Whitecar et al. which showed that women who underwent laparotomy after 23 weeks' gestation had a >50% risk of adverse perinatal outcome.<sup>22</sup>

### SAFETY OF LAPAROSCOPY DURING PREGNANCY

Surgery during the second trimester of pregnancy poses a technical challenge, especially if laparoscopic surgery is performed. One potential complication is the inadvertent injury of the gravid uterus by the Veress needle or trocar, causing bleeding, leakage of amniotic fluid, or miscarriage. Furthermore, there may be difficulty achieving adequate visualization because of the limited space between the laparoscope and the adnexal mass, especially if the umbilical trocar is used for laparoscope insertion.

Laparoscopic treatment of adnexal masses in pregnancy has been considered safe and effective.<sup>6</sup> Studies have demonstrated that laparoscopic surgery during pregnancy offers good maternal outcomes, such as shortened length of hospital stay, early return of bowel function, early ambulation, low rate of wound infection and less pain after surgery.<sup>23</sup> On the other hand, despite the lack of evidence, it is suggested that fetal outcomes seem to be less favourable in laparoscopy than laparotomy, because of the need for carbon dioxide (CO<sub>2</sub>) pneumoperitoneum and increased abdominal pressure during laparoscopy.<sup>24</sup> The Guidelines for diagnosis, treatment, and use of laparoscopy for surgical problems during pregnancy, published by the Society of American Gastrointestinal and Endoscopic Surgeons (SAGES) in 2011,

reassured the safety of laparoscopy during pregnancy, including the use of CO<sub>2</sub> insufflation of 10-15 mmHg.<sup>25</sup>

There has been much debate regarding abdominal access in a pregnant patient with preferences toward either a Hasson technique or Veress needle insertion. The concern for use of the Veress needle has largely been based on the risk of injury to the uterus or other intraabdominal organs.

SAGES Guidelines suggest that both the Hassan technique and Veress needle can be safely and effectively used if the site of initial abdominal access is adjusted according to the fundal height and the abdominal wall is adequately elevated during insertion.<sup>25</sup> The left upper quadrant approach, used extensively in patients at high risk of periumbilical adhesions, has been used in our unit and has been shown to be safe and feasible to be used in the second trimester of pregnancy.<sup>6,26</sup> In our experience, another advantage of the left upper quadrant approach compared with the traditional umbilical placement of the trocar is that it provides better panoramic vision by allowing adequate distance between the laparoscope and the adnexal mass. Moreover, with the primary laparoscopic access at the left upper quadrant, most of the intended surgeries can be completed without the need for an additional trocar placement at the umbilicus. Although ultrasound guided trocar placement has been described in the literature as an additional safeguard to avoid uterine injury, this has not been widely practiced.<sup>27</sup>

Evidence has accumulated to suggest that the clinical outcomes of laparoscopy are equivalent to those of laparotomy, while conferring all of the ad-

vantages of the laparoscopic approach.<sup>7</sup> Reedy et al. found that there was no difference in intrauterine growth restriction or stillbirth between laparoscopy and laparotomy in their 20-year study.<sup>19</sup> Oelsner et al. reported a lower rate of postoperative complications, such as maternal fever and pulmonary embolus, although there were similar rates for fetal outcomes, such as abortion, preterm labour and intrauterine growth restriction between laparoscopy and laparotomy.<sup>28</sup> It was also suggested that laparoscopic surgery was associated with reduced narcotic use, contributing to less fetal depression and reduced manipulation of the uterus, which resulted in less uterine irritability and, consequently, less preterm labour.<sup>23</sup>

### SELECTION OF CASES

Given the potential complications of surgery during pregnancy, the decision whether to operate on an adnexal mass or to observe is often difficult. Despite the increased frequency with which adnexal masses are now diagnosed during pregnancy, there is still a lack of consensus recommendations to guide clinicians on its management.

Several investigators have suggested that observation is a reasonable approach in the majority of women,<sup>8,10</sup> especially when ultrasound findings are not concerning for malignancy.

The American College of Obstetricians and Gynecologists has also suggested that adnexal masses in pregnancy appear to have low risk for both malignancy and acute complications, they may be considered for expectant management.<sup>29</sup> If the nature of an adnexal mass is indeterminate or suspicious of malignancy, a multidisciplinary approach is recommended. This includes the radi-

ologist, the obstetrician, the gynaecological oncologist and the gynaecologist specialized in minimally invasive surgery to ensure proper selection of patients that may require operative intervention and optimize the timing of surgery.

Obviously, in the acutely symptomatic pregnant patient, surgery may be performed in any trimester. Laparoscopy can be considered for both diagnosis and treatment of adnexal torsion unless clinical severity warrants laparotomy, as

dictated by the patient's clinical condition and operative findings.<sup>25</sup>

## CONCLUSIONS

Diagnostic and management algorithms for patients with adnexal masses complicating pregnancy depend on the clinical symptoms, the timing of detection, the natural history and sonographic features of the adnexal masses. Ultrasound is a valuable diagnostic tool, which can stratify adnexal masses into low or high risk of

malignancy and thus aids significantly in deciding on expectant versus operative treatment strategy. Patients with ovarian cyst identified during pregnancy should be informed of the risks and benefits of intervention, in order to enable them to make an ultimate informed management decision.

## About the Author

Dr Vincent Y.T. Cheung is a Consultant and Honorary Clinical Associate Professor at the Department of Obstetrics & Gynaecology, Queen Mary Hospital, The University of Hong Kong, Hong Kong.

## REFERENCES

1. Condous G, Khalid A, Okaro E, Bourne T. Should we be examining the ovaries in pregnancy? Prevalence and natural history of adnexal pathology detected at first-trimester sonography. *Ultrasound Obstet Gynecol* 2004;24:62-66.
2. Yazbek J, Salim R, Woelfer B, Aslam N, Lee CT, Jurkovic D. The value of ultrasound visualization of the ovaries during the routine 11-14 weeks nuchal translucency scan. *Eur J Obstet Gynecol Reprod Biol* 2007;132:154-158.
3. Glanc P, Brofman N, Salem S, Kornecki A, Abrams J, Farine D. The prevalence of incidental simple ovarian cysts  $\geq$  3 cm detected by transvaginal sonography in early pregnancy. *J Obstet Gynaecol Can* 2007;29:502-506.
4. Czekirowski A, Bednarek W, Rogowska W, Kotarski J. Difficulties in differential diagnosis of adnexal masses during pregnancy: the role of greyscale and color doppler sonography. *Ginekol Pol* 2001;72:1281-1286.
5. Choi JR, Levine D, Finberg H. Luteoma of pregnancy: sonographic findings in two cases. *J Ultrasound Med* 2000;19:877-881.
6. Ngu SF, Cheung VY, Pun TC. Surgical management of adnexal masses in pregnancy. *JSLs* 2014;18:71-75.
7. Koo YJ, Kim HJ, Lim KT, et al. Laparotomy versus laparoscopy for the treatment of adnexal masses during pregnancy. *Aust N Z J Obstet Gynaecol* 2012;52:34-38.
8. Glanc P, Salem S, Farine D. Adnexal masses in the pregnant patient: a diagnostic and management challenge. *Ultrasound Q* 2008;24:225-240.
9. Sherard GB 3rd, Hodson CA, Williams HJ, Semer DA, Hadi HA, Tait DL. Adnexal masses and pregnancy: a 12-year experience. *Am J Obstet Gynecol* 2003;189:358-362.
10. Brady PC, Simpson LL, Lewin SN, et al. Safety of conservative management of ovarian masses during pregnancy. *J Reprod Med* 2013;58:377-382.
11. Zanetta G, Mariani E, Lissoni A, et al. A prospective study of the role of ultrasound in the management of adnexal masses in pregnancy. *BJOG* 2003;110:578-583.
12. Bromley B, Benacerraf B. Adnexal masses during pregnancy: accuracy of sonographic diagnosis and outcome. *J Ultrasound Med* 1997;16:447-452.
13. Levine D, Brown DL, Andreotti RF, et al. Management of asymptomatic ovarian and other adnexal cysts imaged at US Society of Radiologists in Ultrasound consensus conference statement. *Ultrasound Q* 2010;26:121-131.
14. Timmerman D, Valentin L, Bourne TH, Collins WP, Verrelst H, Vergote I; International Ovarian Tumor Analysis (IOTA) Group. Terms, definitions and measurements to describe the sonographic features of adnexal tumors: a consensus opinion from the International Ovarian Tumor Analysis (IOTA) Group. *Ultrasound Obstet Gynecol* 2000;16:500-505.
15. Schmeier KM, Mayo-Smith WW, Peipert JF, Weitzen S, Manuel MD, Gordinier ME. Adnexal masses in pregnancy: surgery compared with observation. *Obstet Gynecol* 2005;105:1098-103.
16. Timmerman D, Schwärzler P, Collins WP, et al. Subjective assessment of adnexal masses with the use of ultrasonography: an analysis of interobserver variability and experience. *Ultrasound Obstet Gynecol* 1999;13:11-16.
17. Van Holsbeke C, Daemen A, Yazbek J, et al. Ultrasound experience substantially impacts on diagnostic performance and confidence when adnexal masses are classified using pattern recognition. *Gynecol Obstet Invest* 2010;69:160-168.
18. Yen CF, Lin SL, Murk W, et al. Risk analysis of torsion and malignancy for adnexal masses during pregnancy. *Fertil Steril* 2009;91:1895-1902.
19. Reedy MB, Källén B, Kuehl TJ. Laparoscopy during pregnancy: a study of five fetal outcome parameters with use of the Swedish Health Registry. *Am J Obstet Gynecol* 1997;177:673-679.
20. Usui R, Minakami H, Kosuge S, Iwasaki R, Ohwada M, Sato I. A retrospective survey of clinical, pathologic, and prognostic features of adnexal masses operated on during pregnancy. *J Obstet Gynaecol Res* 2000;26:89-93.
21. Yuen PM, Ng PS, Leung PL, Rogers MS. Outcome in laparoscopic management of persistent adnexal mass during the second trimester of pregnancy. *Surg Endosc* 2004;18:1354-1357.
22. Whitecar MP, Turner S, Higby MK. Adnexal masses in pregnancy: a review of 130 cases undergoing surgical management. *Am J Obstet Gynecol* 1999;181:19-24.
23. Al-Fozan H, Tulandi T. Safety and risks of laparoscopy in pregnancy. *Curr Opin Obstet Gynecol* 2002;14:375-379.
24. Reynolds JD, Booth JV, de la Fuente S, et al. A review of laparoscopy for non-obstetric-related surgery during pregnancy. *Curr Surg* 2003;60:164-173.
25. Society of American Gastrointestinal and Endoscopic Surgeons. Guidelines for diagnosis, treatment, and use of laparoscopy for surgical problems during pregnancy (April 2011). Available at <http://www.sages.org/publications/guidelines>.
26. Ngu SF, Cheung VY, Pun TC. Left upper quadrant approach in gynecologic laparoscopic surgery. *Acta Obstet Gynecol Scand* 2011;90:1406-1409.
27. Wang CJ, Yen CF, Lee CL, Soong YK. Minilaparoscopic cystectomy and appendectomy in late second trimester. *JSLs* 2002;6:373-375.
28. Oelsner G, Stockheim D, Soriano D, et al. Pregnancy outcome after laparoscopy or laparotomy in pregnancy. *J Am Assoc Gynecol Laparosc* 2003;10:200-204.
29. ACOG Practice Bulletin: Management of adnexal masses. *Obstet Gynecol* 2007;110:201-214.