

Severe influenza A H7N9 pneumonia with rapid virological response to intravenous zanamivir

Pak-Leung Ho^a, Wai-Ching Sin^b, Jasper Fuk-Woo Chan^a, Vincent Chi-Chung Cheng^a,
Kwok-Hung Chan^a

^aCarol Yu Center for Infection and Department of Microbiology, University of Hong Kong

^bAdult Intensive Care Unit, Queen Mary Hospital

Running title: Avian influenza A H7N9 pneumonia

*Correspondence: Pak-Leung Ho, Division of Infectious Diseases, Department of Microbiology and Carol Yu Centre for Infection, The University of Hong Kong, Queen Mary Hospital, Pokfulam, Hong Kong SAR, China.

Tel.: +852-2255-4897; fax: +852-2855-1241. E-mail: plho@hkucc.hku.hk

Word count: Text 679

Keywords: Avian influenza, pneumonia, zanamivir

To the editors:

In March 2013, a novel influenza A H7N9 virus of avian origin was reported to cause severe pneumonia in mainland China [1-3]. While the great majority of patients were treated with oral oseltamivir, impaired gastrointestinal absorption in critically ill patients, the lack of virological response among patients requiring extracorporeal membrane oxygenation (ECMO), and detection of the an amino acid change (arginine to lysine at residue 292, N2 numbering) in the viral neuraminidase associated with drug resistance in two H7N9 strains are major concerns [1,4]. Here, we report a case of severe pneumonia due to avian influenza A H7N9 requiring ECMO support and there was rapid clinical and virological response following intravenous zanamivir therapy.

On 21 November 2013, a 36-year-old Indonesian female in Hong Kong began to have fever, malaise, and cough. She had been previously healthy except for a history of vitiligo. She sought medical advice from two clinics and was given symptomatic treatment. She attended the accident and emergency department of a regional hospital in Hong Kong on 27 November when the symptoms deteriorated. Her temperature was 40.0°C, blood pressure was 120/63 mmHg, pulse was 116 beats·min⁻¹, respiratory rate was 18 breaths·min⁻¹ and oxygenation was 97% while breathing ambient air. A chest radiograph showed right lower zone consolidation.

After admission, there was persistent fever and rapid progression of the radiological infiltrates to both lungs and development of parapneumonic effusion despite treatment with intravenous amoxicillin-clavulanate, ceftriaxone, azithromycin, and oral oseltamivir (75 mg twice daily, total two doses given). Endotracheal intubation and mechanical ventilation were required on 29 November. Desaturation worsened and she was put on ECMO on 30 November. Initial microbiological workup including sputum culture, blood culture, urine for legionella and pneumococcal antigens, two nasopharyngeal swabs for influenza A and B antigens, and tracheal aspirate for human metapneumovirus, *Mycoplasma pneumoniae*, *Chlamydomphila pneumoniae* and *Mycobacterium tuberculosis* by PCR were negative.

In view of the rapid disease progression, the respiratory specimens were subjected to testing for avian influenza viruses [5]. PCR identified presence of H7N9 in all the respiratory specimens (throat swab, nasopharyngeal swabs and aspirates, tracheal aspirate, and pleural fluid) collected since hospitalization. No H7N9 was detected in urine and rectal swabs. PCR for influenza A subtypes H1, H3 and H5 of the nasopharyngeal swabs and tracheal aspirates was negative. Therapy with intravenous zanamivir 600 mg every 12-hourly was started on 2 December. Quantitative PCR targeting the matrix gene demonstrated that the viral loads had declined rapidly following zanamivir therapy (Figure). Sequence analysis of the neuraminidase gene of the virus recovered from tracheal aspirate showed no resistance associated mutations. Patient's condition improved clinically and she was extubated after 2

days and ECMO was discontinued on 6 December. Subsequently, it was revealed that patient had a history of buying, slaughtering, and eating a chicken in Shenzhen on 17 November.

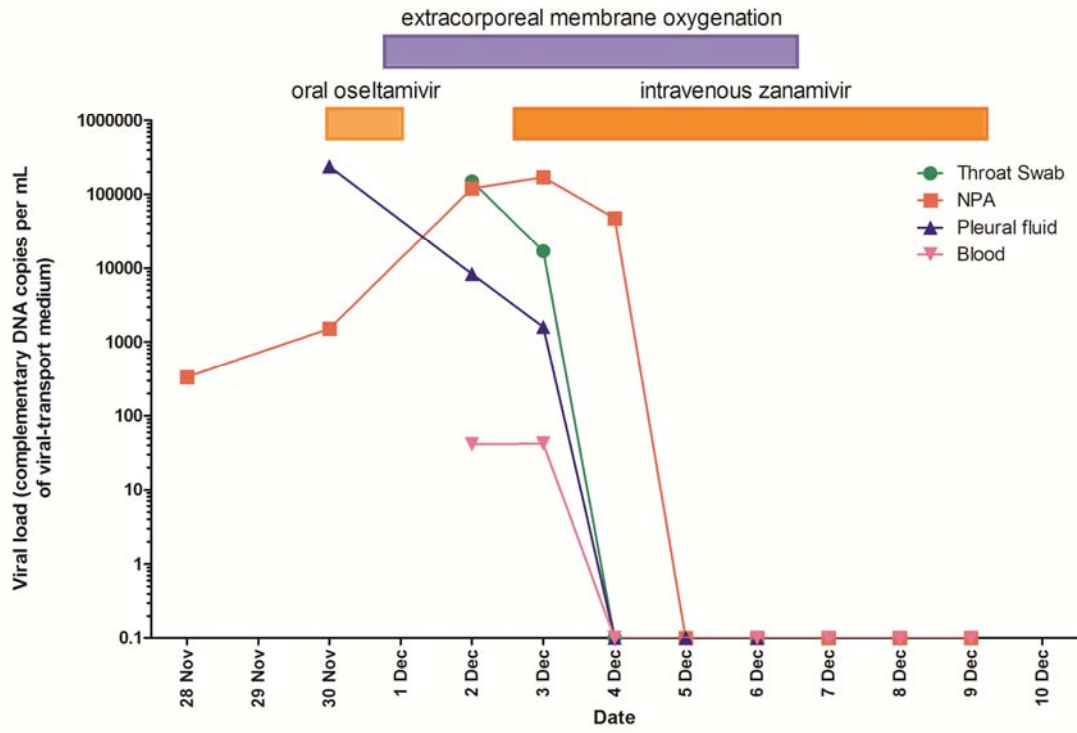
Here, we document, for the first time, rapid virological clearance in a patient with severe H7N9 pneumonia requiring ECMO. In the absence of comparative clinical studies, the optimal antiviral therapy for pneumonia caused by H7N9 remains uncertain. Genetic analysis and in vitro susceptibility testing demonstrated that most strains of H7N9 are susceptible to neuraminidase inhibitors oseltamivir and zanamivir, but resistant to adamantanes [1]. In patients with respiratory failure, inhalational neuraminidase inhibitors are unlikely to be helpful because the drugs are not expected to reach the consolidated lungs. For hospitalized patients with suspected or confirmed H7N9 influenza, both oral oseltamivir and intravenous zanamivir are currently considered to be acceptable alternatives for therapy [6,7]. Although enterically administered oseltamivir is well absorbed in critically ill influenza patients, intravenous zanamivir is preferred for patients with gastric stasis, malabsorption or gastrointestinal bleeding [6]. Antiviral therapy in the present patient was switched to intravenous zanamivir because a study by Hu et al found that patients on ECMO responded poorly to enterically administered oseltamivir and that neuraminidase-resistant mutants may emerge during oseltamivir therapy under such clinical circumstances [4]. In accordance with previous observations, decline in viral loads in our patient correlated with clinical improvement [1,4]. Our findings are useful for informing choice of antiviral therapy in future

cases but further clinical trials would be required to confirm the observation.

Acknowledgment and Support statement: We thank the patient for giving written consent for publication. The work is supported by a commission grant from the Research Fund for the Control of Infectious Diseases (RFCID) of the Food and Health Bureau of the Hong Kong SAR Government.

Statement of Interest: None declared.

Figure: Temporal changes in H7N9 viral load after intravenous zanamivir therapy.



Reference

1. To KK, Chan JF, Chen H, Li L, Yuen KY. The emergence of influenza A H7N9 in human beings 16 years after influenza A H5N1: a tale of two cities. *Lancet Infect Dis* 2013; 13:809-21.
2. Chen Y, Liang W, Yang S, Wu N, Gao H, Sheng J et al. Human infections with the emerging avian influenza A H7N9 virus from wet market poultry: clinical analysis and characterisation of viral genome. *Lancet* 2013; 381:1916-25.
3. Chan JF, To KK, Tse H, Jin DY, Yuen KY. Interspecies transmission and emergence of novel viruses: lessons from bats and birds. *Trends Microbiol* 2013; 21:544-55.
4. Hu Y, Lu S, Song Z, Wang W, Hao P, Li J et al. Association between adverse clinical outcome in human disease caused by novel influenza A H7N9 virus and sustained viral shedding and emergence of antiviral resistance. *Lancet* 2013; 381:2273-9.
5. Wang W, Ren P, Mardi S, Hou L, Tsai C, Chan KH et al. Design of multiplexed detection assays for identification of avian influenza a virus subtypes pathogenic to humans by SmartCycler real-time reverse transcription-PCR. *J Clin Microbiol* 2009; 47:86-92.
6. Centers for Disease Control and Prevention. Interim guidance on the use of antiviral agents for treatment of human infections with avian influenza A (H7N9) virus. www.cdc.gov/flu/avianflu/h7n9-antiviral-treatment.htm. Date last updated: September 30 2013. Date last accessed: January 9 2014.
7. World Health Organization. Overview of the emergence and characteristics of the avian influenza A (H7N9) virus. http://www.who.int/influenza/human_animal_interface/influenza_h7n9/en/. Date last updated: May 31 2013. Date last accessed: January 9 2014.