

Journal of Pediatric Hematology and Oncology

Central diabetes insipidus: an unusual complication in a child with juvenile myelomonocytic leukemia and monosomy 7

--Manuscript Draft--

Manuscript Number:	
Full Title:	Central diabetes insipidus: an unusual complication in a child with juvenile myelomonocytic leukemia and monosomy 7
Article Type:	Clinical and Laboratory Observations
Section/Category:	Oncology
Keywords:	JMML; monosomy 7; diabetes insipidus; neurofibromatosis.
Corresponding Author:	Alan Kwok-Shing Chiang, MBChB, PhD, FRCPCH Li Ka Shing Faculty of Medicine, The University of Hong Kong Hong Kong, CHINA
Corresponding Author Secondary Information:	
Corresponding Author's Institution:	Li Ka Shing Faculty of Medicine, The University of Hong Kong
Corresponding Author's Secondary Institution:	
First Author:	Pacharapan Surapolchai, MD
First Author Secondary Information:	
Order of Authors:	Pacharapan Surapolchai, MD Shau-Yin Ha, MBBS, FRCPCH, FRCPATH Godfrey Chi-Fung Chan, MD, DMD, MSc, FRCPCH Johannes B Lukito, MD Thomas S K Wan, PhD, FRCPATH(UK) Chi-Chiu So, MBBS, FRCPATH(UK) Alan Kwok-Shing Chiang, MBChB, PhD, FRCPCH
Order of Authors Secondary Information:	
Manuscript Region of Origin:	HONG KONG
Abstract:	Central diabetes insipidus (DI) is well documented as a presenting feature of myelodysplastic syndrome and acute myeloid leukemia in adults. However, DI is unusual in pediatric patients with myeloid malignancies. We report here this rare complication in a child with neurofibromatosis type 1 who developed juvenile myelomonocytic leukemia and monosomy 7. Our case and previously reported cases of DI arising as a complication in myeloid malignancies demonstrate a close association with deletion of chromosome 7. The clinical characteristics and outcomes of these uncommon cases in children are reviewed and discussed.

Central diabetes insipidus: an unusual complication in a child with juvenile myelomonocytic leukemia and monosomy 7

Pacharapan Surapolchai, MD^{1,4}

SY Ha, MBBS, FRCPCH, FRCPATH¹

Godfrey CF Chan, MD, DMD, MSc, FRCPCH¹

Johannes B Lukito, MD³

Thomas SK Wan, PhD, FRCPATH(UK)²

CC So, MB, BS, FRCPATH(UK)²

Alan KS Chiang, MBChB, PhD, FRCPCH¹

¹ Department of Paediatrics and Adolescent Medicine and ² Department of Pathology, Li Ka Shing Faculty of Medicine, The University of Hong Kong, Queen Mary Hospital, Pokfulam, Hong Kong, China; ³ Pantai Indah Kapuk Hospital, Jakarta, Indonesia; ⁴ Department of Pediatrics, Faculty of Medicine, Thammasat University, Pathumthani, Thailand.

Correspondence author:

Alan KS Chiang

Clinical Associate Professor & Honorary Consultant

Children's Centre of Cancers & Blood Diseases

Department of Paediatrics & Adolescent Medicine

The University of Hong Kong

Queen Mary Hospital, Pokfulam

Hong Kong, China

Tel: 852-22554091

Fax: 852-28551523

Email: chiangak@hku.hk

Abstract word count: 90

Text word count: 1084

Number of tables and figures: 1 figure and 1 table

Short running title: DI in a child with JMML and monosomy 7

Keywords: JMML, monosomy 7, diabetes insipidus, neurofibromatosis

ABSTRACT

Central diabetes insipidus (DI) is well documented as a presenting feature of myelodysplastic syndrome and acute myeloid leukemia in adults. However, DI is unusual in pediatric patients with myeloid malignancies. We report here this rare complication in a child with neurofibromatosis type 1 who developed juvenile myelomonocytic leukemia and monosomy 7. Our case and previously reported cases of DI arising as a complication in myeloid malignancies demonstrate a close association with deletion of chromosome 7. The clinical characteristics and outcomes of these uncommon cases in children are reviewed and discussed.

INTRODUCTION

Juvenile myelomonocytic leukemia (JMML) is an aggressive myeloid malignancy of childhood. This disorder is currently classified under myelodysplastic/myeloproliferative neoplasms (MDS/MPN) in children by the World Health Organization (WHO) [1]. Hepatosplenomegaly, lymphadenopathy, and constitutional symptoms are the most common presenting features [2]. Even though central DI had been described in association with other myeloid malignancies of adults, it is rare in JMML. Niemeyer *et al* [2] described only one case with DI in a retrospective study of 110 JMML cases. Hasle *et al* [3] reported 43 JMML cases with monosomy 7 and two of them presented with DI. A review of previous local data of 21 JMML patients in Hong Kong showed that 3 of them had monosomy 7 but none of them was complicated with DI (Chan GCF, unpublished data). We describe here our first case of JMML patient with neurofibromatosis type 1 (NF1) and monosomy 7 who was complicated by central DI, and compare the clinical and laboratory features with those in the literature.

CASE REPORT

A previously healthy 8-year-old Indonesian girl was found to have leucocytosis, monocytosis, and mild anemia during an episode of acute diarrhea. An initial bone marrow study revealed increased myelomonocytic series which was compatible with a myeloproliferative disorder. A diagnosis of JMML was suspected. In the subsequent two months, she complained of progressive

abdominal distension, polydipsia and polyuria. She was admitted into hospital in a semi-comatose state with dehydration. A complete blood count showed marked leukocytosis of $90 \times 10^9/L$, with hemoglobin (Hb) 9.9 g/dL and platelet count $79 \times 10^9/L$. After rehydration, she received one course of cytarabine and etoposide ($100 \text{ mg}/\text{m}^2/\text{day}$ intravenous infusion for each) for 5 days, followed by low dose cytarabine ($20 \text{ mg}/\text{m}^2/\text{day}$) for 5 days. Her condition stabilized and she was transferred to our center for further workup. On admission, she was found to have multiple café-au-lait spots (>6 and each >5 mm in greatest diameter) and hepatosplenomegaly. The patient's mother had multiple café-au-lait macules and scattered neurofibromas consistent with NF1. The clinical findings of café au lait macules and NF1 in a first-degree relative established the diagnosis of NF1 in our patient [4]. Repeated peripheral blood examination showed a leucoerythroblastic picture, with Hb 10.7 g/L, white blood cell count $23.6 \times 10^9/L$ (monocyte 31%, blast 7%), and platelet count $56 \times 10^9/L$. Her Hb F was 1%. Repeated bone marrow examination revealed active granulopoiesis and dysplastic megakaryocytes. Marrow blast count was 18%. Cytogenetic analysis showed monosomy 7 (Fig. 1A). Utilizing fluorescence *in situ* hybridization, monosomy 7 was demonstrated in 88.5% of the marrow nucleated cells (Fig. 1B). The cerebral spinal fluid examination was unremarkable. Anterior pituitary function testing was normal. Magnetic resonance imaging (MRI) of the brain showed absence of a normal bright spot over the posterior pituitary gland without thickening of the pituitary stalk (Fig. 1C and D). Central DI was subsequently confirmed by biochemical and imaging studies. A diagnosis of central DI

complicating JMML with monosomy 7 in a patient with NF1 was made, according to the WHO Classification [1]. Her polyuria resolved dramatically after commencing desmopressin (DDAVP). The patient was returned to her referring pediatrician, pending for an appropriate donor for hematopoietic stem cell transplantation (HSCT).

DISCUSSION

The association of central DI and myeloid malignancies has been uncommonly reported, even though peri-hypophyseal leukemic infiltrates were found in 46% of adult patients with acute leukemia at postmortem [5]. The onset of DI is variable, but usually occurs as a presenting feature of the myeloid malignancies [6]. The possible mechanisms include leukemic infiltration, leukostasis, thrombosis, fibrosis, infection, and hemorrhage in the hypothalamo-neurohypophyseal system [7]. In most patients the MRI findings are normal. Classical finding of disappearance of the physiological hyperintense signal, termed “bright spot”, at the neurohypophysis is caused by the loss of the vasopressin-containing vesicles in the posterior pituitary. Thickened infundibulum is also seen in some reported cases [6,7]. Loss of the bright spot at the posterior pituitary has been suggested to be related to leukemic infiltration.

Of note, cases of acute myeloid leukemia (AML)/MDS complicated by DI have been reported to be associated with abnormalities of chromosome 7 [monosomy 7 or del(7q)] and/or chromosome 3 [inv(3)(q21q26) or t(3;3)(q21;q26)] [6-8].

Cytogenetic analysis also revealed monosomy 7 in our JMML patient, again supporting the postulation that this karyotypic change is one factor contributing to the development of DI. For patients with partial or complete monosomy 7, the neutrophil migration gene in 7q22~qter region is lost, which increases susceptibility to infection and may predispose patients to onset of DI [9]. Moreover, because most circulating arginine vasopressin (ADH) is bound to the platelets, thrombocytosis related to dysthrombopoiesis in monosomy 7 and/or 3q21q26 syndrome may interfere with level and function of circulating ADH [10].

Review of the English literature of pediatric myeloid malignancies and DI yielded nine cases (Table 1) [11-19]. Seven of these (78%) patients had DI at diagnosis of AML/MDS. Cytogenetic data were available in four patients, of whom monosomy 7 and/or inversion of chromosome 3 was most commonly detected. Two patients had AML/MDS associated with NF1 and monosomy 7. Imaging studies were performed in five patients and only one patient had loss of pituitary bright spot and enhancement of infundibulum. Two of three patients, who underwent postmortem examination, had leukemic infiltration in the posterior pituitary and one patient had suspected destruction of the hypothalamic nuclei by either infarction or arachnoid infiltration. Only two of the nine patients (22%) achieved disease remission with resolution of DI. Interestingly, Harb *et al* [6] also found that reported cases of AML complicated by DI with monosomy 7 (n = 25) had a trend towards lower complete remission (CR) and survival rates than those with other chromosomal aberrations (n = 6). Furthermore, AML cases with

monosomy 7 and DI had worse CR rate than AML with monosomy 7 but without DI.

In conclusion, DI is a rare but important complication of myeloid malignancies in both adults and children and tends to occur early in the disease course. It is closely associated with the karyotypic abnormality of monosomy 7. The pathophysiological link between DI and monosomy 7 is unclear. Whether the complication of DI has additional poor prognostic implication is difficult to assess because of the rarity of such cases and the inherent poor prognosis of myeloid malignancies associated with monosomy 7 or 3q21q26 rearrangement. Nevertheless, it is important to recognize this unique complication in pediatric patients with myeloid malignancies and provide timely supportive treatment to prevent dehydration, electrolyte disturbances and aggravation of leukostasis-related complications.

Declaration of Interests

The authors report no potential conflicts of Interests.

REFERENCES

1. Baumann I, Bennett JM, Niemeyer CM, et al. Juvenile myelomonocytic leukemia. In: Swerdlow SH, Campo E, Harris NL, Jaffe ES, Pileri SA, Stein H, Thiele J, Vardiman JW, editors. World Health Organization

- classification of tumours of haematopoietic and lymphoid tissues. Lyon: IARC Press; 2008. pp 82-84.
2. Niemeyer CM, Aricò M, Basso G, et al. Chronic myelomonocytic leukemia in childhood: a report of 110 cases. *Blood* 1997;89:3534-3543.
 3. Hasle H, Aricò M, Basso G, et al. Myelodysplastic syndrome, juvenile myelomonocytic leukemia, and acute myeloid leukemia associated with complete or partial monosomy 7. European Working Group on MDS in Childhood (EWOG-MDS). *Leukemia* 1999;13:376-385.
 4. Neurofibromatosis. Conference statement. National Institutes of Health Consensus Development Conference. *Arch Neurol* 1988 ;45:575-578.
 5. Masse SR, Wolk RW, Conklin RH. Peripituitary gland involvement in acute leukemia in adults. *Arch Pathol* 1973;96:141-142.
 6. Harb A, Tan W, Wilding GE, et al. Acute myeloid leukemia and diabetes insipidus with monosomy 7. *Cancer Genet Cytogenet* 2009;190:97-100.
 7. Müller CI, Engelhardt M, Laubenberger J, et al. Myelodysplastic syndrome in transformation to acute myeloid leukemia presenting with diabetes insipidus: due to pituitary infiltration association with abnormalities of chromosomes 3 and 7. *Eur J Haematol* 2002;69:115-119.
 8. Lavabre-Bertrand T, Bourquard P, Chiesa J, et al. Diabetes insipidus revealing acute myelogenous leukaemia with a high platelet count, monosomy 7 and abnormalities of chromosome 3: a new entity? *Eur J Haematol* 2001;66:66-69.

9. Ruutu P, Ruutu T, Repo H, et al. Defective neutrophil migration in monosomy-7. *Blood* 1981;58:739-745.
10. Nussey SS, Ang VTY, Bevan DH, et al. Human platelet arginine vasopressin. *Clin Endocrinol* 1986;24:427-433.
11. Joseph MC, Levin SE. Leukemia and diabetes insipidus. Case report with unexpected effect of cortisone. *Br Med J* 1956;1:1328-1332.
12. Roy S 3rd, Johnson WW. Diabetes insipidus in a child with erythromyelocytic leukemia. *Am J Dis Child* 1970;119:82-85.
13. Bergman GE, Baluarte HJ, Naiman JL. Diabetes insipidus as a presenting manifestation of acute myelogenous leukemia. *J Pediatr* 1976;88:355.
14. Betkerur U, Shende A, Lankowsky P. Acute myeloblastic leukemia presenting with diabetes insipidus. *Am J Med Sci* 1977;273:325-327.
15. Diltek I, Uysal A, Demirer T, et al. Acute myeloblastic leukemia associated with hyperleukocytosis and diabetes insipidus. *Leuk Lymphoma* 1998;30:657-660.
16. Kanabar DJ, Betts DR, Gibbons B, et al. Monosomy 7, diabetes insipidus and acute myeloid leukemia in childhood. *Pediatr Hematol Oncol* 1994;11:111-114.
17. Frangoul HA, Shaw DW, Hawkins D, et al. Diabetes insipidus as a presenting symptom of acute myelogenous leukemia. *J Pediatr Hematol Oncol* 2000;22:457-459.
18. Wössmann W, Borkhardt A, Gossen R, et al. Acute myeloid leukemia presenting with diabetes insipidus. *Eur J Pediatr* 2002;161:161-162.

19. Kollen WJ, Ball LM, Snijder P, et al. Diabetes insipidus in a child with a monosomy-7 associated myelodysplastic syndrome and neurofibromatosis I. *Med Pediatr Oncol* 2003;40:257-259.

Fig. 1. A: Karyotype showing monosomy 7 (arrow; G-banding with trypsin-Giemsa). B: Fluorescence *in situ* hybridization analysis of interphase cells using centromeric probe for chromosome 7, showing the presence of monosomy 7 that appears as single distinct red fluorescence signal within marrow cells. C: Sagittal, T1-weighted magnetic resonance (MRI) image, representing disappearance of the physiological signal (“bright spot”) of the posterior pituitary (arrow). D: Coronal T1-weighted MRI image after gadolinium, disclosing normal sized pituitary stalk (arrow) and no enhancing lesion of hypothalamus and posterior pituitary.

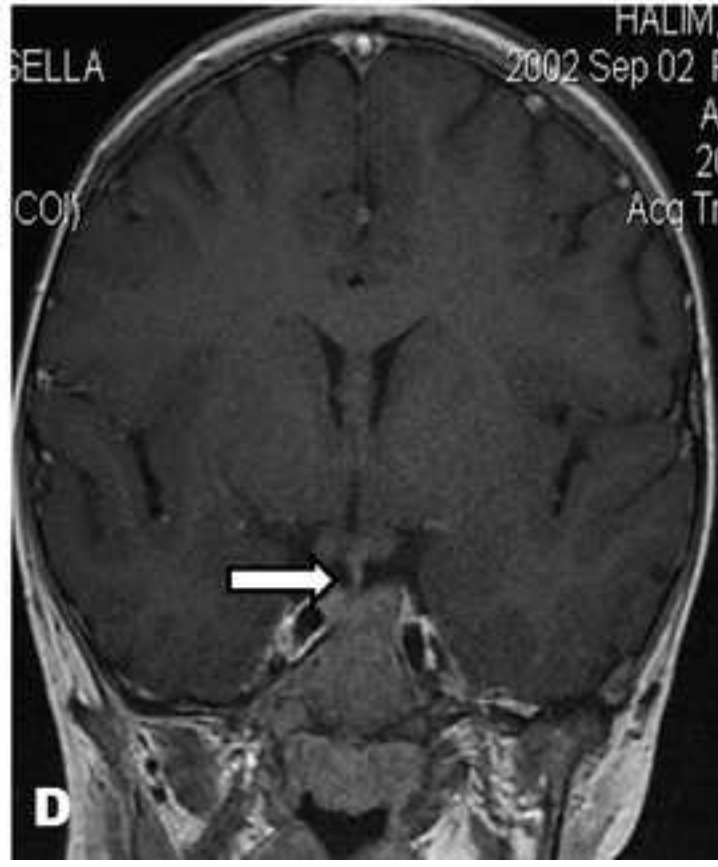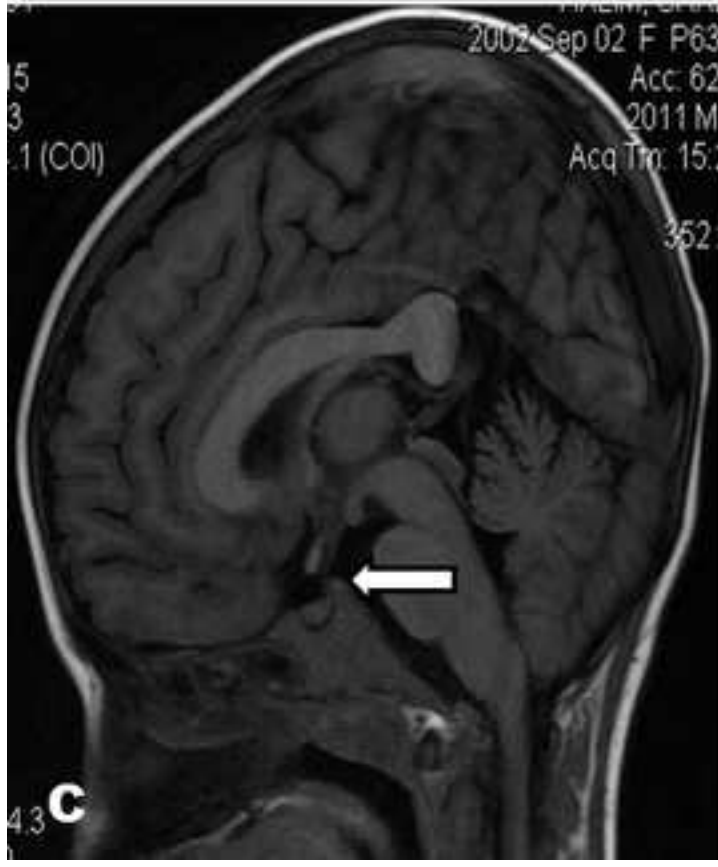
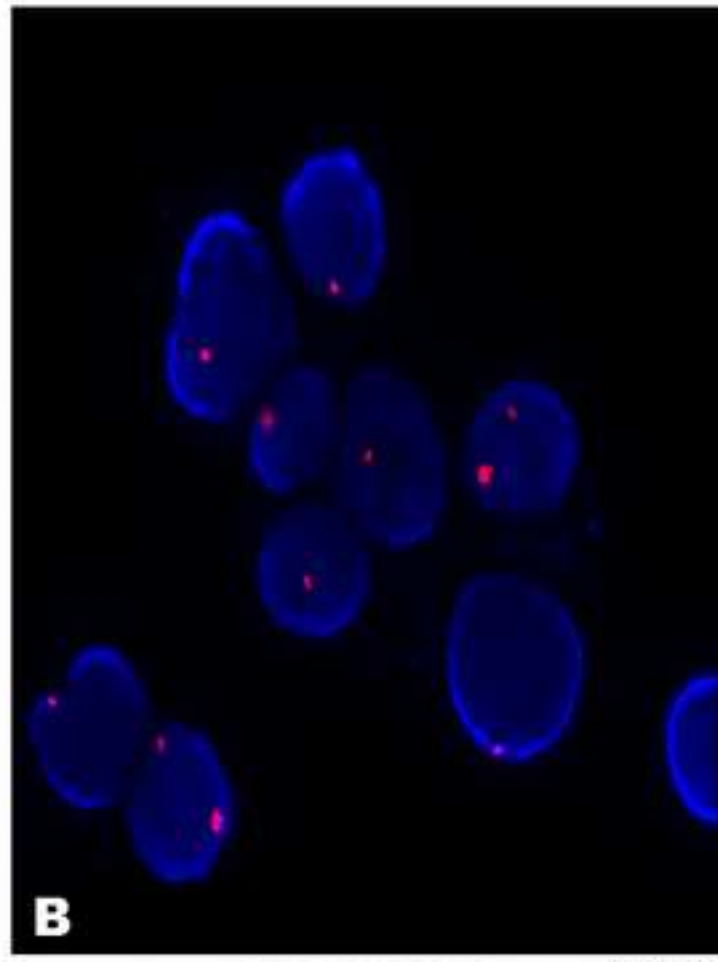



TABLE 1. Literature Review of diabetes insipidus in associated with childhood myeloid malignancies.

Reference	Age (years)/ Gender	Type of myeloid malignancies	Cytogenetics	Onset of DI, from diagnosis	Imaging	Outcome	Survival from diagnosis	Histopathology of hypothalamus and neurohypophysis
Joseph et al, 1956 [11]	10/ male	AML	NA	At diagnosis	NA	Died of disease progression	2 months	Leukemic infiltration in posterior pituitary
Roy et al, 1970 [12]	3.5/ male	AML (FAB-M6)	NA	4 months	NA	Died of infection	6 months	Leukemic infiltration in pituitary stalk
Bergman et al, 1976 [13]	8/ female	AML	NA	At diagnosis	NA	Died of disease relapse	3 months	Areas of gliosis and hemosiderin pigment containing in hypothalamus and posterior pituitary
Betkerur et al, 1977 [14]	9/ female	AML	NA	At diagnosis	NA	Died of disease progression	2 months	NA
Kanabar et al, 1994 [15]	7/ male	AML (FAB-M2)	Monosomy 7	At diagnosis	normal ^a	No CR after three courses of induction	NA	NA
Diltek et al, 1998 [16]	16/ male	AML (FAB-M4)	NA	At diagnosis	normal ^a	Died of bleeding	2 days	NA
Frangoul et al, 2000 [17]	11/ male	AML (FAB-M2)	47, XXY	At diagnosis	No bright spot, thickened and enhancing pituitary stalk ^b	Alive, in remission after CMT	NA	NA
Wössmann et al, 2002 [18]	11/ male	AML (FAB-M7)	45, XY, inv(3)(q21q26), -7	At diagnosis	normal ^b	Died of infection in post-HSCT	10 months	NA
Kollen et al, 2003 [19]	6/ male	MDS (RAEB)	Monosomy 7	6 months	normal ^b	Alive, in remission after HSCT	NA	NA

a, computed tomography of brain. b, magnetic resonance imaging of brain

AML, acute myeloid leukemia; FAB, French American British grouping; CMT, chemotherapy; CR, complete remission; DI, diabetes insipidus; HSCT, hematopoietic stem cell transplantation; MDS, myelodysplastic syndrome; NA, not applicable; RAEB, refractory anemia with excessive blasts.