

***Mycobacterium marinum* infection of the hand and wrist**

Jason Pui Yin Cheung, Boris Fung, Wing Yuk Ip, Shew-Ping Chow

Department of Orthopaedics and Traumatology, University of Hong Kong Medical Centre, Queen Mary Hospital, Hong Kong

ABSTRACT

Purpose. To review records of 166 patients who underwent treatment for *Mycobacterium marinum* tenosynovitis of the hand and wrist to identify factors associated with functional outcome.

Methods. Records of 97 men and 69 women aged 13 to 85 (mean, 50) years who underwent treatment for suspected *M. marinum* tenosynovitis of the hand and wrist were retrospectively reviewed. All underwent open biopsy; synovectomy was performed when florid synovitis was present. Rifampicin and ethambutol were usually prescribed. Clarithromycin, minocycline and/or levofloxacin were used as adjuvants if there was drug intolerance, allergy, or relapse. The duration of antibiotic treatment depended on the clinical recovery. Patients were followed up for one year after completion of drug treatment. Functional outcome was considered excellent for those with >195° total active motion (TAM) and >75% return of motion, good for those with 130° to 195° TAM and 50 to 75% return of motion, fair for those with 65° to 129° TAM and 25 to 49% return of motion, and poor for those with <65° TAM and <25% return of motion.

Results. The mean delay in presentation was 4.9 (0.3–120) months. 93 of the patients presented with disabilities (flexion deformity or reduced range of motion), 64 of whom presented one month after injury.

37 (22%) of the patients had received intralesional steroids prior to admission, 30 of whom presented one month after injury. 32 (19%) patients were treated with antibiotics alone, whereas 134 (81%) patients underwent debridement in addition to antibiotic treatment. The mean duration of antibiotic treatment was 7.2 (range, 0–29) months. Of the 156 patients who completed the follow-up, functional outcome was satisfactory in 128 (82%) and unsatisfactory in 28 (17%). Steroid injections and late presentation led to worse functional outcome. Patients with unsatisfactory outcome were more likely to have received intralesional steroid injections (43% [16/37] vs. 10% [12/118], $p<0.001$, Pearson Chi squared test), have presented >2 months after injury (27% [21/79] vs. 9% [7/77], $p=0.004$, Pearson Chi squared test), and have undergone synovectomy (23% [28/124] vs. 0% [0/32], $p=0.001$, Fisher's exact test). Worse functional outcome correlated with late presentation ($r=0.218$) and the greater number of debridement procedures ($r=0.453$).

Conclusion. Delayed antibiotic treatment of *M. marinum* infections and steroid injections were associated with unsatisfactory outcome. Clinicians must have a high index of suspicion for this condition and avoid inappropriate management such as intralesional steroid injections. Public awareness to this condition should be raised.

Key words: hand; *Mycobacterium marinum*; tenosynovitis

INTRODUCTION

Delay in diagnosis of *Mycobacterium marinum* infections is common. In 1987, the mean duration from injury to presentation to an orthopaedic unit in Hong Kong was about 3.3 to 3.7 months, although late presentation did not affect functional outcome.¹ Owing to the indolent nature of early lesions, patients often do not seek medical attention until symptoms became more florid. The initial diagnosis was usually mistaken for rheumatoid arthritis or trigger finger, which could lead to steroid injections that aggravated the infections. Injection of steroids, presence of a discharging sinus, and persistent pain were associated with an unfavourable clinical course and delayed healing of the wound, which necessitated surgical debridement.¹ We reviewed the records of 166 patients who underwent treatment for *M. marinum* tenosynovitis of the hand and wrist to identify factors associated with functional outcome.

MATERIALS AND METHODS

This study was approved by the Institutional Review Board of the University of Hong Kong/Hospital Authority Hong Kong West Cluster. Informed consent was obtained from each patient. Records of 97 men and 69 women aged 13 to 85 (mean, 50) years who underwent treatment in our unit between 1981 and September 2009 for suspected *Mycobacterium marinum* tenosynovitis of the hand and wrist were retrospectively reviewed. Patients who had risk factors of marine exposure (at home or work) and a histological diagnosis of granulomatous inflammation, with or without positive culture for *M. marinum* were included. Patients with cutaneous or lymphoid lesions or infections other than *M. marinum* were excluded.

The treatment protocol² was standardised. All patients underwent open biopsy; extensor synovectomy or flexor tenosynovectomy (Fig. 1) was performed when florid synovitis was present. Rifampicin and ethambutol were usually prescribed. Clarithromycin, minocycline and/or levofloxacin were used as adjuvants if there was drug intolerance, allergy, or relapse. The duration of antibiotic treatment depended on the clinical recovery. Patients were followed up for one year after completion of drug treatment.

Parameters analysed included: age, gender, occupation, type of injury and marine exposure, duration from symptom onset to hospital admission, site of involvement, disability, initial diagnosis

before admission, steroid injections, smear (acid-fast bacilli) and culture results, treatment used, number of operations, antibiotic regimens and duration, and the number of postoperative days before beginning range-of-motion exercises.

The main outcome measure was functional outcome quantified by the total active motion (TAM), which was defined as the sum of total active metacarpophalangeal, proximal interphalangeal, and distal interphalangeal joint flexion minus any extension lag of these joints, according to the American Society for Surgery of the Hand.³ Functional outcome was considered excellent for those with >195° TAM and >75% return of motion, good for those with 130° to 195° TAM and 50 to 75% return of motion, fair for those with 65° to 129° TAM and 25 to 49% return of motion, and poor for those with <65° TAM and <25% return of motion.³

Comparisons were made using the Student's *t* test, Pearson Chi squared test, Fisher's exact test, and correlation test. A *p* value of <0.05 was considered statistically significant.

RESULTS

Of 166 patients, 84 were fishermen or fishmongers and 26 were seafood handlers (at home or work). 131 (79%) of the patients had marine exposure during injury, 84 of whom injured the flexor side (79 involved the fingers). 92 (55%) of the patients had finger injuries, 69 of which involved the flexor side. 74 (45%) of the patients injured the hand and wrist; 34 of whom involved the flexor side. Thus, 63 (38%)

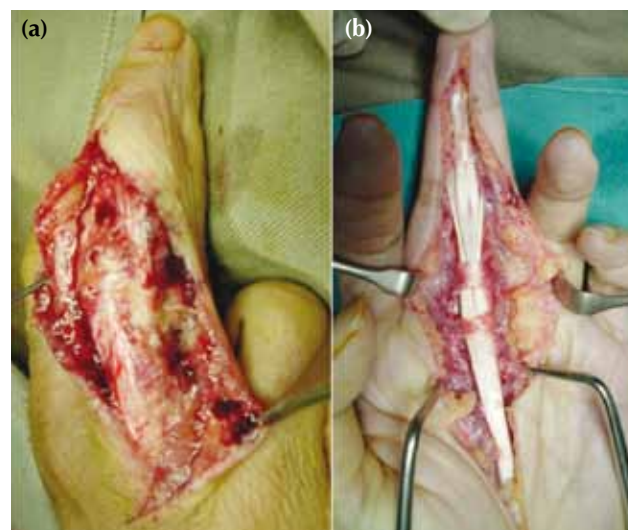

Figure 1 (a) Extensor synovectomy and (b) flexor tenosynovectomy

and 103 (62%) patients injured the extensor and flexor sides, respectively. None had osteomyelitis or septic arthritis. 10 (6%) patients were lost to follow-up.

The mean delay in presentation was 4.9 (0.3–120) months. 93 of the patients presented with disabilities (flexion deformity or reduced range of motion), 64 of whom presented one month after injury. 37 (22%) of the patients received intralesional steroids prior to admission, 30 of whom presented one month after injury.

Most patients had consulted their family physician or traditional Chinese medicine practitioner. The initial diagnosis was correct in 66 (40%) of the patients, whereas in 100 (60%) the diagnosis was mistaken as stenosing tenosynovitis, carpal tunnel syndrome, and other conditions. 42% of the incorrectly diagnosed patients presented >3 months after injury, whereas 38% of the correctly diagnosed patients did so. Thus, incorrectly diagnosed and late-presenting patients were more likely to undergo operative treatment ($p=0.034$).

Only 52 (31%) and 67 (40%) of the patients yielded a positive smear and a positive culture, respectively. 154 (93%) of the patients had positive histology (granulomatous inflammation). 32 (19%) of the patients were treated with antibiotics alone, whereas 134 (81%) received antibiotic treatment and underwent one ($n=83$), 2 ($n=30$), 3 ($n=10$), 4 ($n=9$), and 5 ($n=2$) debridement procedures for the extensor ($n=51$) or flexor ($n=83$) side (Figs. 2 and 3).

The mean duration of antibiotic treatment was 7.2 (range, 0–29) months; some patients were lost to follow-up and did not complete the regimen. 75 (45%) patients received rifampicin and ethambutol (5 of whom switched to other antibiotics owing to resistant strains, drug allergy, or retrobulbar neuritis), whereas 62 (37%) received rifampicin, ethambutol, and an adjuvant drug (isoniazid, pyrazinamide, clarithromycin or levofloxacin), 17 (10%) received either rifampicin or ethambutol with an adjuvant drug, and 11 (7%) received neither rifampicin nor ethambutol.

The mean duration before starting range-of-motion exercises was 14.5 (range, 1–112) days. The wide range was due to some patients undergoing multiple debridement procedures.

Of 156 patients who completed the follow-up, functional outcome was excellent in 100 (64%), good in 28 (18%), fair in 22 (14%), and poor in 6 (4%) patients. Thus, functional outcome was satisfactory in 128 (82%) and unsatisfactory in 28 (18%) patients. No patient had a persistent discharging sinus.

Steroid injections and late presentation led to worse functional outcome (Table 1). Patients with

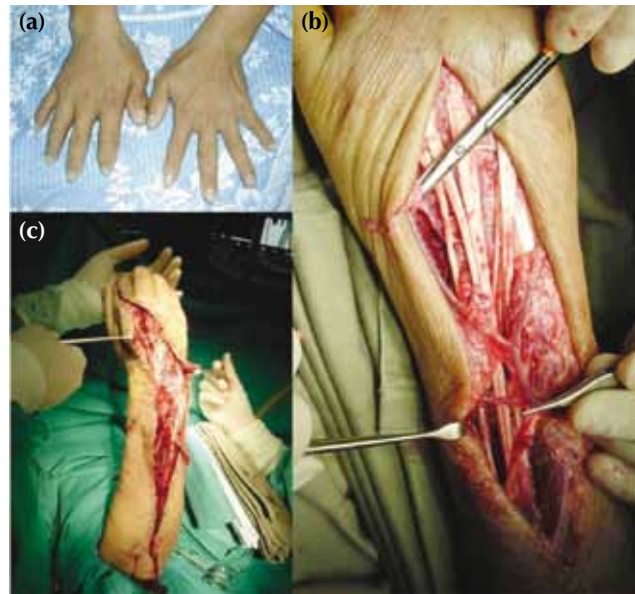


Figure 2 A 57-year-old fisherman with a puncture injury to his right wrist dorsum: (a) presentation at 3 months after injury with persistent swelling after intralesional steroid injections, (b) 4 debridement procedures are performed, and (c) the large dorsal wrist skin defect with an exposed extensor carpi ulnaris tendon is covered with a rotational flap and split-thickness skin graft.

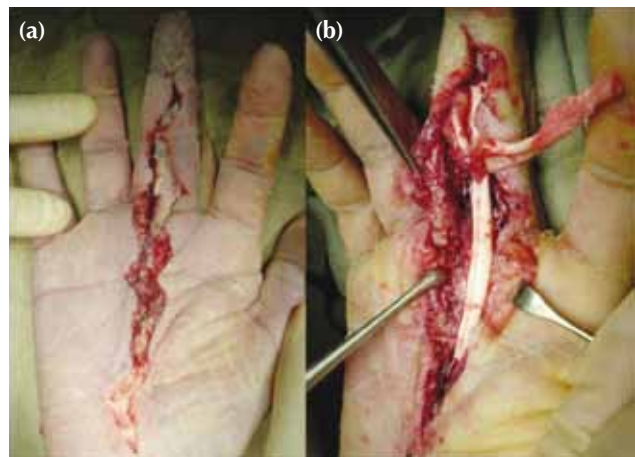

Figure 3 A 68-year-old diabetic fishmonger with a puncture injury at the right middle finger: (a) refractory infection despite 5 debridement procedures, (b) exposed bone, dessicated flexor tendons and friable skin edge. She ultimately underwent a ray amputation to control the infection.

unsatisfactory outcome were more likely to have received intralesional steroid injections (43% [16/37] vs. 10% [12/118], $p<0.001$, Pearson Chi squared test), have presented >2 months after injury (27% [21/79]

vs. 9% [7/77], $p=0.004$, Pearson Chi squared test), and have undergone synovectomy (23% [28/124]) vs. 0% [0/32], $p=0.001$, Fisher's exact test).

Late presentation correlated with worse functional outcome ($r=0.218$). Five of the 7 patients who had unsatisfactory functional outcome despite presenting <2 months after injury received intralesional steroid injections. Greater number of debridement procedures correlated with worse functional outcome ($r=0.453$). This group of patients usually had more severe and refractory disease and underwent multiple operations. The numbers of postoperative days before starting range-of-motion exercise ($p=0.441$) and the duration of antibiotic treatment ($p=0.244$) were not associated with functional outcome (Table 2).

DISCUSSION

There are 3 types of *M. marinum* infections.⁴ Types I and II are cutaneous lesions that are usually treated with medication alone. Type III is deep infection (tenosynovitis, septic arthritis, and osteomyelitis) for which surgical intervention by orthopaedic surgeons is necessary. These infections are commonly ignored by patients, and easily missed and misdiagnosed by general practitioners, which results in delayed presentation and inappropriate management (steroid injections).

The diagnosis of *M. marinum* infection depends on positive exposure risk and granulomatous

inflammation on histology. In our study, the yield rate for positive culture was only 40%, which is comparable to other studies.⁵⁻⁹ Thus, a negative culture is not specific.

Delay in diagnosing this infection was common. In one study, the mean duration from symptom onset to presentation was 7.7 (range, 1-36) months.¹⁰ In our study, many fishermen had thicker skin and might not even recall a prick or puncture injury. In a Hong Kong study in 1987,¹ 13 (54%) of 24 patients received local steroid injections before admission; 11 of whom had delayed wound healing or a poor response to antibiotics and needed surgical debridement. Steroid injections interfere with normal monocyte-macrophage functions and impairs wound healing and immunity against infections.¹¹

There is no consensus protocol for the optimal choice of antimicrobial agents and treatment duration.⁴ In one study, the treatment duration ranged from 4 to 38 (mean, 14.9) weeks, and 68% of patients showed clinical improvement.⁵ In a French study, the treatment duration ranged one to 25 (median, 3.5) months, and 87% of patients healed.⁶ Treatment failure was not related to the antibiotic regimen and its duration.⁶ In our study, duration of antibiotic treatment was also not associated with functional outcome ($p=0.244$, Student's *t* test, Table 2). The *M. marinum* species was susceptible to a wide range of antibiotics.

In one study, the mean number of debridement procedures to achieve clearance was 3.4 (range, 2-4).⁹

Table 1
Proportion of patients in terms of outcome

Parameter	No. of patients		p Value
	Satisfactory outcome	Unsatisfactory outcome	
Intralesional steroid injections			<0.001 (Chi squared test)
Yes	21	16	
No	106	12	
Presentation			0.004 (Chi squared test)
<2 months	70	7	
>2 months	58	21	
Treatment			0.001 (Fisher's exact test)
Conservative	32	0	
Synovectomy	96	28	

Table 2
Outcome analysis

Parameter	Satisfactory outcome	Unsatisfactory outcome	p Value (Student's <i>t</i> test)
Mean duration before starting range-of-motion exercise (days)	13.9	16.3	0.441
Mean duration of antibiotic treatment (months)	7	8	0.244
Mean no. of debridement procedures	1.1	2.3	<0.001

In our study, 50% of the patients underwent only one debridement. More debridement procedures represented uncontrolled infection, longer period of immobilisation, more scarring and excised tendons, and thus more loss of hand function.

Although early mobilisation can improve hand function, it may lead to flare-up, wound dehiscence, and persistent sinus formation. One protocol suggested immobilising the hand for 7 to 10 days until the wound was more stable before starting exercise.¹² In our study, the number of postoperative days before starting hand mobilisation was not associated with functional outcome ($p=0.441$, Student's t test, Table 2).

All 28 of our patients with unsatisfactory

functional outcome underwent radical synovectomy. We considered our treatment protocol appropriate: antibiotic treatment alone for patients without florid synovitis and radical synovectomy for patients with synovitis. It is more important to diagnose these infections early and avoid steroid injections. Good history and background recording is also important.

Public awareness about the potentially disabling outcome of delayed treatment for this condition should be raised, especially among those at risk such as fishermen, hawkers, and cooks. Gloves should be worn when handling raw marine life. Clinicians should have a high index of suspicion for *M marinum* infections to avoid misdiagnosis and mis-treatment.

REFERENCES

1. Chow SP, Ip FK, Lau JH, Collins RJ, Luk KD, So YC, et al. *Mycobacterium marinum* infection of the hand and wrist. Results of conservative treatment in twenty-four cases. *J Bone Joint Surg Am* 1987;69:1161–8.
2. Cheung JP, Fung BK, Ip WY. *Mycobacterium marinum* infection of the deep structures of the hand and wrist: 25 years of experience. *Hand Surg* 2010;15:211–6.
3. Strickland JW, Glogovac SV. Digital function following flexor tendon repair in Zone II: a comparison of immobilization and controlled passive motion techniques. *J Hand Surg Am* 1980;5:537–43.
4. Cheung JP, Fung B, Wong SS, Ip WY. Review article: *Mycobacterium marinum* infection of the hand and wrist. *J Orthop Surg (Hong Kong)* 2010;18:98–103.
5. Ang P, Rattana-Apiromyakit N, Goh CL. Retrospective study of *Mycobacterium marinum* skin infections. *Int J Dermatol* 2000;39:343–7.
6. Aubry A, Chosidow O, Caumes E, Robert J, Cambau E. Sixty-three cases of *Mycobacterium marinum* infection: clinical features, treatment, and antibiotic susceptibility of causative isolates. *Arch Intern Med* 2002;162:1746–52.
7. Dodiuk-Gad R, Dyachenko P, Ziv M, Shani-Adir A, Oren Y, Mendelovici S, et al. Nontuberculous mycobacterial infections of the skin: a retrospective study of 25 cases. *J Am Acad Dermatol* 2007;57:413–20.
8. Ho MH, Ho CK, Chong LY. Atypical mycobacterial cutaneous infections in Hong Kong: 10-year retrospective study. *Hong Kong Med J* 2006;12:21–6.
9. Pang HN, Lee JY, Puhaindran ME, Tan SH, Tan AB, Yong FC. *Mycobacterium marinum* as a cause of chronic granulomatous tenosynovitis in the hand. *J Infect* 2007;54:584–8.
10. Hurst LC, Amadio PC, Badalamente MA, Ellstein JL, Dattwyler RJ. *Mycobacterium marinum* infections of the hand. *J Hand Surg Am* 1987;12:428–35.
11. Ho PL, Ho P, Fung BK, Ip WY, Wong SS. A case of disseminated *Mycobacterium marinum* infection following systemic steroid therapy. *Scand J Infect Dis* 2001;33:232–3.
12. Chow SP, Stroebel AB, Lau JH, Collins RJ. *Mycobacterium marinum* infection of the hand involving deep structures. *J Hand Surg Am* 1983;8:568–73.