

A pregnant woman with a rapidly growing breast lump

US Khoo, LWC Chow, LWC Ho, R Tam, TT Alagaratnam, ANY Cheung

Presentation of case

Dr R Tam[†]: A 30-year-old pregnant woman presented with a lump on her right breast. She had no significant past history or family history of breast cancer. She was married and not on the contraceptive pill. Clinical examination showed a mobile lump, approximately 1.5 cm in size. A fine needle aspiration (FNA) was performed which showed benign changes. She was subsequently advised to have regular follow-up. She returned six months later pregnant. The right breast lump had increased in size and now measured 4 x 5 cm in diameter.

Dr TT Alagaratnam[†]: How could these findings be explained? Was this a new development?

Team B: Sometimes mastitis can occur in pregnancy, so-called pregnancy-related mastitis.

Dr Alagaratnam: An FNA was performed and the diagnosis was “benign changes related to pregnancy”. The patient returned for follow-up a week later when her pregnancy was at 33 weeks gestation. The lump was the same size. The question was: “Should we leave this lesion alone and deal with it after pregnancy or should we do a lumpectomy?”

Team B: Since the patient was so advanced in pregnancy it was felt best to advise having the baby delivered first since all the previous FNA results had shown it to be benign.

Dr Tam: When she came back to see us this year, the lump had enlarged, measuring 7 x 2 cm. She was one month post-partum at the time.

Dr Alagaratnam: This was the appearance of the breast with a 7 cm, well-demarcated lump (Fig 1). There was some redness and warmth over the mass.

The nipple was retracted but there was no skin tethering and no palpable axillary lymph nodes. Would anybody like to make some suggestion as to the diagnosis? Dr Chow, what is your impression at this stage?

Differential diagnosis

Dr LWC Chow[‡]: I first saw the patient at this stage. It was obviously a very big lump—a very rapidly growing one. In view of the past FNA report, the change would most likely be related to pregnancy. A fibroadenoma can grow to a large size during pregnancy. However, in view of the rapid growth, one also has to bear in mind the possibility of malignancy. In pregnancy, carcinoma of the breast carries a poor prog-

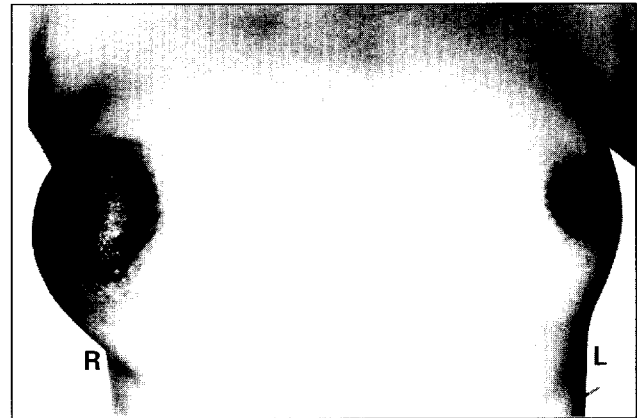


Fig 1. Clinical appearance of the right breast lump. Note the retracted nipple and some redness of the overlying skin

nosis as most of these are discovered at an advanced stage because of the delay in diagnosis. As the skin overlying the mass showed redness and the nipple was retracted, this could also have been an inflammatory carcinoma. However, the redness is not typical of the erythema of inflammatory carcinoma which appears like an erysipelas-type infection. Moreover, inflammatory carcinoma is usually associated with peau d’orange and weals or ridging of the skin—features secondary to dermal lymphatic invasion.

The surgical pathology conference is from the Queen Mary Hospital, The University of Hong Kong, Pokfulam, Hong Kong

^{†,‡} Department of Surgery

Dr Alagaratnam: At that time, the worrying feature was that this may have been a carcinoma we had missed during the pregnancy, progressing particularly in the last few weeks. When I was asked to see the patient, the first impression I had was that this was a well walled-off lesion from the rest of the breast. It was not an infiltrating lesion typical of malignancy and at that time I even thought of a chronic abscess or something similar, i.e. a benign inflammatory condition. However, one has to exclude malignancy and endeavor to do further investigations. Would anyone like to make any more suggestions?

Team B: A mammogram should be performed before proceeding to FNA.

Dr Alagaratnam: Dr Ho, do you think a mammogram is useful in this case?

Dr LWC Ho[§]: First of all, this patient is only 30 years old and she is post-partum, so the breast is very glandular. The mammogram will appear dense and it will be very difficult to pick up any lesion. Another factor to bear in mind is that the patient has a painful mass. You must remember that to take a good mammogram, compression of the breast is necessary which would be rather painful for her. So I would perform an ultrasound instead. If on the ultrasound I saw something suspicious such as echogenicities suggestive of malignant calcification that may be better picked up by mammogram, I would then order a mammogram.

The ultrasound showed a solid well-circumscribed mass (Fig 2). Pregnant breast tissue usually appears more echogenic. There were some hypoechoic areas within it and it did not look like an abscess. The Doppler scan showed no signal within the mass. The only signals were at the periphery of the mass. We usually expect inflammatory cancer to be more vascular. So the overall features are more suggestive of a benign tumour. However, one cannot exclude the possibility of a well-circumscribed type of carcinoma such as a papillary, mucinous, or medullary carcinoma. I would like to point out that the mass is relatively avascular which is against the diagnosis of an inflammatory carcinoma.

Dr Alagaratnam: So on the balance of possibilities, do you think it is benign or malignant?

Dr Ho: I would favour more a benign tumour, although I cannot exclude a carcinoma. We really need to have a tissue diagnosis.

Dr Alagaratnam: We tried to perform an FNA but only got a dry tap. There was no pus.

Dr Chow: We admitted the patient for further investigations to rule out the possibility of an inflammatory carcinoma. The results of other investigations were as follows: the white cell count was normal; haemoglobin was 109 g/L (normal 115 to 155 g/L). So the patient was slightly anaemic which would be consistent with her post-partum status. Liver function and renal function tests were all within normal limits. Her chest X-ray was normal.

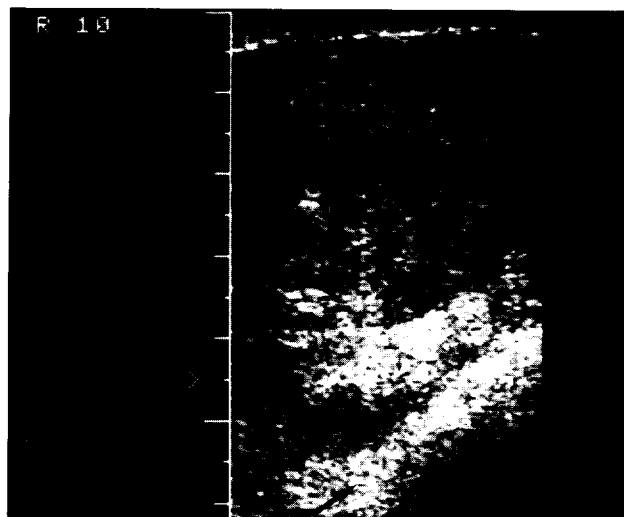


Fig 2. Ultrasound showing a well-circumscribed mass. The adjacent breast tissue is more echogenic

Dr Alagaratnam: Although the skin was red, painful, and warm, the lump was relatively avascular. At this stage, we were still unsure whether we were dealing with a benign or a malignant lesion. We needed to act quickly because if this woman had a malignancy, she needed to have surgery soon. We could not let her wait any longer. Can I ask what we should do then?

Team B: Since the FNA did not show much, a trucut biopsy may be able to yield more histological features.

Dr Alagaratnam: Rather than do a trucut biopsy to get a little more tissue, we preferred to do a wedge biopsy by a circum-areolar incision.

Dr Tam: At operation there appeared indeed to be a big tumour inside. Cutting through, it felt hard and gritty which is consistent with malignancy. There was

[§] Department of Diagnostic Radiology

no pus. It had a cavity but there was no fluid. The surface of the tumour was convex, as one would expect to see in a carcinoma.

Dr Chow: Besides the biopsy of the mass, we also included the skin in the biopsy for histological examination because of our suspicion of an inflammatory carcinoma. The diagnosis of an inflammatory carcinoma can only be made if there is subdermal infiltration of carcinoma cells. So I took a wedge incision underlying the skin and sent it to histology.

Pathological discussion

Dr US Khoo¹: We received a fragment of tissue, most of which was infarcted. You see just the ghost outline of cells. Towards the skin surface there is better preservation and this is the area where pregnancy changes can be seen. At the edge there is granulation tissue, and you also see remnants of tubular structures entrapped which give a spurious appearance of infiltration by deformed tubules. However, immunohistochemical stains for actin confirm the presence of myoepithelial cells, which reassures us as to the absence of malignancy. This is a high-power view of the area showing pregnancy changes (Fig 3). You can see there is increased size of the lobules which have distended acini filled with secretory material. The epithelial cells show vacuolation. There is chronic inflammatory infiltrate surrounding the lobules.

Dr Alagaratnam: You commented on the presence of myoepithelial cells. What is the significance of this finding?

Dr Khoo: In the normal breast, the ducts are lined by two cell types, the epithelial cells and the myoepithelial cells. When you see tubular or acinar structures containing both these cell types, this normally indicates it is benign. This observation is particularly important to help distinguish from tubular carcinoma in which the tubules do not contain myoepithelial cells. It is also a feature we look for in FNA cytology. When we see bipolar stripped nuclei, which represent myoepithelial cells, we are assured that we are dealing with a benign lesion.

Dr Alagaratnam: So your conclusion is that it is an infarction. Why does infarction occur in pregnancy?

Dr Khoo: With enlargement of the breast in pregnancy, the adenoma—which may be a fibroadenoma

or a tubular adenoma—also enlarges and outgrows its blood supply. Infarction of these tumours can be found especially in pregnancy.

Dr Alagaratnam: Can a normal breast undergo infarction?

Dr Khoo: If there is occasion for occlusion of a major vessel supplying the breast, infarction theoretically can occur in a normal breast, but these occasions would be very rare. Adenomas have been reported to become infarcted, especially during pregnancy and lactation.¹ Some people consider lactating adenoma to be an overgrowth of lobules in pregnancy rather than a true neoplasm.^{2,3}

Dr Alagaratnam: So at the end of this we all heaved a sigh of relief, now feeling sure we were dealing with a benign lesion and not a carcinoma. We went ahead with an excision biopsy of the tumour. The whole tumour was shelled out and this is how it looked after excision. It was a large circumscribed tumour, probably benign. Dr Khoo, please tell us what you found on histology.

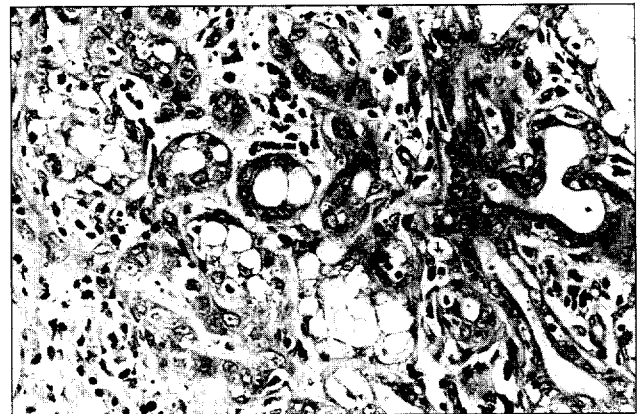


Fig 3. Photomicrograph showing pregnancy changes in the breast (H&E, x 500)

Dr Khoo: The cut surface of the gross specimen showed a well-circumscribed nodule which was lobulated and had the characteristic yellow colour of a lactating adenoma (Fig 4). The histological sections showed a very well-circumscribed and encapsulated tumour (Fig 5). In the centre is the area of infarction which was seen in the earlier biopsy. The adjacent breast showed lactation changes. A reticulin stain was done to show up the remnant basement membrane enclosing each acinus. You can see the well-defined capsule and the outline of closely packed tubules. So this was probably a pre-existing tubular adenoma having undergone lactation changes and infarction.

¹ Department of Pathology

In the previous biopsy I could not comment on the presence of tumour because I just saw infarction and adjacent granulation tissue. Here, I actually see a definite encapsulated mass. In fact, some parts of the adenoma are still viable and show closely packed tubules that are greatly distended due to lactation changes. A high-power view shows distended acini and epithelial cells which have become hobnail-shaped (Fig 6). The adjacent breast shows lactation changes and some areas of involution. There is a lymphoplasmacytic infiltrate and the acini which were completely distended before, are here beginning to involute. We still see some acini with secretion but they will gradually be replaced by connective tissue.

At this point I would like to emphasise the importance of the pathologist always being informed when the patient is pregnant or lactating, especially if an FNA is to be performed. The cytology of the epithelial cells in pregnancy can mimic malignancy. This can also be appreciated on high-power histological section (Fig 3). The cells become enlarged, with an increased nuclear to cytoplasmic ratio, prominent nucleoli, and the cells may even appear discohesive in the smear. Hence, if we do not know the status of the patient on FNA, this becomes a potential pitfall. It could look very much like a carcinoma and be misdiagnosed.

Dr Alagaratnam: So both clinically and even on FNA one may be misled into thinking that this is a carcinoma. What is the final diagnosis?

Dr Khoo: An infarcted lactating adenoma.

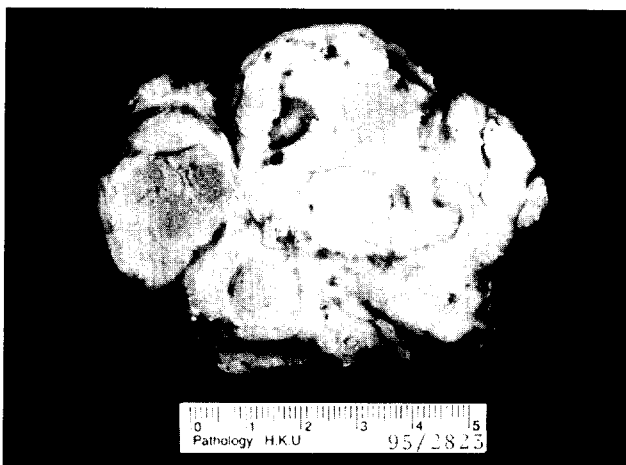

Fig 4. Appearance of the resected nodule. The cut section shows a well-circumscribed lobulated mass measuring 7 cm at its greatest diameter (H&E, x 500)

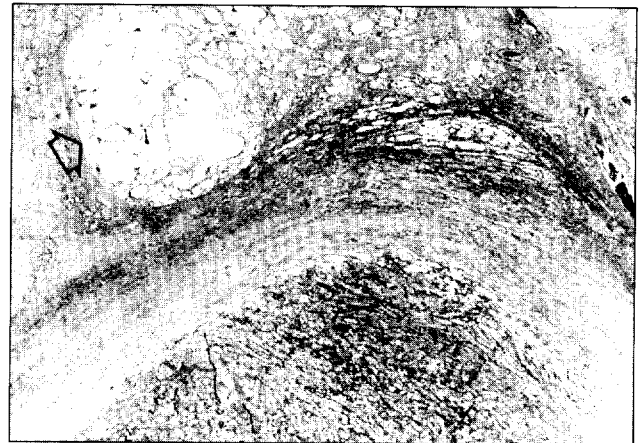


Fig 5. Photomicrograph showing an encapsulated tumour. The adjacent breast shows lactation changes (H&E, x 25)

Dr Alagaratnam: Putting everything together, we had an initially small subareolar nodule. Although the diagnosis on FNA was benign, it probably grew rapidly under the influence of the hormones of pregnancy. It grew so rapidly that it outstripped its blood supply and infarction occurred, resulting in an infarcted lactating adenoma of the breast. How common is this condition?

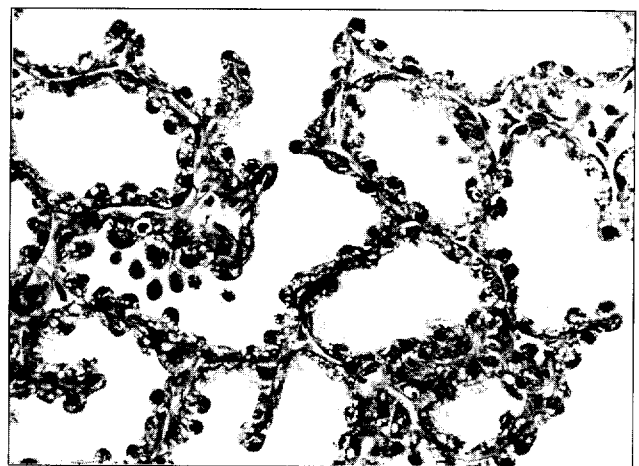

Fig 6. Photomicrograph showing hobnail epithelial cells lining distended acini (H&E, x 500)

Dr Khoo: Approximately 5% of lactating adenomas have been found to be infarcted.⁴

Team B: Could I ask the pathologist, if the FNA does not yield conclusive results or does not support my clinical diagnosis, what is the best approach to take?

Dr Khoo: We now have the multidisciplinary approach to management which includes clinical and

radiological examination followed by FNA for cytological diagnosis. If all three agree and the diagnosis is benign, one may opt to leave the lesion alone or to follow-up. If even one party is suspicious then we must repeat the FNA or do a biopsy, either trucut or excision. There is also the need to consider when a repeat FNA is to be performed. If it is done at too close an interval, the presence of reactive change may render a diagnosis of atypia. The pathologist should be informed whenever a repeat FNA is being done so that possible atypical features may be interpreted in an informed context. Some centres have found a four-week interval between repeat FNAs to be optimal, to allow reactive changes to settle. The adequacy of the material aspirated will also depend on the experience of the aspirator and the size of the lesion. If it is small, there is a greater chance of missing the lesion.

Dr Alagaratnam: FNA results also depend on who is doing it. It has been shown to be much better if the same person is consistently performing it over a year rather than having random FNAs done by different people. This has been conclusively demonstrated in many centres.^{5,6}

Pathological diagnosis:
Infarcted lactating adenoma

References

1. Rickert RR, Rajan S. Localised breast infarcts associated with pregnancy. *Arch Pathol Lab Med* 1974;97:159-62.
2. Slavin JL, Billson VR, Oster AG. Nodular breast lesions during pregnancy and lactation. *Histopathology* 1993;22:481-5.
3. O'Hara MF, Page DL. Adenomas of the breast and ectopic breast under lactational influences. *Hum Pathol* 1985;16:707-12.
4. Tavassoli FA. Benign lesions. In: Tavassoli FA, editor. *Pathology of the breast*. New York: Elsevier, 1992:79-153.
5. Dixon JM, Anderson TJ, Lamb JL, Nixon SJ, Forrest AP. Fine needle aspiration cytology: in relationship to clinical examination and mammography in the diagnosis of a solid breast mass. *Br J Surg* 1984;71:593-6.
6. Barrows GH, Anderson TJ, Lamb JL, Dixon JM. Fine needle aspiration of breast cancer: relationship of clinical factors to cytology results in 689 primary malignancies. *Cancer* 1986;58:1493-8.

HKMJ 1995;1:253-257