

Source of tubercle bacilli in cervical lymph nodes: A prospective study

S. K. LAU,* S. KWAN,† J. LEE,† W. I. WEI* (Hong Kong)

Abstract

A prospective study searching for associated mycobacterial infection of the upper aerodigestive tract in patients with cervical tuberculous lymphadenitis (TBLN) was carried out. One hundred and thirteen patients with a clinical suspicion of cervical TBLN were included. All patients had a physical examination of the upper aerodigestive tract. Routine endoscopy and biopsy of the nasopharynx were performed. All of them had surgery to the cervical lymph node. Seventy-five patients had histologically confirmed cervical TBLN. Culture of the lymph node specimen showed *Mycobacterium tuberculosis* in 68 (90 per cent). In 45 (60 per cent) patients with cervical TBLN the primary foci of infection could not be found. Twenty-nine (39 per cent) had radiographic evidence of active or healed pulmonary tuberculosis. Sputum culture from two patients showed *Mycobacterium tuberculosis*. Five patients (six per cent) had tuberculous nasopharyngitis. In one of them (one per cent) the tuberculous nasopharyngitis was primary as no other evidence of mycobacterial infection was found. In the present study, mycobacterial infection of other parts of the upper aerodigestive tract was not found.

Introduction

Mycobacterial infection of the cervical lymph node is the commonest form of extrapulmonary tuberculosis. The route of mycobacterial infection of the cervical lymph nodes is not clear. A usual event after infection by *Mycobacterium tuberculosis* is the spread from the primary focus to the regional lymph nodes. For cervical tuberculous lymphadenitis (TBLN) in the adult it is accepted that the lung is the primary focus (Newcombe, 1971; Tomblin and Roberts, 1979). About 20 to 40 per cent of cervical TBLN in adult is associated with pulmonary tuberculosis (Dwyer *et al.*, 1987; Alleva *et al.*, 1988). It is however rare for the pulmonary foci to be active (Newcombe, 1971; Siu *et al.*, 1983). Therefore the manifestation of cervical TBLN may be a reactivation of previous infection of the lymph nodes (Powell, 1988). In the upper aerodigestive tract, a few anatomical regions such as the tonsil (Wilmot *et al.*, 1957; Deitel *et al.*, 1989) or the nasopharynx (Sim and Ong, 1972) are considered as the possible portal of entry of the mycobacteria. Tuberculous nasopharyngitis can be the primary foci or secondary to pulmonary infection. Primary tuberculous nasopharyngitis spreading to cervical lymph nodes has been reported. Review of the literature does not show any incidence or information regarding associated tuberculous infection in patients with cervical TBLN. The present prospective study was carried out to determine the incidence of any associated infection of the upper aerodigestive tract in patients with cervical TBLN.

Materials and methods

Patients seen in Queen Mary Hospital with a clinical suspicion of cervical TBLN were included in this study. The patients had a physical examination of the head and neck region and the upper aerodigestive tract. Any suspicious area was biopsied. Sputum from patients was stained for acid-fast bacilli (AFB) by the Ziehl-Neelsen technique. Sputum was cultured for mycobacteria. Radiography of the chest was performed. A Mantoux test with one international tuberculin unit was performed on each patient; the result was read at 72 hours. The patients underwent a nasendoscopic examination with a Storz 4 mm 0° rigid endoscope. Fiberoptic laryngo-broncho-esophagoscopy was performed to rule out malignancy of the upper aerodigestive tract. The patients had surgery to the cervical mass. The surgical specimen was examined for (i) Ziehl-Neelsen staining for AFB; (ii) culture for mycobacteria; and (iii) histology.

Result

Between July 1987 and January 1990, 75 patients were diagnosed to have cervical TBLN. All of them had undergone surgery to the cervical lymph node. Among the 75 patients, 59 had excisional biopsy of the cervical lymph node. Eight had incision and drainage of a cervical abscess and the remainder had excision of the abscess. The mean age was 32 years ranging from seven to 79. Twenty-seven were male and 48 were female. Five

*Department of Surgery, University of Hong Kong, Queen Mary Hospital, Hong Kong.

†Tuberculosis and Chest Service, Grantham Hospital, Hong Kong.

Accepted for publication: 25 February 1991.

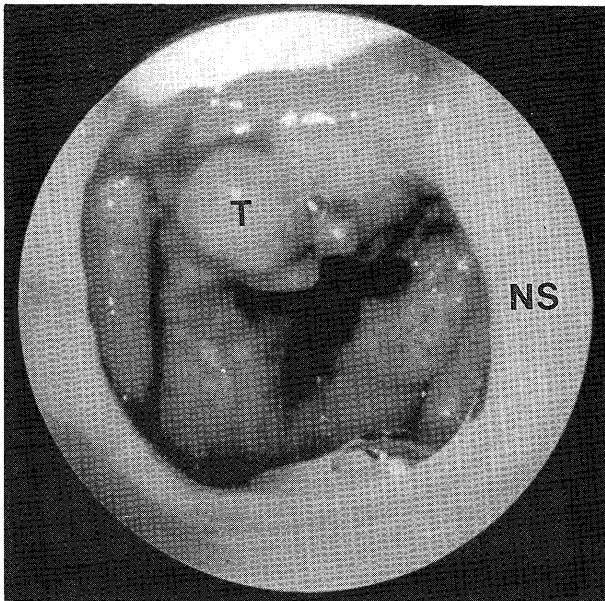


FIG. 1

Endoscopic view of nasopharynx showing a tuberculoma (T) in the roof (NS = nasal septum).

patients had been treated for pulmonary tuberculosis in the past and five had active pulmonary tuberculosis. Seven patients had recurrent cervical TBLN as they had been treated previously with anti-tuberculous drugs for cervical TBLN. Physical examination of the upper aerodigestive tract using a post-nasal mirror showed a suspicious mass in the nasopharynx in 11 patients. No other pathology was found in the upper aerodigestive tract. The chest X-ray in 24 patients showed fibrosis or calcification in the apex of the lung indicating healed pulmonary tuberculosis. The chest X-rays of five patients showed either consolidation of the lung or hilar lymph node enlargement, both suggestive of active pulmonary tuberculosis. A direct smear of the sputum with Ziehl-Neelsen staining for AFB was negative in all patients. Sputum culture showed *Mycobacteria tuberculosis* in two patients both of whom showed evidence of active pulmonary tuberculosis on chest X-ray. The skin reaction to one international tuberculin unit was positive in all but two patients; the mean reaction size was 21 mm ranging from 12 to 45 mm. Rigid endoscopy of the nose and nasopharynx was performed in all 75 patients (Fig. 1). A fiberoptic laryngo-tracheo-bronchoscopy and oesophagoscopy were performed in 22. Inflamed adenoid tissue was found in 11 patients. The rest of the upper aerodigestive tract was normal. Biopsy of the nasopharynx was carried out in all patients. Histologically proven tuberculous infection was found in five nasopharyngeal biopsies (Fig. 2). In four out of the above five nasopharyngeal biopsies, AFB was demonstrated by Ziehl-Neelsen staining. Four of the five patients with tuberculous nasopharyngitis had also radiographic changes of pulmonary tuberculosis. The remaining one was regarded as suffering from primary tuberculous nasopharyngitis spreading to the cervical lymph node. None of these five patients had nasal complaints even though the diagnosis of tuberculous nasopharyngitis was revealed to them in retrospect.

Direct smear of the specimen of lymph node showed

AFB in 40 (53 per cent); culture of the lymph node specimen yielded *Mycobacterium tuberculosis* in 68 (90 per cent).

Discussion

The present study revealed that 29 (39 per cent) of the 75 patients with cervical TBLN had pulmonary tuberculosis as shown by the chest X-ray changes. In five of them (6 per cent), the pulmonary tuberculosis was regarded as active either because of positive *Mycobacterium tuberculosis* culture of the sputum or because of chest X-ray evidence. In these 29 patients, the mycobacteria probably spread to the cervical lymph node by lymphatic or by the haematogenous route blood from the pulmonary foci. In the 24 patients with old pulmonary tuberculosis, it is not known what factors precipitated a reactivation of the mycobacterial infection in the cervical lymph node. Four of them had tuberculous nasopharyngitis which was regarded as secondary in the presence of pulmonary foci. In the remaining 46 patients with cervical TBLN, no pulmonary foci were detected. The examination of the upper aerodigestive tract with indirect mirror or endoscope failed to identify any primary foci in most patients except in one who had primary tuberculous nasopharyngitis. The primary site of mycobacterial infection in the remaining 45 patients remains unknown. It is possible that the primary foci in lung or upper aerodigestive tract were too small to be detected or had healed completely without any residual radiological change. It is not uncommon to find a normal chest radiograph after adequate chemotherapy of pulmonary tuberculosis. The pulmonary focus is more favoured as the primary site of infection because 39 per cent of the patients had a chest radiological abnormality.

Nasopharyngeal carcinoma and tuberculosis are common causes of cervical lymphadenopathy in this part of the world. It may not be possible to differentiate between a metastatic lymph node and a tuberculous one by physical examination (Chan *et al.*, 1989). Furthermore, the primary nasopharyngeal carcinoma can be submucosal (Sham *et al.*, 1989). It is essential, therefore to examine and biopsy the nasopharynx of every patient with cervical lymphadenopathy in this part of the world. The present study shows that five patients (6 per cent) with cervical TBLN had tuberculous nasopharyngitis. Four of them had evidence of pulmonary TB infection and the fifth had none; in this latter patient the nasopharynx may be the primary site of infection. The mycobacteria spread to the drainage lymph node in the neck through the lymphatics.

Such findings of primary tuberculous nasopharyngitis spreading to cervical lymph nodes have been reported previously (Sim and Ong, 1972). They reported 15 patients with tuberculous nasopharyngitis. In seven patients the nasopharynx was considered to be the primary site of infection as there was no evidence of pulmonary tuberculosis. In five of the seven, infection had spread to the cervical lymph nodes. Primary tuberculous nasopharyngitis is very rare (Martinson, 1967). The mode of infection of the nasopharynx by *Mycobacterium tuberculosis* is probably by inhalation. It is suggested that the adenoid may have harboured the tubercle bacilli for some time and under certain conditions clinical disease is precipitated.

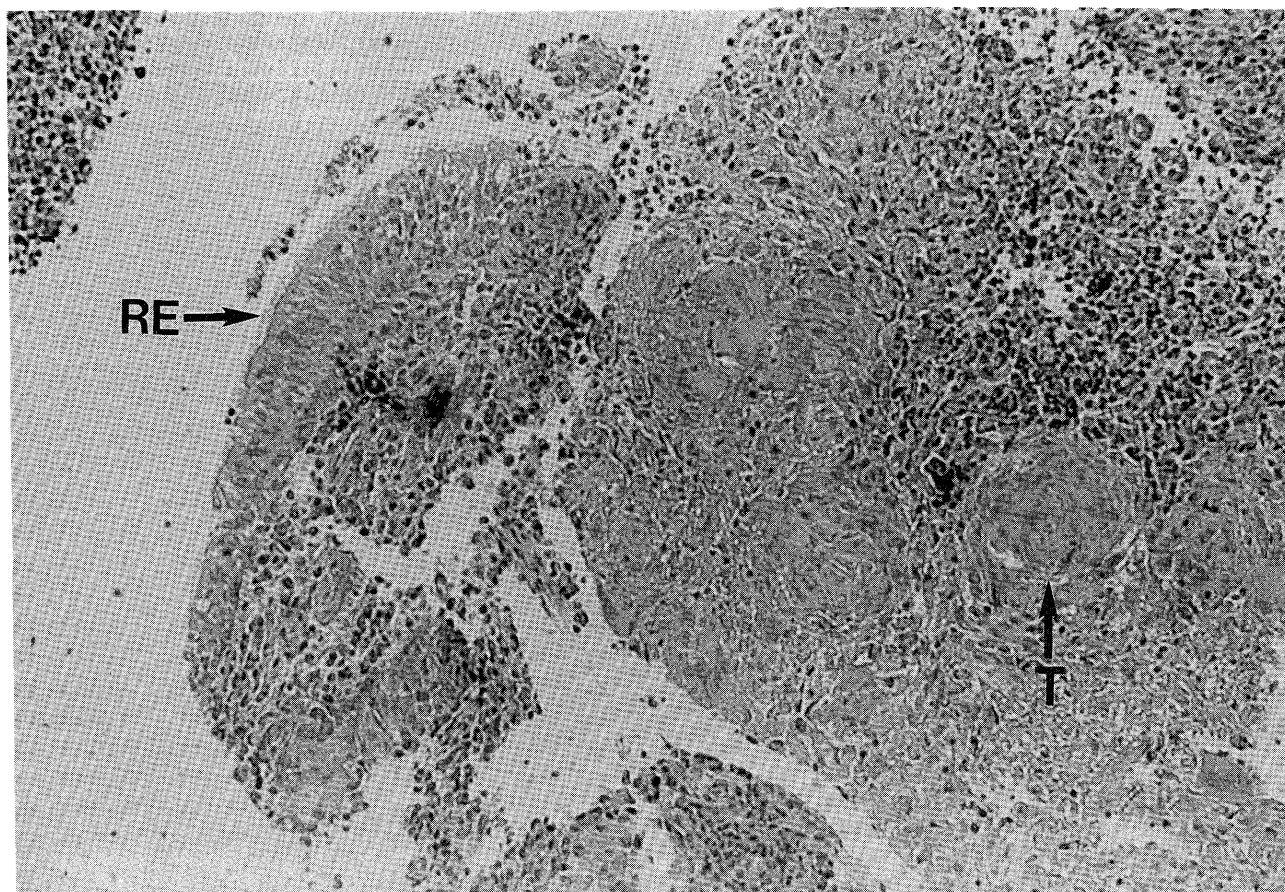


FIG. 2

Photomicrograph of a nasopharyngeal biopsy of a patient with cervical TBLN showing respiratory epithelium (RE) and tubercle (T) (Haematoxylin and eosin stain $\times 160$).

The tonsil has also been considered as a route of infection in children (Wilmot *et al.*, 1957). In our study, however, mycobacterial infection was not found in other parts of the upper aerodigestive tract except the nasopharynx. This is in accordance with another study which also found that mycobacterial infection of the upper aerodigestive tract was rare (Rohwedder, 1974). It is accepted that the tuberculosis of the upper respiratory tract is secondary to pulmonary infection. The respiratory tract mucosa is infected by sputum heavily laden with tubercle bacilli.

The clinical importance of the present study lies in the treatment of cervical TBLN (Campbell, 1990). It is generally accepted that antituberculous chemotherapy is the definite modality of treatment of TBLN. This is true even after complete excision of cervical TBLN (British Thoracic Society Research Committee 1988). The finding of relatively asymptomatic associated mycobacterial infection such as pulmonary or nasopharyngeal tuberculosis in the present study further supports this view.

Conclusion

In 60 per cent of the patients with cervical TBLN, a primary focus of infection could not be found. Thirty-nine per cent of cervical TBLN were associated with old or active pulmonary infection. It is highly suggestive that the pulmonary foci are the primary infection in cervical TBLN. In rare cases (one per cent), the cervical TBLN is

secondary to a primary mycobacterial infection of the nasopharynx. Six per cent of the patients with cervical TBLN had tuberculous nasopharyngitis. The finding of associated mycobacterial infection in lung or nasopharynx supports the policy of antituberculous chemotherapy even after complete excision of TBLN.

References

- Alleva, M., Guida, R. A., Romo, T., Kimmelman, C. P. (1988) Mycobacterial cervical lymphadenitis, a persistent diagnostic problem. *Laryngoscope*, **98**: 855-857.
- British Thoracic Society Research Committee (1988) Short Course chemotherapy for lymph node tuberculosis: Final report at five years. *British Journal of Diseases of the Chest*, **82**: 282-284.
- Campbell, I. A. (1990) The treatment of superficial tuberculous lymphadenitis. *Tubercle*, **71**: 1-3.
- Chan, M. K. M., McGuire, L. J., Lee, J. C. K. (1989) Fine needle aspiration cytodiagnosis of nasopharyngeal carcinoma in cervical lymph nodes. A study of 40 cases. *Acta Cytologica*, **33**: 344-350.
- Deitel, M., Bendago, M., Krajden, S., Ronald, A. C., Borowy, Z. J. (1989) Modern management of cervical scrofula. *Head and Neck*, **11**: 60-66.
- Dwyer, D. E., Macleod, C., Collignon, P. J., Sorrell, T. C. (1987) Extrapulmonary tuberculosis—a continuing problem in Australia. *Australian and New Zealand Journal of Medicine*, **17**: 507-511.
- Martinson, F. D. (1967) Primary tuberculosis of the nasopharynx in a Nigerian. *Journal of Laryngology and Otology*, **81**: 229-233.
- Newcombe, J. F. (1971) Tuberculous cervical lymphadenopathy. *Postgraduate Medical Journal*, **47**: 713-717.
- Powell, D. A. (1988) Tuberculous lymphadenitis. In *Tuberculosis 2nd edition* (David Schloss Berg, eds.) Springer-Verlag: New York p 99-105.

- Rohwedder, J. J. (1974) Upper respiratory tract tuberculosis 16 cases in a general hospital. *Annals of Internal Medicine*, **80**: 708-713.
- Sham, J. S. T., Wei, W. I., Kwan, W. H., Chan, C. W., Choi, P. H. K., Choy, D. (1989) Fiberoptic endoscopic examination and biopsy in determining the extent of nasopharyngeal carcinoma. *Cancer*, **64**: 1838-1842.
- Sim, T., Ong, B. H. (1972) Primary tuberculosis the nasopharynx. *Singapore Medical Journal*, **13**: 39-43.
- Siu, K. F., Ng, A., Wong, J. (1983) Tuberculous lymphadenopathy. A review of results of surgical treatment. *Australian and New Zealand Journal of Surgery*, **53**: 253-257.
- Tomblin, J. L., Roberts, F. J. (1979) Tuberculous cervical lymphadenitis. *Canadian Medical Association Journal*, **121**: 324-330.
- Wilmot, T. J., James, E. F., Reilly, L. V. (1957) Tuberculous cervical adenitis. *Lancet*, **2**: 1184-1187.

Address for correspondence:

Dr Sai-Kit Lau,
Department of Surgery,
University of Hong Kong,
Queen Mary Hospital,
Hong Kong.

Key words: Tuberculosis; Lymphadenitis