

RADIOLOGICAL CONFERENCE

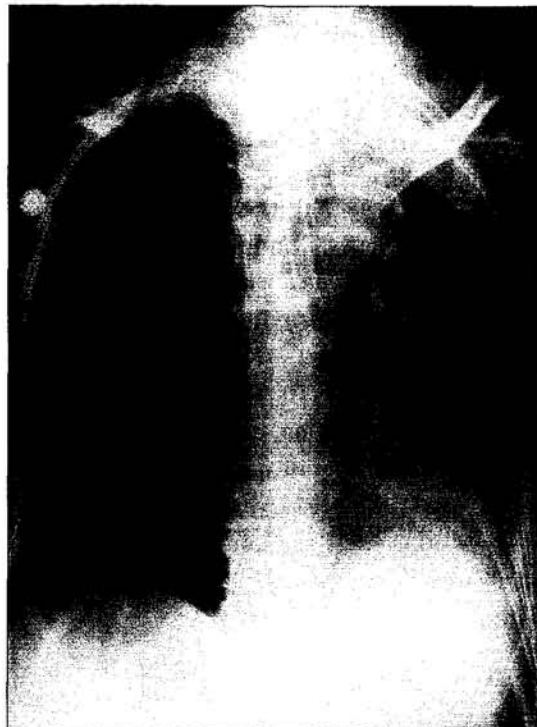
Clinical History:

A 69-year-old woman suffering from nasopharyngeal carcinoma underwent a difficult but eventually successful intubation in the intensive care unit. She was subsequently found to have poor oxygen saturation despite administration of 100% oxygen. Serial frontal chest radiographs were obtained with the first radiograph (**Figure 1**) taken 20 hours prior to the second radiograph (**Figure 2**).

Figure 1: Frontal chest radiograph

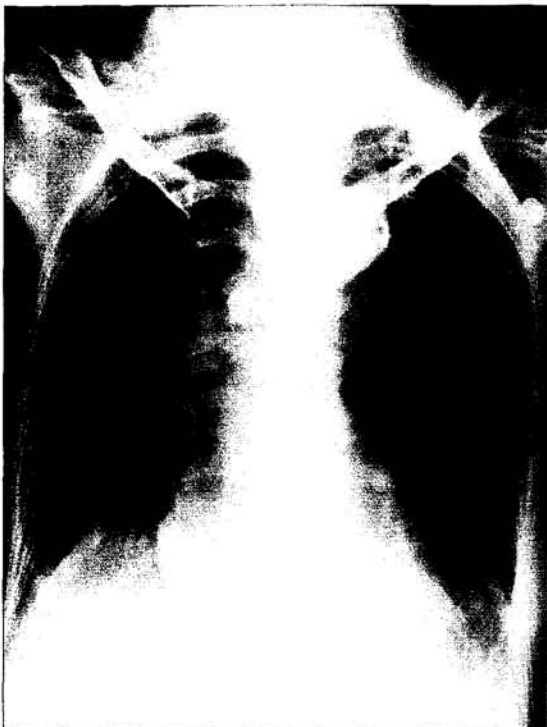

Figure 2: Frontal chest radiograph, taken 20 hours later



Answer
on
page 514

What is the diagnosis?

- a) Left pleural effusion
- b) Left upper lobe collapse
- c) Right tension pneumothorax
- d) Left lower lobe collapse
- e) Progressive massive fibrosis

This radiology case was prepared by:

Dr. L.L.S. Wong,
Senior Medical Officer.
Professor W.C.G. Peh,
Department of Diagnostic Radiology,
The University of Hong Kong,
Queen Mary Hospital.

RADIOLOGICAL CONFERENCE

Answer:

- b) Left upper lobe collapse

Radiological findings

The first chest radiograph (Figure 3) shows an endotracheal tube in the trachea with its tip located about 4cm proximal to the carina. Both lungs are of symmetrical expansion and density. The subsequent chest radiograph (Figure 4) shows diffuse opacity of the left lung only. There is loss of left lung volume as

Figure 3: Same figure as Figure 1 with addition of arrows. Endotracheal tube is in the trachea with its tip (arrowheads) 4 cm proximal to the carina (large arrow). There is a calcified density in the right tracheobronchial region, compatible with a calcified lymph node (open arrow). Aortic knuckle (short white arrow) and the left cardiac border (small white arrows) are sharp and distinct

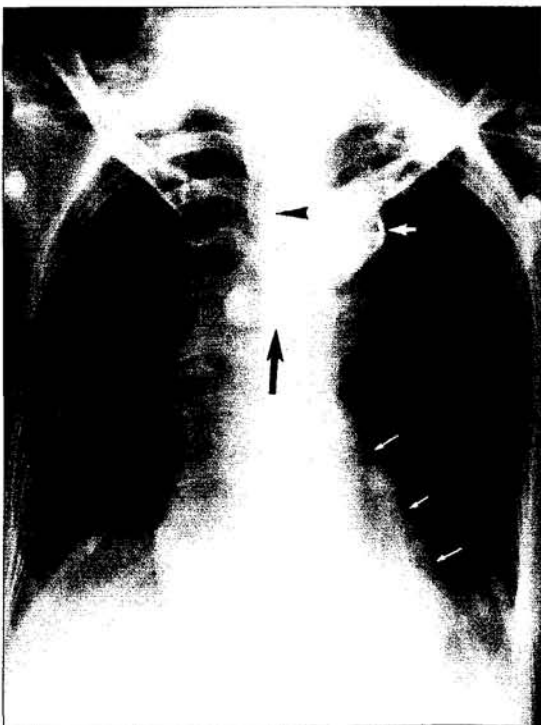
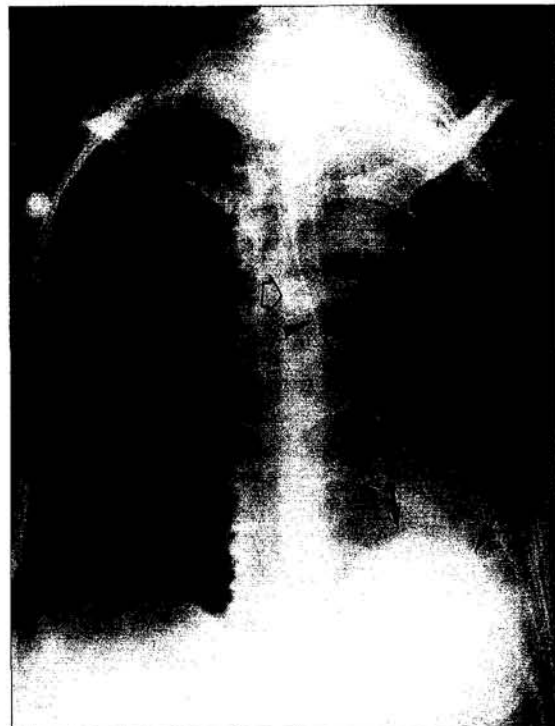


Figure 4: Same figure as Figure 2 with addition of arrows. Malplaced endotracheal tube with its tip (arrowheads) in the left lower lobe bronchus. There is shift of the mediastinum and the calcified lymph node (open arrow) to the left. The left hemidiaphragm is raised but still distinct (arrows). The aortic knuckle and left cardiac border are obscured



evidenced by left hemidiaphragm elevation, marked shift of mediastinal structures to the left side, and mild crowding of the left ribs. The outline of the left hemidiaphragm is still visible. The left cardiac border is obliterated and the aortic knuckle is obscured. In addition, there is shift of the calcified subcarinal lymph node to the left, compared with the earlier radiograph. The right lung is normal. Chest radiographic appearances are typical of those of a left upper lobe collapse.

The cause of left upper lobe collapse is due to a malpositioned endotracheal tube which, in the second radiograph, is located in the left lower lobe bronchus. The endotracheal tube was withdrawn and a repeat chest

RADIOLOGICAL CONFERENCE

radiograph (**Figure 5**) shows satisfactory positioning of the endotracheal tube within the trachea. There is resolution of the left-sided lung opacity, particularly in the upper zone. There remains a small left pleural effusion. Appearances are those of re-inflation of a previously-collapsed left upper lobe.

Discussion

Partial or complete loss of volume of a lung is referred to as collapse or atelectasis.¹ Types of atelectasis include: obstructive/resorptive (obstructed bronchus with resorption of gases in the alveoli which are not

replenished), compressive (intrapulmonary abnormalities that compress surrounding lung e.g. large lung mass), passive (developing from changes in intrapleural pressure e.g. air or fluid in the pleural space), cicatrizing (abnormally stiff lung with decreased lung compliance e.g. pulmonary fibrosis, bronchiectasis) and adhesive (deficiency of surfactant with collapse of alveoli e.g. hyaline membrane disease or respiratory distress syndrome). Airway obstruction is by far the most common cause of atelectasis.² The causes are summarised in **Table 1**.³

In children, foreign body or mucus plugging are common causes while in older patients, bronchogenic carcinoma should be considered first. In this case, the left upper lobe orifice was obstructed by the inflated air-cuff at the distal end of the endotracheal tube. There was no collapse of the right lung as there was no right bronchial tree obstruction, hence air could still enter the lung via the remaining space between the trachea and the endotracheal tube (**Figure 6**).

Figure 5: Repeat chest radiograph after withdrawal of the endotracheal tube. The tip of endotracheal tube (arrowheads) is repositioned in the trachea proximal to the carina (large arrow). There is resolution of the left upper lobe collapse with part of the aortic knuckle (short white arrow) and left cardiac border being visible again. A small left pleural effusion is seen

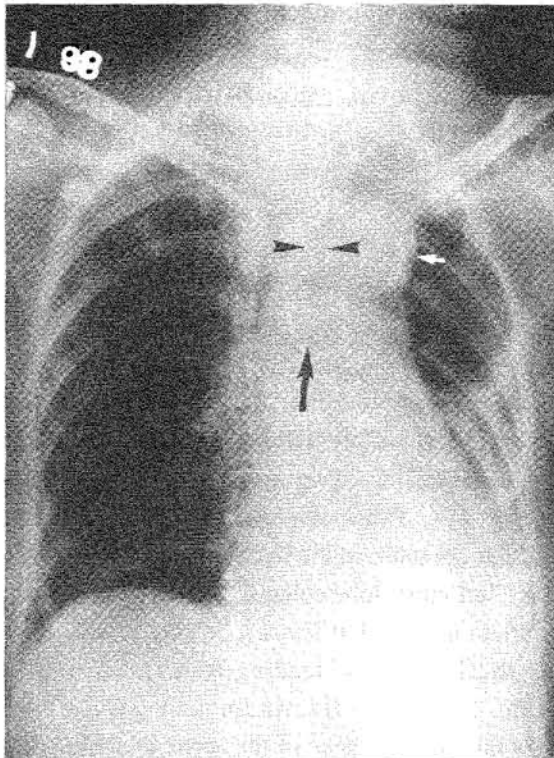


Table 1: Causes of bronchial stenosis or occlusion

Intra-luminal

1. Foreign body – air trapping is more common than atelectasis; lower lobe is most frequently affected.
2. Mucus plug from asthma or cystic fibrosis
3. Misplaced endotracheal tube
4. Aspergillosis

Arising from the bronchial wall

1. Carcinoma of the bronchus
2. Bronchial adenoma
3. Sarcoid granuloma
4. Fibrosis
5. Bronchial atresia
6. Fractured bronchus

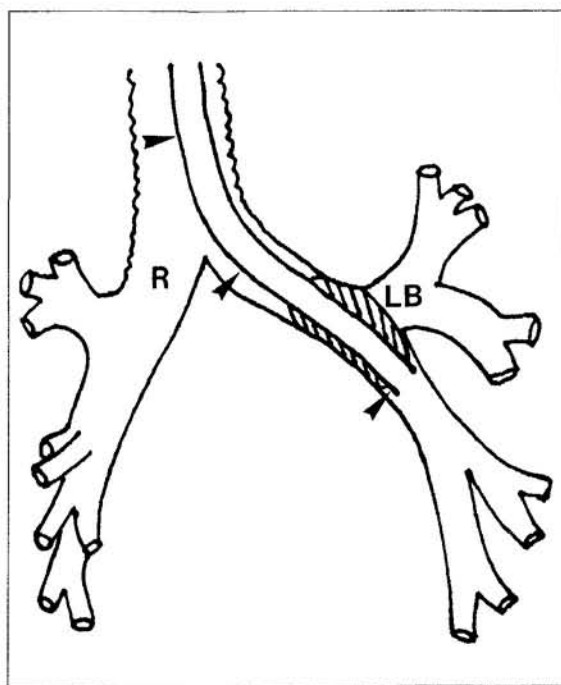
Extra-luminal

1. Lymph node
2. Mediastinal tumour
3. Enlarged left atrium
4. Vascular – aortic aneurysm or anomalous vessels

RADIOLOGICAL CONFERENCE

The radiological appearances in pulmonary collapse depends upon on the mechanism of collapse, degree of collapse, presence or absence of consolidation, and pre-existing state of the pleura. Radiological signs of collapse may be direct or indirect. Direct signs include displacement of interlobar fissures, loss of aeration with increased density of the collapsed lung, and crowding of vascular and bronchial tree. Indirect signs are those resulting from compensatory changes occurring in response to volume loss and include elevation of the diaphragm, mediastinal shift, hilar displacement, crowding of ribs, cardiac rotation, and compensatory hyperinflation of the normal lung.¹ On occasion, the change in position of an abnormal structure such as a calcified granuloma may also provide additional clues to the diagnosis,² such as in this case.

Figure 6: Line drawing illustrating the position of the endotracheal tube (arrow-heads) within the left bronchus. The inflated air-cuff (hatched lines) around the tip of the endotracheal tube obstructs the orifice of the left upper lobe bronchus (LB), causing the left upper lobe collapse. Right main bronchus is labelled (R)



Another important radiographic sign in the interpretation of chest radiographs is the *silhouette sign* described by Felson. On a chest radiograph, a soft tissue density structure will have clear and sharp margins provided that their interfaces with the adjacent air in the lung are reasonably smooth and tangential to the x-ray beam. The *silhouette sign* indicates loss of the silhouette of any of these borders caused by an adjacent opacity of similar density. Thus, when air in the lung at a soft tissue-air interface is removed (e.g. atelectasis) or substituted (e.g. consolidation), the radiographic boundary will disappear. On the other hand, if the interface is merely overlapped by a remote opacity, then, given appropriate radiographic factors, the radiographic boundary remains clearly visible within the new opacity. Thus, using this radiographic sign, normal structures and obvious abnormal opacities can be localised.⁴

In left upper lobe collapse, there is anterior displacement of the entire oblique fissure which becomes oriented in a plane almost parallel to the anterior chest wall. This is apparent on the lateral projection as an elongated opacity extending from the apex and reaching or almost reaching the diaphragm. This opacity is bordered posteriorly by the oblique fissure which appears sharp as it is tangential to the x-ray beam. In the frontal projection, however, the oblique fissure is almost perpendicular to the x-ray beam. As a result, the increased opacity of the collapsed left upper lobe does not have a sharp border as the oblique fissure is not tangential to the x-ray beam. Instead, left upper lobe collapse appears as a veil-like opacity with a hazy margin spreading outwards, upwards and downwards from the left hilum.⁴

In addition, the left cardiac border and aortic knuckle which are normally outlined by air in the adjacent lung become obliterated or "silhouetted" by the increased opacity of the collapsed left upper lobe lying adjacent to these structures. Pulmonary vessels that are seen through this opacity are those in the hyperinflated left lower lobe.³ In severe left upper lobe collapse, however, compensatory hyperinflation of the left lower lobe may intrude medially and at the lung apex, leading to a translucent band adjacent to the mediastinum and giving rise to radiographic reappearance of the aortic knuckle border.^{1,4}

RADIOLOGICAL CONFERENCE

Left pleural effusion

Pleural effusion is one of the causes of increased density of a hemithorax. When a patient is supine, the effusion gravitates posteriorly, producing a generalised increased density with an apical cap of fluid.¹ The mediastinum remains central in a small effusion but becomes displaced away from the opacified hemithorax in a large effusion. A large effusion with no mediastinal shift, however, implies underlying lung collapse which in an older person, is often secondary to a bronchial carcinoma.³ In this case, the mediastinal shift towards the hemithorax is contrary to that associated with pleural effusion, excluding this diagnosis.

Right tension pneumothorax

In tension pneumothorax, there is air-trapping in the pleural cavity as air enters the pleural space on inspiration but does not leave on expiration (ball-valve effect). As intrapleural pressure increases, this may lead to massive displacement of the mediastinum away from the side of pneumothorax, compression of the ipsilateral lung (passive atelectasis), and depression of the ipsilateral hemidiaphragm. The ipsilateral lung can be seen outlined by a sharp white line of visceral pleura separated from the chest wall by radiolucent pleural space devoid of lung markings.¹ In this case, no radiological sign of pneumothorax is noted in the relatively more radiolucent right hemithorax to account for the left mediastinal shift. The diagnosis of pneumothorax can be excluded.

Left lower lobe collapse

In left lower lobe collapse, radiographic signs of left lung volume loss will be similar to that of left upper lobe collapse except for left tracheal shift which is more commonly associated with the latter. On the frontal radiograph, left lower lobe collapse does not give rise to

veil-like opacity described in left upper lobe collapse, but appears as a triangular opacity behind the heart. The lateral border of this triangular opacity is formed by the oblique fissure which appears sharp as it moves posteriorly and inferomedially,¹ and becoming tangential to the x-ray beam. The apex of the triangular opacity points to the left hilum which is usually depressed and rotated medially. The descending thoracic aorta and parts of the hemidiaphragm which are normally outlined by the aerated lung are silhouetted by the left lower lobe collapse. In contrast, the aortic knuckle, which is relatively far away, remains sharply outlined by air in the left upper lobe. Occasionally, left lower lobe collapse can be obscured by the heart shadow and a penetrated frontal view would be useful to confirm this diagnosis. Although there is loss of left lung volume, the other radiographic features are typical of left upper lobe collapse which are distinct from that of left lower lobe collapse.

Progressive massive fibrosis

This is a complication of pneumoconiosis (e.g. silicosis). There is rapid development of massive, ill-defined, dense, oval or round shadows which are bilateral and symmetrical in the upper two-thirds of the lungs. These changes are superimposed on background of small nodules of pneumoconiosis. The absence of these features in this case excludes the diagnosis. ■

References

1. Rubens MB. The pleura - collapse and consolidation. In: Sutton D (ed). *A Textbook of Radiology and Imaging*. 5th ed. Churchill Livingstone, New York, 1992;pp371-372,379-389.
2. Reed JC. *Chest Radiology: Plain Film Patterns and Differential Diagnoses*. 3rd ed. Mosby Year Book, St Louis, 1991;pp167-194,209-228.
3. Chapman S, Nakielny R. *Aids to Radiological Differential Diagnosis*. 3rd ed. London: W.B. Saunders. 1995;pp110-118.
4. Wilson AG. 1) Interpreting the Chest Radiograph. 2) Large Airway Obstruction. In: Grainger RG, Allison DJ (eds). *Diagnostic Radiology*. 2nd ed. Churchill Livingstone, Edinburgh, 1992;pp150-151,254-255.