

Repair of Salmonella mycotic aneurysm of the paravisceral abdominal aorta using in situ prosthetic graft

A. C. W. TING, S. W. K. CHENG

Salmonella infection of the abdominal aorta is associated with a high mortality and morbidity, especially when the paravisceral segment is involved. The presentation may be vague and a high index of suspicion is required in order to make the diagnosis early so that prompt treatment can be instituted. Imaging techniques such as computed tomography and angiogram are useful in arriving at a diagnosis as well as planning of operation. The management of a patient with Salmonella mycotic aortic aneurysm includes potent antibiotics, adequate debridement and revascularization. The method of revascularization, *in situ* bypass or extra-anatomic bypass, has been the subject of controversy. *In situ* bypass involves placing a graft in an infected field with potentially fatal graft infection, while extra-anatomic bypass has the problem of inferior patency and the necessity of a future reconstruction. We report here a patient with Salmonella mycotic aneurysm of the paravisceral abdominal aorta successfully treated with *in situ* prosthetic bypass graft.

KEY WORDS: Salmonella infections - Aortic aneurysm microbiology - Aneurysm, infected - Blood vessel prosthesis.

*From the Department of Surgery
The University of Hong-Kong
Queen Mary Hospital, Hong-Kong*

The management of a patient with Salmonella mycotic aortic aneurysm includes potent antibiotics, adequate debridement and revascularization. The method of revascularization, *in situ* bypass or extra-anatomic bypass, had been the subject of controversy.³⁻⁴ *In situ* bypass involves placing a graft in an infected field with potentially fatal graft infection, while extra-anatomic bypass has the problem of inferior patency and the necessity of a future reconstruction. We report here a patient with Salmonella mycotic aneurysm of the paravisceral abdominal aorta successfully treated with *in situ* prosthetic bypass graft.

Case report

A 66-year-old previously healthy man was admitted with a 2-week history of fever, malaise and anorexia. There was no recent travel history. Urine microscopy revealed increased white cell counts and cultures grew Group D Salmonella. He was treated initially as a case of urinary tract infection by Cefuroxime. Renal function test, ultrasound of the kidneys and intravenous urogram were normal. He was transferred to our institution one week later because of persistent fever.

Physical examination on admission revealed an ill-appearing man with a fever of 38.5°C. There was some vague epigastric tenderness but no obvious palpable abdominal mass. Laboratory investigation showed hemoglobin of 10.7 g/dl, white cell count of $13 \times 10^9/L$, platelet count of $402 \times 10^9/L$. Erythrocyte sedimentation rate was 135 mm/hr. Blood culture, urine and stool cultures showed no growth. Widal test was positive with a T_0 titer of 1:800. Ultrasound examination of the abdomen and subsequent computed tomography (Fig. 1) and

Salmonella infection of the abdominal aorta is rare. Less than a hundred cases have been reported in the literature.^{1,2} Involvement of the paravisceral segment of the abdominal aorta poses a particular problem because of the need to maintain blood flow to these vital branches after reconstruction.

Salmonella aortitis is associated with a high mortality and morbidity because of the frequent delay in diagnosis as a result of the non-specific signs and symptoms. More than half of the patients presented with aortic rupture, with an overall operative mortality rate of 41% in those patients treated surgically.²

Authors' address: A. C. W. Ting, Department of Surgery, The University of Hong-Kong, Queen Mary Hospital, Pokfulam, Hong-Kong.

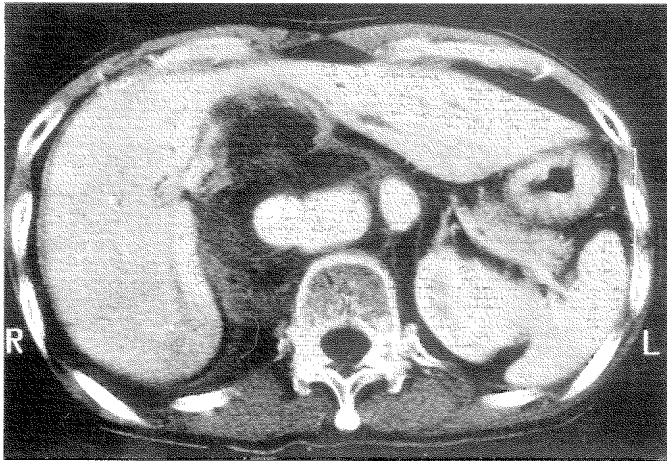


Fig. 1.—Preoperative computed tomography of the abdomen showing a mycotic paravisceral aortic aneurysm.

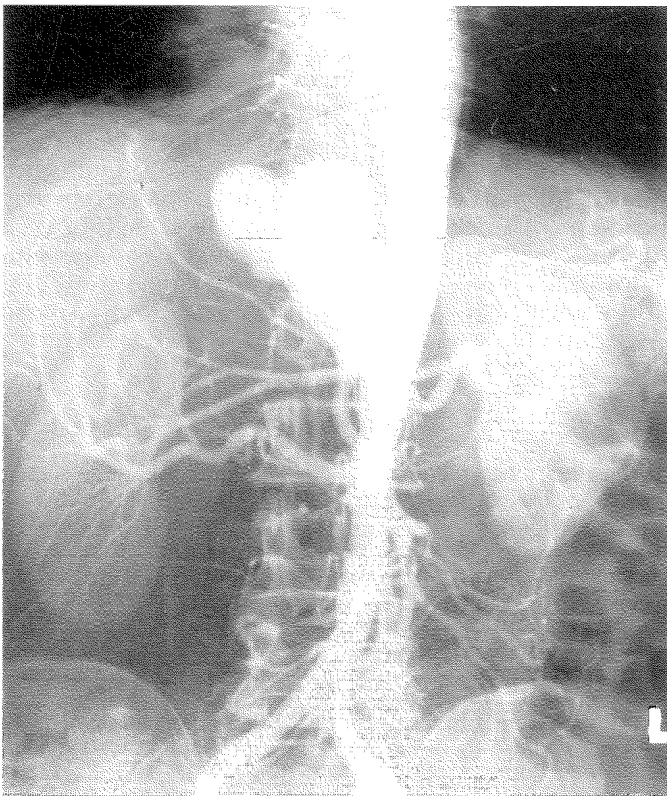


Fig. 2.—Preoperative angiogram showing the mycotic paravisceral abdominal aortic aneurysm.

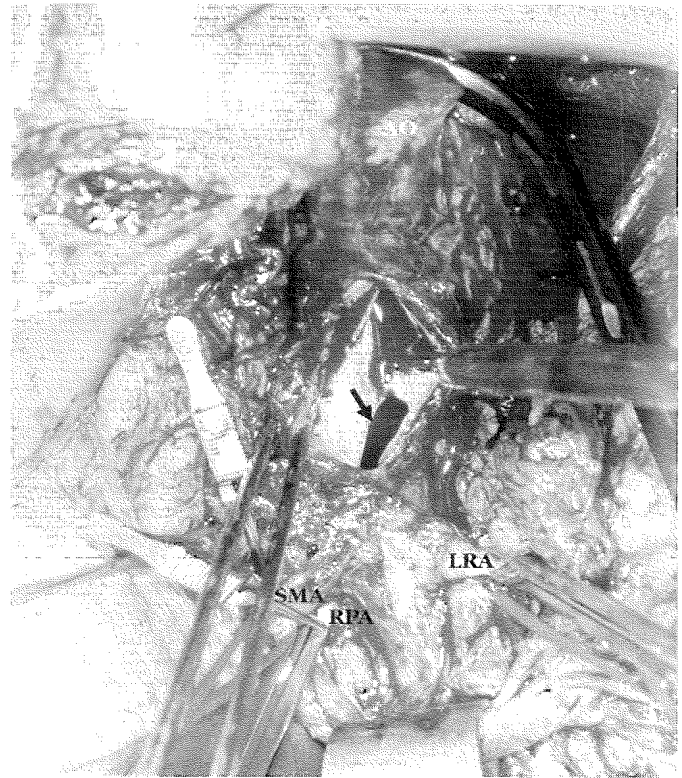


Fig. 3.—Intraoperative photograph showing an oval shape defect in the posterior wall of the infected aorta (arrow), leading into a huge pseudoaneurysm cavity (AO: aorta; CA: celiac axis; LRA: left renal artery; RRA: right renal artery; SMA: superior mesenteric artery).

angiogram (Fig. 2) revealed a pseudoaneurysm arising from the paravisceral aorta with involvement of the celiac axis and superior mesenteric artery. Intravenous antibiotics, including Ceftriaxone and Ciprofloxacin, were administered.

Surgery was performed through a left thoracoabdominal incision and the paravisceral segment of the aorta exposed using medial visceral rotation.⁵ A large oval shaped defect of 2×3 cm was found in the posterior wall of the paravisceral aorta leading to a large pseudoaneurysm on the right posterolateral aspect of the aorta (Fig. 3). There was inflammation and edema of the retroperitoneum, but gross pus was absent. The mycotic segment of the paravisceral aorta was resected and arterial reconstruction achieved using an interposition 16 mm woven dacron tube graft from the distal thoracic aorta to a healthy abdominal aortic segment just above the left renal artery origin. The celiac axis, superior mesenteric artery and right renal artery were reimplemented as a single Carrel patch. The left renal artery was spared. The pseudoaneurysm cavity was debrided and irrigated.

The patient recovered uneventfully from the operation.

Intraoperative cultures of the thrombus, aortic wall and blood clots were all negative. He was given intravenous antibiotics for 6 weeks and subsequently kept on ofloxacin, 100 mg twice daily, as a maintenance dose. The erythrocyte sedimentation rate returned to normal. Postoperative computed tomography showed a patent graft with a small residual collection over the previous pseudoaneurysm. A follow-up scan was repeated 1 month and 6 months postoperatively showing complete resolution of the collection.

The patient was followed up for 18 months and has remained well.

Discussion

Salmonella is an important causative agent in mycotic aortic aneurysm. It has been reported to be responsible for 42.5% of infected infrarenal aortic aneurysms.⁶ However, when mycotic aneurysms in all sites were considered, *Staphylococcus aureus* was found to be the predominant organism, especially in this era of increasing arterial instrumentation and arterial complications from intravenous drug abusers.⁷ Salmonella mycotic aneurysm had been uniformly fatal from systemic sepsis and arterial rupture prior to the advent of potent antibiotics and modern vascular reconstruction. The first survivor from ruptured aorta due to Salmonella aortitis was reported in 1962 by Sower,⁸ when the condition was successfully treated with resection and interposition graft. In the last three decades, the mortality and morbidity from Salmonella aortic infection remained high.²

Salmonella can invade normal arterial intima, a structure which is usually resistant to bacterial infection.⁹ This is the case in our patient whose abdominal aorta is relatively healthy with no significant atherosclerotic disease. It can infect pre-existing aortic aneurysm or the native aorta, leading to aortitis and subsequent mycotic aneurysm. Atherosclerotic arteries are at an increased risk of infection and aneurysm formation during Salmonella bacteriemia.¹⁰ Early diagnosis is important before fatal rupture or uncontrolled systemic sepsis occurs. The classic triad of fever, abdominal pain and pulsatile abdominal mass² may not be present. A high index of suspicion is therefore important. In our patient all subsequent cultures were negative, probably due to the antibiotics prescribed and suggestive physical signs were masked. The diagnosis was made with a positive Widal test and the presence of a mycotic aneurysm. The posi-

tive urine culture was probably due to septic emboli from the mycotic aneurysm.

With the advent of duplex ultrasound, initial screening with duplex scan, which is non-invasive and can be performed quickly, even at bedside, should be considered whenever there is suspicion. Other imaging techniques, especially computed tomography and angiogram, are important in making the definite diagnosis as well as delineating the extent of the lesion so as to facilitate preoperative planning.

The management of mycotic aneurysm is surgical. The mortality rate associated with medical treatment approaches 100%¹¹ with only isolated case reports of survivors.¹²⁻¹³ The recommended management strategy includes potent antibiotics, adequate debridement and revascularization. The best method of revascularization⁶⁻⁸ *in situ* prosthetic bypass or extra-anatomic bypass is still controversial.

Aortic ligation and extra-anatomic bypass had been considered the standard treatment for aortic sepsis.¹⁴ Extra-anatomic bypass has the advantage of avoiding graft conduit in an infected field and hence decreasing the chance of subsequent prosthetic graft infection. However, extra-anatomic bypass may not always be possible or would involve complex autogenous visceral revascularization, especially in cases with paravisceral aortic involvement. The long term patency rate of extra-anatomic bypass is not favorable and subsequent aortic revascularization may be necessary. In the presence of bacteriemia, even a remote prosthetic graft may be infected.

In situ reconstruction with prosthetic graft is the alternative method for revascularization. It is especially useful when no remote or extra-anatomic route is available to maintain perfusion, or when the mycotic segment is in the paravisceral aorta. It has the disadvantage of placing a graft in an infected field and hence creates a potential for infection. A high rate of re-operation for graft complication and residue sepsis was reported in some patients with abdominal aortic sepsis treated with *in situ* prosthetic reconstruction.¹⁵ Some conclude that *in situ* reconstruction should not be used in patients with Gram negative sepsis.¹⁶ However, the success of prosthetic valve replacement in patients with valvular insufficiency due to infective endocarditis has demonstrated that *in situ* reconstruction is a feasible option. More recently, some surgeons favor *in situ*

reconstruction, especially in paravisceral abdominal aortic infection. Chan¹⁷ reviewed the unique experience from Houston with 22 mycotic aortic aneurysm treated with *in situ* prosthetic graft. Nineteen of their 22 patients survived for periods ranging from 3 months to more than 7 years. In another literature review by Atnip,¹⁸ *in situ* prosthetic reconstruction in patients with mycotic suprarenal aortic aneurysm was found to have a better survival as compared to those with extra-anatomic bypass. Techniques such as omental flap coverage⁴ or antibiotic-releasing carriers¹⁹ had also been advocated to reduce the chance of infection of *in situ* bypass.

The optimal duration of antibiotic treatment in mycotic aneurysms is not well established. However, it is generally agreed that appropriate antibiotics should be administered intravenously for 4-6 weeks after operation.²⁰ Some even suggested life long antibiotics after *in situ* bypass, especially in Salmonella infection.²⁰

In our patient, the mycotic segment was located at the paravisceral aorta. This poses a particular problem because of the importance of these vital vessels and the difficulty in exposure and access to this region. We advocate the use of transabdominal medial visceral rotation,⁵ as it offers a satisfactory exposure and allows access to these vital branches. The celiac and the superior mesenteric artery orifices in this patient could not be closed to allow retrograde filling with extra-anatomic bypass. With potent perioperative antibiotics and adequate intraoperative debridement, *in situ* reconstruction was successfully performed with reimplantation of the celiac, superior mesenteric and right renal arteries as a single Carrel patch.

We believe that *in situ* prosthetic graft reconstruction of the paravisceral aorta is a viable option and can be successfully used in Salmonella aortitis.

Conclusions

Salmonella is an important causative agent in mycotic aortic aneurysm that carries significant mortality and morbidity. The presentation may be vague and a high index of suspicion is required in order to make the diagnosis early so that prompt treatment can be instituted. Imaging techniques such as computed tomography and angiogram are useful in arriving at a diagnosis as well as planning of the opera-

tion. Appropriate perioperative antibiotics, adequate debridement and vascular reconstruction are the keys to successful treatment. *In situ* bypass appears to be a safe option for revascularization, especially in mycotic paravisceral aortic aneurysm. Life long suppressive dose of antibiotic is preferable in this situation.

References

1. Flamand F, Harris KA, DeRose G, Karam B, Jamieson WG. Arteritis due to salmonella with aneurysm formation: two cases. *Can J Surg* 1992;35:248-52.
2. Oskoui R, Davis WA, Gomes MN. Salmonella aortitis. A case report of successfully treated case with a comprehensive review of the literature. *Arch Intern Med* 1993;153:517-25.
3. Pasic M, Carrel T, Tonz M, Vogt P, von-Segesser L, Turina M. Mycotic aneurysm of the abdominal aorta: extra-anatomic versus *in situ* reconstruction. *Cardiovasc Surg* 1993;1:48-52.
4. Trairatvorakul P, Sriphojanart S, Sathapatayavongs B. Abdominal aortic aneurysms infected with salmonella: problems of treatment. *J Vasc Surg* 1990;12:16-9.
5. Reilly LM, Ramos TK, Murray SP, Cheng SWK, Stoney RJ. Optimal exposure of the proximal abdominal aorta: A critical appraisal of transabdominal medial visceral rotation. *J Vasc Surg* 1994;19:375-90.
6. Pichelle JM, Tabet G, Cormier P, Farkas JC, Laurian C, Gigou F *et al*. Infected infrarenal aortic aneurysms: when is *in situ* reconstruction safe? *J Vasc Surg* 1993;17:635-45.
7. Brown SL, Busutil RW, Baker JD, Machleder III, Moore WS, Baker WF. Bacteriologic and surgical determinants of survival in patients with mycotic aneurysms. *J Vasc Surg* 1984;1:541-7.
8. Sower ND, Whelan TJ. Suppurative arteritis due to salmonella. *Surgery* 1962;52:851-9.
9. Johansen K, Devin J. Mycotic aortic aneurysm. A reappraisal. *Arch Surg* 1983;118:583-8.
10. Oz MC, Brener BJ, Buda JA, Todd G, Brenner RW, Goldenkranz RJ *et al*. A ten-year experience with bacterial aortitis. *J Vasc Surg* 1989;10:439-49.
11. Jacobs MJHM, Reul GJ, Gregoric I, Cooley DA. *In situ* replacement and extra-anatomic bypass for the treatment of infected abdominal aortic grafts. *Eur J Vasc Surg* 1991;5:83-6.
12. Donabedian H. Long term suppression of Salmonella aortitis with an oral antibiotic. *Arch Intern Med* 1989;149:1452.
13. Aguado JM, Fernandez-Guerrero ML, La Banda F, Garces JLG. Salmonella infections of the abdominal aorta cured with prolonged antibiotic treatment. *J Infect* 1987;14:135-9.
14. Anderson CB, Butcher HR, Ballinger WF. Mycotic aneurysms. *Arch Surg* 1974;109:712-7.
15. Ewart JM, Burke ML, Bunt TJ. Spontaneous abdominal aortic infections: essentials of diagnosis and management. *Am Surg* 1983;49:37-50.
16. Bunt TJ, Wilson TG. Infected abdominal aortic aneurysm. *South Med J* 1985;78:419-22.
17. Chan FY, Crawford ES, Coselli JS, Safi HJ, Williams TW Jr. *In situ* prosthetic graft replacement for mycotic aneurysm of the aorta. *Ann Thorac Surg* 1989;47:193-203.
18. Atnip RG. Mycotic aneurysms of the suprarenal abdominal aorta: prolonged survival after *in situ* aortic and visceral reconstruction. *J Vasc Surg* 1989;10:635-41.
19. Pasic MP, von-Segesser L, Turina M. Implantation of antibiotic-releasing carriers and *in situ* reconstruction for treatment of mycotic aneurysm. *Arch Surg* 1992;127:745-6.
20. Onoda K, Hayashi T, Mizumoto T, Shimpo H, Tanaka K, Katayama Y *et al*. One stage repair of salmonella enteritidis-infected infrarenal aortic aneurysm. *Vasc Surg* 1994;9:619-26.