

# Combined endo-laparoscopic surgery for difficult benign colorectal polyps

Zhong-Hui Liu<sup>1</sup>, Li Jiang<sup>1</sup>, Fion Siu-Yin Chan<sup>1,2</sup>, Michael Ka-Wah Li<sup>3</sup>, Joe King-Man Fan<sup>1,2,3</sup>

<sup>1</sup>Department of Surgery, The University of Hong Kong-Shenzhen Hospital, Shenzhen 518053, China; <sup>2</sup>Department of Surgery, The University of Hong Kong, Hong Kong, China; <sup>3</sup>Asia-Pacific Endo-Lap Surgery Group (APELS), Hong Kong, China

**Contributions:** (I) Conception and design: JKM Fan, MKW Li; (II) Administrative support: MKW Li; (III) Provision of study materials or patients: FSY Chan; (IV) Collection and assembly of data: ZH Liu, L Jiang; (V) Data analysis and interpretation: ZH Liu; FSY Chan; JKM Fan; (VI) Manuscript writing: All authors; (VII) Final approval of manuscript: All authors.

**Correspondence to:** Joe King-Man Fan, MBBS (HK), MS (HKU), FRCSEd, FACS. Department of Surgery, The University of Hong Kong-Shenzhen Hospital, Shenzhen 518053, China. Email: drfanj@gmail.com.

**Abstract:** Prevention of colorectal cancer (CRC) depends largely on the detection and removal of colorectal polyps. Despite the advances in endoscopic techniques, there are still a subgroup of polyps that cannot be treated purely by endoscopic approach, which comprise of about 10–15% of all the polyps. These so-called “difficult colorectal polyps” are polyps with large size, morphology, at difficult location, scarring or due to recurrence, which have historically been managed by surgical segmental resection. In treating benign difficult colorectal polyps, we have to balance the operative risks and morbidities associated with surgical segmental resection. Therefore, combined endoscopic and laparoscopic surgery (CELS) has been developed to remove this subgroup of difficult benign polyps. We review the currently use of CELS for difficult benign colorectal polyps which includes laparoscopy-assisted endoscopic polypectomy (LACP), full-thickness laparo-endoscopic excision (FLEX) and colonoscopy-assisted laparoscopic wedge resection (CAL-WR).

**Keywords:** Combined; endo-laparoscopic; colorectal; polyps

Submitted Nov 27, 2019. Accepted for publication Dec 05, 2019.

doi: 10.21037/jgo.2019.12.11

**View this article at:** <http://dx.doi.org/10.21037/jgo.2019.12.11>

## Introduction

Colorectal cancer (CRC) ranked globally the third for cancer incidence and fourth for cancer related death (1). CRC is developed mainly from colorectal adenomatous polyps via pathway of adenoma-carcinoma sequence and therefore, its prevention depends largely on early detection and removal of adenomatous polyps (2,3). It was reported that the incidence of CRC significantly decreased by 76–90% with endoscopic removal of colorectal adenomatous polyps (4). In recent years, there was implementation of national colorectal cancer screening program in many countries and increasing detection of premalignant or early malignant colorectal polyps was observed (5). Most of the polyps can be removed by conventional endoscopic procedures, including cold/hot biopsy, snare polypectomy

or endoscopic mucosal resection (EMR). With rapid advancement in endoscopic technology, many large sessile polyps and early cancerous polyps (pTis/pT1a) can also be safely treated by endoscopic submucosal dissection (ESD) or transanal endoscopic operation (TEO) (for rectal polyps). Nonetheless, about 10–15% of polyps are considered as “difficult colorectal polyps” as they cannot be treated simply by either conventional or advanced endoscopic procedures (6), largely due to its size, morphology (sessile or flat), unfavorable location for endoscopic treatment (especially over sigmoid colon or cecum) or submucosal scar from previous attempts of endoscopic removal. These difficult colorectal polyps have historically been managed by surgical resection, which is associated with 10–15% morbidity, namely, leakage, infection and bleeding. Although minimally invasive surgery can achieve

oncological safe resection for cancerous polyps, studies have reported that only a small portion (18.2–20%) of these difficult polyps are invasive cancer (7,8). Majority of the polyps can be safely treated by limited, local resection.

With the advances in imaging technology, combined endoscopic and laparoscopic surgery (CELS) have been developed to treat lesions not suitable for simple endoscopic surgery. We would like to review the current advances and clinical application of CELS in management of difficult colorectal polyps.

When colorectal polyp is found during endoscopic examination, choice of treatment is based mainly on the size of the lesion. Reported incidence of malignancy for polyps >2 cm was 18% while those <1 cm was less than 10% (9,10). Small polyps (less than 5 mm) is usually taken by cold or hot biopsy. Polyps of 6–9 mm are excised by snare polypectomy or EMR. The majority of pedunculated polyps can be resected easily by snare polypectomy. For some giant pedunculated polyps ( $\geq 30$  mm), snare polypectomy can be done but is associated with higher risk of post resection bleeding. Choi *et al.* introduced endoscopic submucosal dissection of the polyp stalk for this kind of giant pedunculated polyps, the results were promising and *en bloc* resection was achieved for all patients, with no intra-operative bleeding. Post polypectomy bleeding occurred only in one case (4%), suggesting that ESD is an effective and safe option for treatment of difficult giant pedunculated or sub-pedunculated polyps (11). For sessile polyps larger than 10mm, treatment algorithm is more complicated. It is vital to distinguish malignant and benign polyps before offering endoscopic resection, as segmental colectomy should be performed for pT1b cancer, which has an incidence of approximately 10% of lymph node metastasis (12–14). The majority of benign or early cancerous polyps can be treated by endoscopic resection, like EMR or ESD. For early cancer of pTis or pT1a (submucosal invasion <1,000 mm) tumor, submucosal *en bloc* resection is oncological radical treatment with favorable long-time outcome. Endoscopic characteristics suggesting benign polyps are size <2 cm; soft consistency; regular contour; no depressed morphology; non-ulcerated; Kudo pit pattern type I–IV; predominant regular or sparse irregular vascular patterns on NBI; able to lift with submucosal injection.

For sessile polyps larger than 20 mm without features of malignancy, ESD should be considered as first line treatment which serves both diagnostic and therapeutic purposes. Gamaleldin *et al.* conducted a case-matched study comparing the outcomes of patients who underwent ESD

with those who underwent laparoscopic colectomy for large benign colorectal polyps, the results showed that ESD had a 43% cost-reduction advantage over laparoscopic colectomy and a 6% lower complication rate (15). Complete resection with clear proximal, distal and circumferential margins is indispensable to enable both precise pathological diagnosis and curative potential (16). If the histology of the specimen indicates invasive carcinoma (>pT1b), a tumor-positive margin, an unfavorable histologic grade, vascular invasion, or grade 2/3 tumor budding, subsequent formal colectomy with lymph node dissection should be considered.

Despite the advances in endoscopic resection techniques for difficult colonic polyps, there is still a subgroup of polyps that are endoscopically unresectable, which has historically been managed by surgical resection. Most studies reported favorable outcomes of laparoscopic resection for endoscopically unresectable benign polyps, operative risks including iatrogenic injury, bleeding, infection, and anastomotic leakage cannot be ignored: whereas the morbidity and mortality rate were reported as 9.3–21% and 0–2.7% respectively (5,15,17).

Combining laparoscopic and endoscopic techniques to perform a local excision for difficult benign polyps is a possible alternative, and the potential risks of surgical resection is avoided. Wilhelm *et al.* reported a 10-year experiences and follow-up of CLES for colorectal polyps in 154 patients, showing good outcomes of CELS with a conversion rate of 5%, intraoperative and postoperative complication rate of 1% and 3%, respectively (18). There are three main kinds of CELS, which are laparoscopic-assisted colonoscopic polypectomy (LACP), full-thickness laparo-endoscopic excision (FLEX) and colonoscopy-assisted laparoscopic wedge resection (CAL-WR). The major clinical studies on CELS are listed in *Table 1* (operative details) and *Table 2* (surgical outcomes).

### LACP (Figure 1)

This approach includes laparoscopic-assisted endoscopic EMR or ESD depending on the diameter and suspected histology of the polyps. For benign polyps less than 2 cm, laparoscopic-assisted EMR (LA-EMR) would be the preferred choice. For polyps larger than 2 cm without features of malignancy, laparoscopic-assisted piecemeal EMR or ESD (LA-ESD) can be considered. For polyps suspicious of early cancer, LA-ESD should be performed to achieved clearance of circumferential and deep margins. After induction of general anesthesia, patients will be placed

**Table 1** The operative details of the key human studies regarding of CELS

First author	Publication year	Procedures	Patient number	Median polyp size (cm)	Polyp location	Insufflation	Operating time (min)	Intra-op complications (%)	Conversion rate (%)
Lee (19)	2013	LACP	65	3	Cecum 43.1% Right colon 21.5% Hepatic flex 16.9% Transverse 6.2% Left colon 1.5% sigmoid 10.8%	CO <sub>2</sub>	145 (50–249)	0	26.2
Goh (20)	2014	LACP	30	NA	Cecum 16.7% Ascending 10% Transverse 16.7% Left colon 10% sigmoid 46.6%	CO <sub>2</sub>	105 (75–125)	0	26.6
Grünhagen (21)	2011	LACP	10	2	Transverse 10% Splenic flex 10% Descending flex 10% Rectosigmoid 70%	Air	NA	0	10
Franklin Jr (22)	2007	LACP	110	2.3	Right colon 59.1% Transverse 12.1% Left colon 6.7% Rectosigmoid 22.1%	CO <sub>2</sub>	NA	0	17.3
Wood (23)	2011	LACP	13	3	Cecum 46% Ascending 23% Hepatic flex 15% Transverse 8% sigmoid 46.6%	Air	NA	0	23.1
Cruz (24)	2011	LACP	25	2.4	Cecum 9.1% Hepatic flex 24.2% Transverse 12.1% Sigmoid 24.2% Ascending 15.2%	Air	92.7±31.0	0	24

**Table 1** (continued)

Table 1 (continued)

First author	Publication year	Procedures	Patient number	Median polyp size (cm)	Polyp location	Insufflation	Operating time (min)	Intra-op complications (%)	Conversion rate (%)
Lascarides (25)	2016	LACP	17	2.7	Cecum 64.7% Ascending 11.8% Hepatic flex 11.8% Transverse 11.8%	Air	90 (60–161)	0	11.8
Franklin Jr (26)	2009	LACP	160	3.7	Right colon 59% Transverse 14% Left colon 8% Rectosigmoid 19%	CO <sub>2</sub>	96.5	0	2.5
Lin (27)	2016	FLEX	3	2	Cecum 33.3% Ascending 66.7%	CO <sub>2</sub>	194 (129–241)	0	0
Fukunaga (28)	2014	FLEX	3	2.7	NA	CO <sub>2</sub>	182 (178–255)	0	0
Currie (29)	2019	FLEX	10	3.5	Cecum 54.5% Right colon 27.3% Descending 18.2%	CO <sub>2</sub>	113–296	0	27.3
Wilhelm (18)	2009	LACP 5.5% FLEX 27.4% CAL-WR 49.3% EASC 18%	146	NA	Cecum 31% Right colon 27% Transverse 13% Left colon 4% Rectosigmoid 25%	NA	100 (40–272)	2	5
Yan (30)	2011	LACP 61% CAL-WR 26%	23	3	Cecum 52% Ascending 35% Hepatic flex 13%	CO <sub>2</sub>	NA	0	13
Giavarini (31)	2013	CAL-WR	15	3	Cecum: Anterior wall 60% Posterior wall 27% Lateral wall 13%	CO <sub>2</sub>	62±15	0	0
Leicher (32)	2017	CAL-WR	8	2.8	Cecum 37.5% Transverse 25% Hepatic flex 12.5% Splenic flex 12.5% Sigmoid 12.5%	CO <sub>2</sub>	132 (110–170)	0	0

LACP, laparoscopy-assisted colonoscopic resection; FLEX, full-thickness laparoendoscopic resection; CAL-WR, colonoscopy-assisted laparoscopic wedge resection; EASC, endoscopy-assisted segmental colectomy; NA, not available.

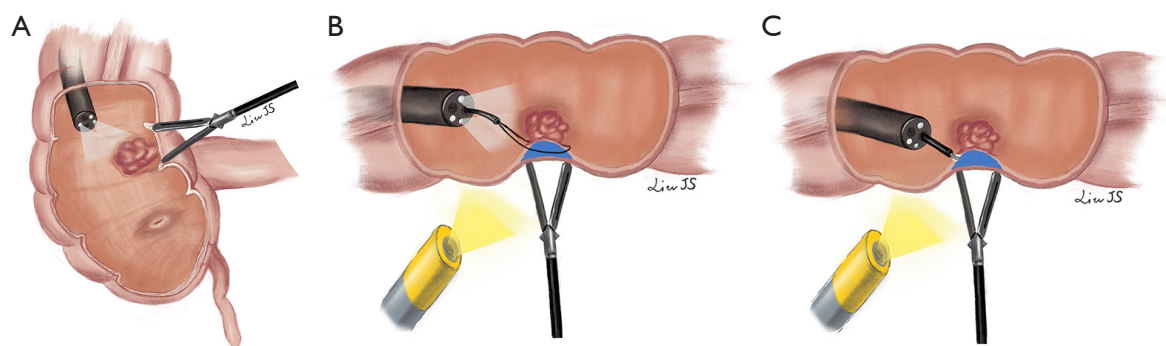
**Table 2** The surgical outcomes of the key human studies regarding of CELS

First author	Publication year	Procedures	Colonic Leak (%)	Post-op complications (%)	Mortality (%)	LOS (days)	Invasive cancer (%)	Prognosis (months)
Lee (19)	2013	LACP	0	4.4	0	1	1.5	10% recurrence at 65 m
Goh (20)	2014	LACP	0	13.3	0	2	6.7	No local recurrence at 20 m
Grünhagen (21)	2011	LACP	0	10%	0	1	10	No recurrence at 11 m
Franklin Jr (22)	2007	LACP	0	2.7	0	1	9.1	No recurrence at 6 m
Wood (23)	2011	LACP	0	15.4	0	2	NA	NA
Cruz (24)	2011	LACP	0	8	0	1.5	12	NA
Lascarides (25)	2016	LACP	0	11.8	0	3	0	10% local recurrence at 15.3 m
Franklin Jr (26)	2009	LACP	0	5.6	0	1.1	10.2	No recurrence at 65 m
Lin (27)	2016	FLEX	0	0	0	1	0	NA
Fukunaga (28)	2014	FLEX	0	0	0	6–12	0	No recurrence at 12 m
Currie (29)	2019	FLEX	0.9	36.4	0.9	3–5	27.30%	NA
Wilhelm (18)	2009	LACP 5.5%	0	3	0	8	11.6	0.9% local recurrence at 31 m
		FLEX 27.4%						
		CAL-WR 49.3%						
		EASC 18%						
Yan (30)	2011	LACP 61%	0	0	0	2	0	13% local recurrence at 12 m
		CAL-WR 26%						
Giavarini (31)	2013	CAL-WR	0	0	0	3	NA	NA
Leicher (32)	2017	CAL-WR	0	0	0	1–2	12.5	NA

LACP, laparoscopy-assisted colonoscopic resection; FLEX, full-thickness laparoendoscopic resection; CAL-WR, colonoscopy-assisted laparoscopic wedge resection; EASC, endoscopy-assisted segmental colectomy; NA, not available.

in modified lithotomy position to facilitate intraoperative colonoscopy. Camera port is inserted at sub-umbilical region and pneumoperitoneum is created for laparoscopic exploration. Endoscopists then perform colonoscopy to localize the lesion and assess the suitability for EMR/ESD or need for immediate surgical resection. CO<sub>2</sub> instead of air should be used for gas insufflation during

colonoscopy (19,20), as CO<sub>2</sub> can readily be absorbed to venous circulation. The polyp is then marked with indigo carmine (19) or vascular clip (33) intra-luminally by colonoscopy and can be identified laparoscopically. Additional 5-mm working ports (21), will be placed according to the location of the lesions (always at sites opposite to the lesions). If the polyp is located at a difficult



**Figure 1** LACP. (A) Using laparoscopic forceps to help inverting the colonic polyp; (B) colonic polyp is removed by LACP-EMR; (C) colonic polyp is removed by LACP-ESD. LACP, Laparoscopy-assisted colonoscopic polypectomy; EMR, endoscopic mucosal resection; ESD, endoscopic submucosal dissection.

location with sharp angulation or at retroperitoneal side, the colon is mobilized laparoscopically for better exposure and access (Figure 1A). The lesion is elevated as usual with submucosal injection of either saline (34), adrenaline in saline (20), or mannitol and methylene blue dye solution (22). EMR will be performed by endoscopic snare (Figure 1B) while ESD will be performed by use of endoscopic knives (like Dual-knives, Hook-knives, IT-knives, etc.) under direct laparoscopic vision of the colonic serosa (Figure 1C). If a full-thickness injury or perforation is suspected, laparoscopic suture repair can be performed. The integrity of the bowel can be ascertained by air-leak test with the use of CO<sub>2</sub> insufflation using colonoscopy. The specimen is finally retrieved transanally. Some institutions perform frozen section for the resected specimens routinely. However, most believed that frozen section is unnecessary with exception for firm or multi-lobulated polyps, as the reported rate of missed cancer is low (only 1.5%) based on clinical judgement of the specimens (19).

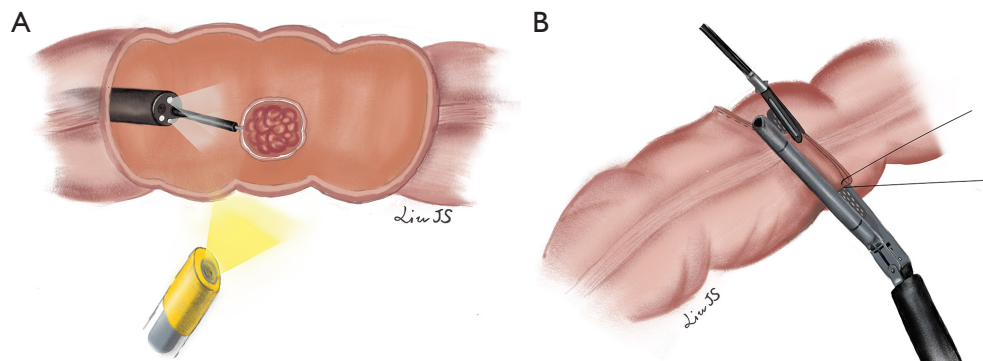
Many authors have reported excellent outcomes of LACP compared with laparoscopic resection. The advantages of LACP are less complication, fast recovery, and less cost (24,25,35). Many centers have reported no major complication by LACP approach. Recovery is similar to endoscopic polypectomy alone, Length of stay (LOS) is 2.5 days less on average compared with laparoscopic colectomy (25,35). Lascarides *et al.* conducted a single-center randomized controlled study comparing LACP and laparoscopic right colectomy (LRC) for endoscopically unresectable polyps of the right colon. Results showed post-operative length of stay (LOS) was much shorter for LACP than LRC (2.63 *vs.* 4.94 days) (25). Long-term follow up showed lower local recurrence rate for LACP. Franklin ME

Jr reported no post-operative recurrence in a mean follow-up of 63.37 months in 160 patients (26). Wilhelm *et al.* reported a 0.9% local recurrence rate in a mean follow up of 2.9 years (18).

LACP also is a good alternative treatment for colonic polyps (>1 cm) found under radiological examination and previously incomplete colonoscopy (obesity, redundancy of sigmoid colon, or adhesion after abdominal surgery), which accounted in 8–10% of endoscopic examinations. Quyn *et al.* reported successful intraoperative endoscopic polypectomy after laparoscopic colonic mobilization in all the 12 patients with incomplete preoperative colonoscopy. Recovery times were similar to endoscopic resection alone (36).

## FLEX

Full-thickness resections are mandatory in some special clinical scenarios (e.g., non-lifting recurrent adenomas due to submucosal scar and adenomas located near colorectal diverticulum). The advances in endoscopic devices and techniques allow endoscopists to perform endoscopic full-thickness resection (EFTR) for these lesions. However, the safety of intraluminal closure of colonic defect is a major concern for EFTR. There are three devices designed for endoscopic defect closure in EFTR procedure with unique techniques respectively. After the colonic lesion was endoscopically marked, it was maneuvered into the resection chamber, using either traction or suction, of the full-thickness resection device (FTRD; Ovesco Endoscopy, Tubingen, Germany) (37,38). The tissue fold was then excised and a stapled anastomosis was resulted. Whereas the tissue apposition systems (TAS) (Ethicon, Endo-Surgery



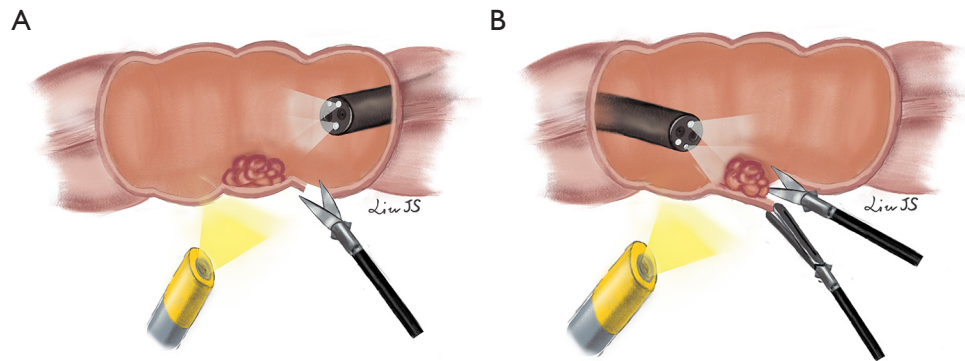
**Figure 2** Laparoscopy-assisted endoscopic FLEX. (A) Margins of polyp are marked using circumferential endoscopic argon plasma coagulation; (B) after transmural endoscopic sutures to evert the bowel, the polyp is resected by laparoscopic linear stapling. FLEX, full-thickness excision.

Inc., Cincinnati, USA) allows step-by-step closure of full-thickness colonic defect by a series of T-tags (39,40). The third device is Over-The-(endo)-Scope Clip (OTSC) (Ovesco Endoscopy, Tubingen, Germany) method, in which the edges of the colotomy were manipulated into the cap using a twin grasper (Ovesco, Endoscopy) and one or more OTSCs were deployed to close the defect (41,42). EFTR can be successfully performed in most of cases with low complication rate. Brigid *et al.* (43) reported a systematic review regarding the feasibility and safety of EFTR for colonic lesions, including 5 trials and 113 procedures. The result showed that overall success rate was high (89%), intraoperative complication rate was acceptable (22%). However, post-resection closure methods more commonly resulted in failure to close the defect (5–55%) and a high incidence of abnormal findings at postmortem examination (84%). EFTR should preferably be performed in high volume centers as it is indeed a technically demanding procedure associated with a steep learning curve.

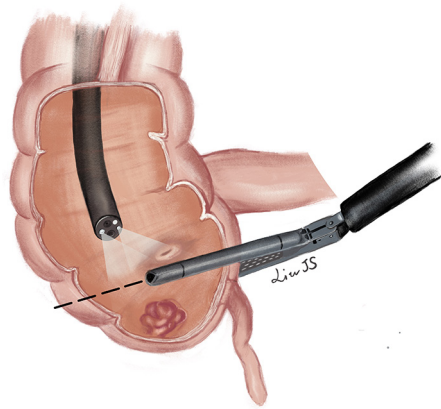
Laparoscopy offer an excellent extramural view of colon and preventing collateral injuries during endoscopic treatment. Laparoscopic suture or linear stapling for closure of colotomy are relatively simple compared to intraluminal defect closure by endoscopic devices. In addition, leak test can be performed by intraluminal gas insufflation to confirm the integrity of colon after closure. Therefore, FLEX will theoretically be safer than EFTR alone for treatment of colonic lesions. Brigid *et al.* (44,45) successfully performed FLEX for colonic lesions in experimental pig models in 2013. There were several different modifications of FLEX reported in humans. Currie *et al.* (29) introduced the following method: (I) circumferential marking of resection

margin of polyp using endoscopic argon plasma coagulation; (II) transmural endoscopic sutures to evert the bowel; (III) resection was completed by laparoscopic linear stapling (Figure 2). Fukunaga *et al.* (27,28) introduced a novel approach as: firstly, endoscopic circumferential mucosal incision was performed, then laparoscopic seromuscular dissection to meet the mucosal incision line created by the endoscopic procedure to ensure precise excision, finally linear stapler fired in an everted fashion to close the colon wall defect. For lesions located near the mesentery, Wilhelm *et al.* (18) suggest a small colotomy was performed after confirming location of the lesion under colonoscopic guidance, the lesion was elevated and resected by application of a linear-stapling device. Closure of the colotomy was achieved by utilizing laparoscopic sutures or linear stapling device (Figure 3). Colonic defect is closed by laparoscopic sutures or linear stapling device in the above FLEX techniques. The pooled results of these small-scale case series reviewed safe closure of colonic defect without post-operative leak or abscess. There was no residual or recurrent adenoma found by colonoscopy performed in 3–12 months after resection of polyp. FLEX is associated with high incidence of complete full-thickness resection of colonic polyp and successful closure of defect, with low incidence of residue lesion nor leakage.

Nevertheless, accurate preoperative assessment of three morphological features of the polyp, including its relation to the mesenteric border, tumor diameter and circumferential extent of involvement of the bowel wall, has to be observed. If the lesion is located at mesenteric side or involves more than half of the circumference of colonic wall, it is considered not suitable for FLEX due to risks of bleeding, ischemia and post-operative stricture. Currie



**Figure 3** Laparoscopy-assisted endoscopic FLEX for lesions close to mesentery. (A) A small colotomy is made under colonoscopic guidance; (B) the lesion is retracted and resected by laparoscopic dissection. The colotomy is then closed by laparoscopic sutures or linear stapling. FLEX, full-thickness excision.



**Figure 4** Colonoscopy-assisted laparoscopic wedge resection. After mobilization of the caecum, full-thickness excision is performed using a linear stapler.

*et al.* (29,46) suggested computed tomography colonography (CTC) should be done to select patients for FLEX. In their study, CTC correctly identified the location of the lesions in relation to the mesenteric border in all patients. CTC was also good for the assessment of the maximum diameter of the lesion and the circumferential extent of colonic wall involvement.

### CAL-WR

CAL-WR is another approach of local full-thickness

resection for benign colorectal polyps with combined laparoscopic and endoscopic techniques. CAL-WR is particularly suitable for caecal polyps where the bowel wall is too thin for EMR/ESD and the size of caecum can easily accommodate a wedge resection without carrying risk of stricture. CAL-WR is technically much simpler than LACP and can be performed when LACP or FLEX failed.

As with FLEX, part of the colon, where the polyp is located, is mobilized laparoscopically to ensure tensionless during the procedure. Colonoscope is intubated to confirm location the polyp and monitor adequate surgical margins when full-thickness wall excision is performed using a linear stapler from laparoscopic side. Advancing the endoscope beyond the affected segment serves as a guidance and prevent stricture during resection (30,31). It is important to check the patency of the residual lumen by colonoscopy before stapling off the polyp. For caecal polyps, passing the colonoscope into the terminal ileum helps to protect the ileocecal valve when the stapler clamping across the cecum. The specimen will be placed in a bag and retrieved via one trocar site (*Figure 4*).

Leicher *et al.* (32) made a small modification of CAL-WR, which they called limited CAL-WR. After colonoscopic localization of the lesion, they placed a suture laparoscopically through the base of the polyp under endoscopic visualization. The lesion was then excised tangentially with a linear stapler with the colonic wall lifted up by applying traction on the suture. The procedure was successfully performed in 12 patients with polyps not limited to caecum but also at sigmoid, transverse colon, hepatic or splenic flexure.

CAL-WR is technically less demanding and without



many complex procedures compared to LACP or FLEX. Giavarini *et al.* (31) and Leicher *et al.* (32) both reported 100% successful rate for CAL-WR in their studies. Operation time was shorter than LACP, ranging from 40–170 min. The risks for CAL-WR was much less than laparoscopic segmental colectomy (LSC). No intraoperative or postoperative complications was reported in several small-case studies. In a large cohort study including 146 patients underwent CLES and half of the patients (72 cases) underwent CAL-WR, the authors reported 2 cases of delay bleeding after operation which warranted surgical intervention, however they did not report the exact procedures performed in patients with complications (18). The hospital stay after CAL-WR was short, ranging for 1–5 days (30–32). As CAL-WR is full thickness excision, most authors had not reported any local recurrence at follow up colonoscopy. Wilhelm *et al.* (18) reported only one case (0.9%) out of 156 patients who had been primarily converted to open resection because of incomplete laparoscopic resection found to have local recurrence, in a follow-up of 2.9 ( $\pm 2.3$ ) years.

### Endoscopic-assisted laparoscopic segmental resection (EAL-SR)

For malignant polyps or those with huge diameter or located at mesenteric side, the methods mentioned above might not be suitable, and laparoscopic or open segmental resection is usually performed. Intraoperative endoscopy facilitates lesion localization and determination of extent of colonic resection. Studies have demonstrated good outcomes of this method without increasing conversion rate, operation time, or hospital stay (47,48). When the polyp is suspicious of malignancy by intraoperative colonoscopy assessment, CELS should be converted to EAL-SR for oncological radical resection.

### Conclusions

With recent advancement in laparoscopic and endoscopic equipment and techniques, there are different surgical techniques for excision of benign colonic polyps without mandatory need of segmental colectomy. Combined endoscopic and laparoscopic techniques can achieved complete resection of many “difficult colonic polyps” with low intraoperative or postoperative complications. Nonetheless, there is no consensus on the indications and types of CELS procedures to be performed. Yan *et al.* (30)

proposed a list of 15 criteria used in their center to assess the subgroup of patients who will be suitable for CELS for benign right colonic polyps, including: large or difficult anatomic location of right colonic polyps, size  $\leq 5$  cm; BMI  $\leq 35$ ; no emergency patients with obstruction or perforation; no IBD that needs surgery; no other abdominal malignant disease; no previous major abdominal surgeries, and so on. For benign polyps not suitable for endoscopic resection, if a patient fulfills the criteria, clinicians should consider CELS as treatment of choice before segmental colectomy. The choice of CELS largely depends on the features of the polyp, and the technical skills of surgeons and endoscopists. For polyps suspicious of invasive malignancy, segmental colectomy with lymph nodes dissection remains the preferred oncological radical treatment.

### Acknowledgments

The authors thank Dr. Jing-Si Liu for her excellent figure drawings for this paper.

### Footnote

*Conflicts of Interest:* The authors have no conflicts of interest to declare.

*Ethical Statement:* The authors are accountable for all aspects of the work in ensuring that questions related to the accuracy or integrity of any part of the work are appropriately investigated and resolved.

### References

1. Global Burden of Disease Cancer Collaboration, Fitzmaurice C, Dicker D, et al. The Global Burden of Cancer 2013. *JAMA Oncol* 2015;1:505-27.
2. Sievers CK, Zou L, Pickhardt PJ, et al. Modeling the rise of intratumoral heterogeneity in growing, static, and regressing human colorectal polyps. *Cancer Res Suppl* 2016;12;151.
3. Cho KR, Vogelstein B. Genetic alterations in the adenoma-carcinoma sequence. *Cancer* 1992;70:1727-31.
4. Winawer SJ, Zauber AG, Ho MN, et al. Prevention of colorectal cancer by colonoscopic polypectomy. The National Polyp Study Workgroup. *N Engl J Med* 1993;329:1977-81.
5. Marres CCM, Buskens CJ, Schriever E, et al. The impact of the national bowel screening program in the

- Netherlands on detection and treatment of endoscopically unresectable benign polyps, *Tech Coloproctol* 2017;21:887-91.
6. Zhang M, Shin EJ. Successful endoscopic strategies for difficult polypectomy. *Curr Opin Gastroenterol* 2013;29:489-894.
  7. Ross HM, Li C, Rosenthal J, et al. Laparoscopic colon resection for polyps: a good novice case? *Dis Colon Rectum* 2006;49:879-82.
  8. Pokala N, Delaney CP, Kiran RP, et al. Outcome of laparoscopic colectomy for polyps not suitable for endoscopic resection, *Surg Endosc* 2007;21:400-3.
  9. Kudo S, Kashida H, Tamura T, et al. Colonoscopic diagnosis and management of nonpolypoid early colorectal cancer. *World J Surg* 2000;24:1081-90.
  10. Bertelson NL, Kalkbrenner KA, Merchea A, Colectomy for endoscopically unresectable polyps: how often is it cancer? *Dis Colon Rectum* 2012;55:1111-6.
  11. Choi YS, Lee JB, Lee EJ, et al. Can endoscopic submucosal dissection technique be an alternative treatment option for a difficult giant ( $\geq 30$  mm) pedunculated colorectal polyp? *Dis Colon Rectum* 2013;56:660-6.
  12. Nakadoi K, Tanaka S, Kanao H, et al. Management of T1 colorectal carcinoma with special reference to criteria for curative endoscopic resection. *J Gastroenterol Hepatol* 2012;27:1057-62.
  13. Suh JH, Han KS, Kim BC, et al. Predictors for lymph node metastasis in T1 colorectal cancer. *Endoscopy* 2012;44:590-5.
  14. Son HJ, Song SY, Lee WY, et al. Characteristics of early colorectal carcinoma with lymph node metastatic disease. *Hepatogastroenterology* 2008;55:1293-7.
  15. Gamaleldin M, Benlice C, Delaney CP, et al. Management of the colorectal polyp referred for resection: A case-matched comparison of advanced endoscopic surgery and laparoscopic colectomy. *Surgery* 2018;163:522-7.
  16. Watanabe T, Itabashi M, Shimada Y, et al. Japanese Society for Cancer of the Colon and Rectum (JSCCR) Guidelines 2014 for treatment of colorectal cancer. *Int J Clin Oncol* 2015;20:207-39.
  17. Hauenschild L, Bader FG, Laubert T, et al. Laparoscopic colorectal resection for benign polyps not suitable for endoscopic polypectomy. *Int J Colorectal Dis* 2009;24:755-9.
  18. Wilhelm D, von Delius S, Weber L, et al. Combined laparoscopic-endoscopic resections of colorectal polyps: 10-year experience and follow-up. *Surg Endosc* 2009;23:688-93.
  19. Lee SW, Garrett KA, Shin JH, et al. Dynamic article: Long-term outcomes of patients undergoing combined endolaparoscopic surgery. *Dis Colon Rectum* 2013;56:869-73.
  20. Goh C, Burke JP, McNamara DA, et al. Endolaparoscopic removal of colonic polyps. *Colorectal Dis* 2014;16:271-5.
  21. Grünhagen DJ, van Ierland MC, Doornebosch PG, et al. Laparoscopic-monitored colonoscopic polypectomy: a multimodality method to avoid segmental colon resection. *Colorectal Dis* 2011;13:1280-4.
  22. Franklin ME Jr, Leyva-Alvizo A, Abrego-Medina D, et al. Laparoscopically monitored colonoscopic polypectomy: an established form of endoluminal therapy for colorectal polyps. *Surg Endosc* 2007;21:1650-3.
  23. Wood JJ, Lord AC, Wheeler JM, et al. Laparo-endoscopic resection for extensive and inaccessible colorectal polyps: a feasible and safe procedure. *Ann R Coll Surg Engl* 2011;93:241-5.
  24. Cruz RA, Ragupathi M, Pedraza R, et al. Minimally Invasive Approaches for the Management of "Difficult" Colonic Polyps. *Diagn Ther Endosc* 2011;2011:682793.
  25. Lascarides C, Buscaglia JM, Denoya PI, et al. Laparoscopic right colectomy vs laparoscopic-assisted colonoscopic polypectomy for endoscopically unresectable polyps: a randomized controlled trial. *Colorectal Dis* 2016;18:1050-6.
  26. Franklin ME Jr, Portillo G. Laparoscopic monitored colonoscopic polypectomy: long-term follow-up, *World J Surg* 2009;33:1306-9.
  27. Lin AY, O'Mahoney PR, Milsom JW, et al. Dynamic Article: Full-Thickness Excision for Benign Colon Polyps Using Combined Endoscopic Laparoscopic Surgery. *Dis Colon Rectum* 2016;59:16-21.
  28. Fukunaga Y, Tamegai Y, Chino A, et al. New Technique of En Bloc Resection of Colorectal Tumor Using Laparoscopy and Endoscopy Cooperatively (Laparoscopy and Endoscopy Cooperative Surgery - Colorectal), *Dis Colon Rectum* 2014;57:267-71.
  29. Currie AC, Blazeby JM, Suzuki N, et al. Evaluation of an early-stage innovation for full-thickness excision of benign colonic polyps using the IDEAL framework. *Colorectal Dis* 2019;21:1004-16.
  30. Yan J, Trencheva K, Lee SW, et al. Treatment for right colon polyps not removable using standard colonoscopy: combined laparoscopic-colonoscopy approach. *Dis Colon Rectum* 2011;54:753-8.

31. Giavarini L, Boni L, Cortellezzi CC, et al. Laparoscopic caecal wedge resection with intraoperative endoscopic assistance. *Int J Surg* 2013;11 Suppl 1:S58-60.
32. Leicher LW, de Vos Tot Nederveen Cappel WH, van Westreenen HL. Limited Endoscopic-Assisted Wedge Resection for Excision of Colon Polyps. *Dis Colon Rectum* 2017;60:299-302.
33. Hensman C, Luck AJ, Hewett PJ, et al. Laparoscopic-assisted colonoscopic polypectomy: technique and preliminary experience. *Surg Endosc* 1999;13:231-2.
34. Lee MK, Chen F, Esrailian E, et al. Combined endoscopic and laparoscopic surgery may be an alternative to bowel resection for the management of colon polyps not removable by standard colonoscopy. *Surg Endosc* 2013;27:2082-6.
35. Prohm P, Weber J, Bönner C, et al. Laparoscopic-assisted coloscopic polypectomy, *Dis Colon Rectum* 2001;44:746-8.
36. Quyn AJ, Vujovic Z, Ziyaie D, et al. Laparoscopic-assisted colonoscopy: results and follow-up endoscopic success. *Colorectal Dis* 2016;18:O376-79.
37. Velegraki M, Trikola A, Vasiliadis K, et al. Endoscopic full-thickness resection of colorectal lesions with the full-thickness resection device: clinical experience from two referral centers in Greece, *Ann Gastroenterol* 2019;32:482-8.
38. Kuellmer A, Mueller J, Caca K, et al. Endoscopic full-thickness resection for early colorectal cancer. *Gastrointest Endosc* 2019;89:1180-9.e1.
39. Raju GS, Malhotra A, Ahmed I. Colonoscopic full-thickness resection of the colon in a porcine model as a prelude to endoscopic surgery of difficult colon polyps: a novel technique (with videos). *Gastrointest Endosc* 2009;70:159-65.
40. Delaney CP, Champagne BJ, Marks JM, et al. Tissue apposition system: new technology to minimize surgery for endoscopically unresectable colonic polyps. *Surg Endosc* 2010;24:3113-8.
41. Schmidt A, Beyna T, Schumacher B, et al. Colonoscopic full-thickness resection using an over-the-scope device: a prospective multicentre study in various indications, *Gut* 2018;67:1280-9.
42. von Renteln D, Kratt T, Rosch T, et al. Endoscopic full-thickness resection in the colon by using a clip-and-cut technique: an animal study. *Gastrointest Endosc* 2011;74:1108-14.
43. Brigic A, Symons NR, Faiz O, et al. A systematic review regarding the feasibility and safety of endoscopic full thickness resection (EFTR) for colonic lesions. *Surg Endosc* 2013;27:3520-9.
44. Brigic A, Southgate A, Sibbons P, et al. Full-thickness laparoendoscopic colonic excision in an experimental model, *Br J Surg* 2013;100:1649-54.
45. Brigic A, Southgate A, Sibbons PD, et al. Full-thickness laparoendoscopic stapled excision of colonic lesion in a porcine ex vivo model. *Endoscopy* 2013;45 Suppl 2 UCTN:E167-8.
46. Currie AC, Burling D, Mainta E, et al. An analysis of the accuracy of computed tomography colonography when defining anatomy for novel full-thickness colonic excision techniques in early colonic neoplasia. *Colorectal Dis* 2016;18:983-88.
47. O. Zmora, A. J. Dinnewitzer, A. J. Pikarsky, et al. Intraoperative endoscopy in laparoscopic colectomy. *Surg Endosc* 2002;16:808-11.
48. Gorgun IE, Aytac E, Manilich E, et al. Intraoperative colonoscopy does not worsen the outcomes of laparoscopic colorectal surgery: a case-matched study. *Surg Endosc* 2013;27:3572-6.

**Cite this article as:** Liu ZH, Jiang L, Chan FSY, Li MKW, Fan JKM. Combined endo-laparoscopic surgery for difficult benign colorectal polyps. *J Gastrointest Oncol* 2019. doi: 10.21037/jgo.2019.12.11