

# WATCHMAN device-related thrombus successfully treated with apixaban

## A case report

Chun-Ka Wong, MBBS<sup>a</sup>, Pak-Hei Chan, MBBS<sup>a</sup>, Cheung-Chi Lam, MBBS<sup>a</sup>, On-Hing Kwok, MBBS<sup>b</sup>, Yat-Yin Lam, MD<sup>c</sup>, Chung-Wah Siu, MD<sup>a,\*</sup>

### Abstract

**Rationale:** Among atrial fibrillation patients with high risk of bleeding, left atrial appendage occlusion has emerged as an alternative to long-term oral anticoagulation therapy for stroke prevention. Device-related thrombus remains a major concern because it may result in recurrent embolic events. To date, there is no consensus on the optimal method of treating device-related thrombus.

**Patient concerns:** A 78-year-old man with atrial fibrillation had an episode of intracranial hemorrhage while taking warfarin. He subsequently underwent percutaneous placement of a 30-mm Watchman device to the left atrial appendage. He was prescribed dual anti-platelet therapy with aspirin and clopidogrel.

**Diagnosis:** Reassessment echocardiography 3 months later found device-related thrombus.

**Interventions:** The antithrombotic regimen was switched from dual antiplatelet therapy to apixaban.

**Outcomes:** Reassessment echocardiography 3 months later revealed complete resolution of the device-related thrombus. Apixaban was stopped. He had dual antiplatelet therapy for 6 more months followed by life-long aspirin. There was no bleeding complication since implantation of Watchman device.

**Lessons:** We demonstrated successful treatment of device-related thrombus with a short course of apixaban with complete resolution of thrombus. Further randomized controlled trials are required to determine the choice and duration of drug therapy for device-related thrombus.

**Abbreviations:** AF = Atrial fibrillation, INR = International normalized ratio, LAAO = Left atrial appendage occlusion.

**Keywords:** apixaban, atrial fibrillation, device related thrombus, left atrial appendage occlusion, stroke

## 1. Introduction

Among atrial fibrillation (AF) patients with high risk of bleeding, left atrial appendage occlusion (LAAO) has emerged as an alternative to long-term oral anticoagulation therapy for stroke prevention. Device-related thrombus remains a major concern because it may result in recurrent embolic events. To date, there is no consensus on the optimal method of treating device-related

thrombus. We report the management of an elderly patient with AF and a history of intracranial hemorrhage who underwent LAAO that was complicated by device-related thrombus.

## 2. Case report

A 78-year-old hypertensive man with a 4-year history of persistent AF was maintained on dose-adjusted warfarin therapy with excellent anticoagulation control. Time in therapeutic range was 100%. He developed a right intracerebral hemorrhage with left hemiparesis. On admission, his international normalized ratio (INR) was only 2.2; nonetheless anticoagulation was reversed with prothrombin complex and fresh frozen plasma. Serial computerized tomography of the brain showed gradual resolution of hematoma. He made a good neurological recovery and managed to walk unaided 6 months after the event. In view of the high CHA<sub>2</sub>DS<sub>2</sub>-VASc score (3: 2 for age and 1 for hypertension), high risk of recurrent intracerebral hemorrhage, and to prevent stroke, the patient underwent percutaneous placement of a 30-mm Watchman device to the left atrial appendage. He was prescribed dual antiplatelet therapy with aspirin 100mg daily and clopidogrel 75mg daily after the procedure. Transesophageal echocardiography performed 3 months later showed an apparently well-positioned device that occupied most of the left atrial appendage. Nonetheless there was a layer of thrombus measuring 0.6-cm thick over the atrial surface of the device (Fig. 1A and Video 1A, <http://links.lww.com/MD/B973>). The antithrombotic regimen was switched from

Editor: Fadi Khasawneh.

Informed consent: Obtained from patient in concern for this case report.

Supplemental Digital Content is available for this article.

The authors report no conflicts of interest.

<sup>a</sup> Cardiology Division, Department of Medicine, The University of Hong Kong,

<sup>b</sup> Cardiology Center, Hong Kong Sanatorium and Hospital, Happy Valley,

<sup>c</sup> Department of Medicine and Therapeutics, Faculty of Medicine, The Chinese University of Hong Kong, Prince of Wales Hospital, Shatin, Hong Kong, China.

\* Correspondence: Chung-Wah Siu, Cardiology Division, Department of Medicine, The University of Hong Kong, Queen Mary Hospital, Hong Kong, 852, China (e-mail: cwdsiu@hku.hk).

Copyright © 2017 the Author(s). Published by Wolters Kluwer Health, Inc.

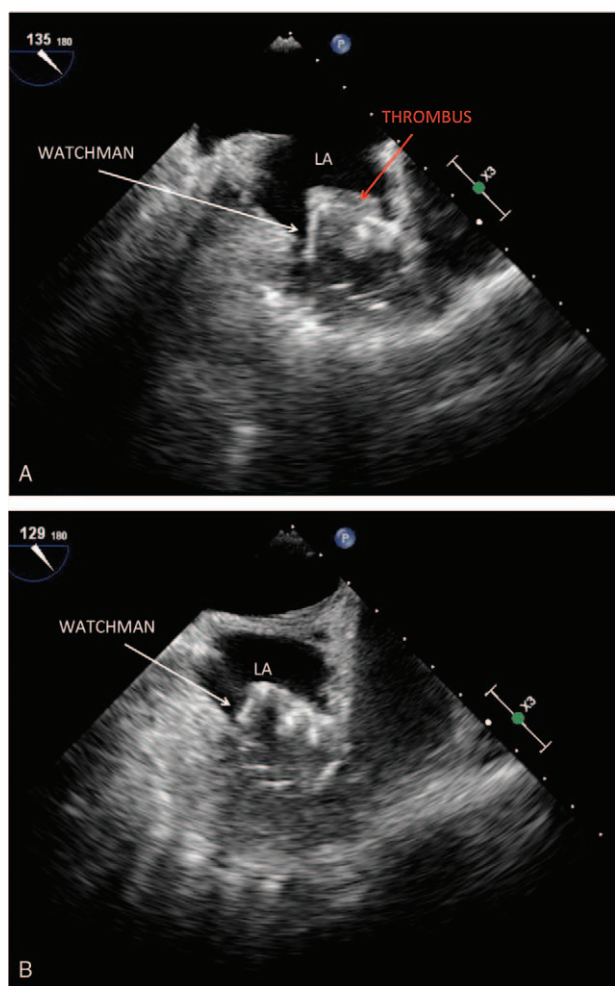
This is an open access article distributed under the Creative Commons Attribution-NoDerivatives License 4.0, which allows for redistribution, commercial and non-commercial, as long as it is passed along unchanged and in whole, with credit to the author.

Medicine (2017) 96:47(e8693)

Received: 7 March 2017 / Received in final form: 12 September 2017 /

Accepted: 23 October 2017

<http://dx.doi.org/10.1097/MD.00000000000008693>



**Figure 1.** (A) Transesophageal echocardiographic image showing a layer of device-related-thrombus over the surface of WATCHMAN. (B) Transesophageal echocardiographic image showing resolution of device-related thrombus after a course of apixaban.

dual antiplatelet therapy to apixaban 5mg twice a day. Reassessment transesophageal echocardiography 3 months later revealed complete resolution of the device-related thrombus (Fig. 1B and Video 1B, <http://links.lww.com/MD/B974>). Apixaban was stopped and he resumed dual antiplatelet therapy for 6 more months. Thereafter, he continued on life-long aspirin. There was no bleeding complication since implantation of Watchman device.

### 3. Discussion

Stroke prevention is the cornerstone of the modern management of AF. Current guidelines recommend long-term oral anticoagulation therapy for most patients with nonvalvular AF, except those with a CHA<sub>2</sub>DS<sub>2</sub>-VASc score <1 who are considered “true low risk.” Nonetheless, among patients at high risk of bleeding, particularly those with a previous history of intracranial hemorrhage, the benefit of long-term anticoagulation therapy is less certain. Since left atrial appendage accounts for the source of emboli in 90% of cases of nonvalvular AF, LAAO has emerged as an alternative to long-term oral anticoagulation

therapy for stroke prevention. For instance, in the PROTECT AF (Watchman Left Atrial Appendage System for Embolic Protection in Patients With AF) study, the Watchman device was noninferior to warfarin in preventing stroke in AF patients with a CHADS<sub>2</sub> score  $\geq 1$ .<sup>[1]</sup> The subsequent ASAP (ASA Plavix Feasibility Study With Watchman Left Atrial Appendage Closure Technology) registry demonstrated that implantation of the Watchman device followed by 6 months of dual antiplatelet therapy was safe even in AF patients in whom short-term anticoagulation therapy was contraindicated.<sup>[2]</sup> Despite this, thrombus formation on the device remains a major concern because it may result in recurrent embolic events. For instance, despite a warfarin transition for 6 months following Watchman device implantation in the PROTECT-AF study, post-implantation device-related thrombus was associated with an ischemic stroke risk of 0.3% per year. In addition, in a meta-analysis of 38 studies, 72 of 2397 patients (3%) who underwent LAAO developed device-related thrombus.<sup>[3]</sup> Risk factors for device-related thrombus included high CHADS<sub>2</sub> and CHA<sub>2</sub>DS<sub>2</sub>-VASc score, high platelet count, low left ventricular ejection fraction, and clopidogrel resistance. To date, there is no consensus on the optimal method of treating device-related thrombus. Traditionally, despite the lack of randomized controlled trials, warfarin therapy has been the standard of care for any thrombus detected in the systemic circulation such as in the left atrial appendage, and left ventricle. In cases of LAAO device-related thrombus, intravenous heparin, low-molecular-weight heparin, and warfarin have been previously used. There have also been recent reports of utilizing nonvitamin K antagonist oral anticoagulants to treat the condition.<sup>[4]</sup> Given its safety profile, apixaban appears to be the most compelling option. In the AVERROES study, compared with aspirin, apixaban reduced the risk of stroke or systemic embolism in AF patients not suitable for warfarin therapy. More importantly, there was no increase in the risk of major bleeding or intracranial hemorrhage amongst those on apixaban compared with aspirin.<sup>[5,6]</sup> In this report, we demonstrated successful treatment of device-related thrombus with a short course of apixaban with complete resolution of thrombus. Further randomized controlled trials are required to determine the choice and duration of drug therapy for device-related-thrombus, taking into account the risks of cardioembolism, recurrence of device-related thrombus and bleeding.

### References

- [1] Holmes DR, Reddy VY, Turi ZG, et al. Percutaneous closure of the left atrial appendage versus warfarin therapy for prevention of stroke in patients with atrial fibrillation: a randomised non-inferiority trial. *Lancet* 2009;374:534–42.
- [2] Reddy VY, Mobius-Winkler S, Miller MA, et al. Left atrial appendage closure with the Watchman device in patients with a contraindication for oral anticoagulation: the ASAP study (ASA Plavix Feasibility Study With Watchman Left Atrial Appendage Closure Technology). *J Am Coll Cardiol* 2013;61:2551–6.
- [3] Wei Z, Zhang X, Wu H, et al. A meta-analysis for efficacy and safety evaluation of transcatheter left atrial appendage occlusion in patients with nonvalvular atrial fibrillation. *Medicine* 2016;95:e4382.
- [4] Freixa X, Scalone G, Martin-Yuste V, et al. Large protruding thrombus over left atrial appendage occlusion device successfully treated with apixaban. *Eur Heart J* 2015;36:1427.
- [5] Connolly SJ, Ezekowitz J, Joyner C, et al. Apixaban in patients with atrial fibrillation. *N Engl J Med* 2011;364:806–17.
- [6] Ando G, Capranzano P. Non-vitamin K antagonist oral anticoagulants in atrial fibrillation patients with chronic kidney disease: A systematic review and network meta-analysis. *Int J Cardiol* 2017;231:162–9.