

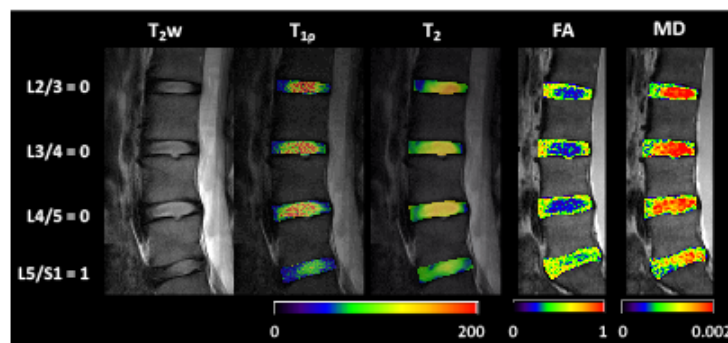
Multiparametric magnetic resonance imaging of normal and degenerative lumbar intervertebral discs

Mina Kim¹, Queenie Chan², Marina-Portia Anthony¹, Dino Samartzis³, Kenneth MC Cheung³, and Pek-Lan Khong¹

¹Department of Diagnostic Radiology, University of Hong Kong, Hong Kong, SAR, China, People's Republic of, ²Philips Healthcare, Hong Kong, ³Department of Orthopaedics and Traumatology, University of Hong Kong, Hong Kong, SAR, China, People's Republic of

Objective: Magnetic resonance imaging (MRI) has been shown to improve the diagnosis and management of patients with intervertebral disc (IVD) related disorders. Multiparametric MRI offers the possibility of noninvasively assessing multiple aspects of pathophysiological processes that exist simultaneously, thereby further assisting in patient treatment management. The purpose of this study is to determine the correlation between relaxation parameters ($T_{1\rho}$ and T_2), diffusion properties including fractional anisotropy (FA) and mean diffusivity (MD) measured by diffusion tensor imaging (DTI) and degenerative grades in human IVD.

Materials and Methods: After informed written consent was obtained, 21 subjects (mean age = 41.3 year; age range = 24-61 years; gender: 10 females, 11 males) with no prior spine surgery were recruited. All images of lumbar spine were acquired using a 3T Achieva scanner (Philips Healthcare, Best, The Netherlands) equipped with 40 mT/m gradients. RF was transmitted using the body coil and sensitivity encoding (SENSE) reception with the 8-element spine coil for human IVDs was employed. The $T_{1\rho}$ -weighted images were obtained with a 3D balanced turbo field echo (B-TFE) sequence with: TR/TE = 4.7ms/ 2.3 ms, flip angle= 30°, FOV= 180 x 200 mm², slice thickness= 10 mm, 5 slices in a sagittal plane, acquired pixel size= 0.55 x 0.78 mm², reconstructed pixel size= 0.52 x 0.52 mm². 5 subsequent $T_{1\rho}$ -weighted scans were performed with spin-lock durations of 1, 25, 50, 75 and 100 ms and with a scan time of 1 min. 8 sec. for each scan. Quantitative T_2 measurement in identical geometry as that of the $T_{1\rho}$ image was performed using standard multi-echo spin-echo sequence with TE= 30, 60, 90, 120 and 150 ms, acquired pixel size = 1.92 x 2.56 mm², reconstructed pixel size = 1.25 x 1.26 mm², FOV = 180 x 200 mm², slice thickness = 10 mm, single slice in a sagittal plane, and scan time = 2 min. 20 sec. 4 averaged minimally weighted (b_0) and 15 non-collinear diffusion-encoding directions (b -value = 500 s/mm²) which cover up to 5 levels of IVDs (L1/L2 to L5/S1) in sagittal plane were acquired using single shot EPI sequence. The imaging parameters were: TR = 3000 ms, TE = 71 ms, FOV = 180 x 72 mm², acquisition matrix = 180 x 141, reconstructed resolution = 0.625 x 0.625 mm², EPI factor = 71, 12 slices, slice thickness = 5 mm, gap = 1 mm, 4 averages and total scan time = 6 min. 24 sec. T_2w



images with same geometry as the DTI acquisition (low-resolution T_2w) were obtained in order to identify regions of interest (ROIs). Additionally, high-resolution T_2w images in sagittal plane were obtained for radiologic assessment of disc degeneration with: TR = 2500 ms, TE = 90 ms, FOV = 72 x 180 mm², acquisition matrix = 88 x 191, reconstructed resolution = 0.625 x 0.625 mm², 12 slices, slice thickness = 5 mm, gap = 1 mm, 2 averages and total scan time = 2 min. Using high-resolution T_2w , discs were graded by two spine specialists in consensus according to Schneiderman's classification (score range: 0 to 3) [1]. For data analysis, a custom-written program in Matlab (Mathworks, Natick, MA, USA) was used. Statistical analyses were performed with SPSS vr. 18.0 (Chicago, IL)

	$T_{1\rho}$	T_2	MD	FA
DDD	-0.674 (< .001)	-0.713 (< .001)	-0.735 (< .001)	-0.761 (< .001)
Age	-0.753 (< .001)	-0.834 (< .001)	-0.529 (< .001)	0.603 (< .001)

Results: Figure illustrates representative multiparametric MR images (T_2w , $T_{1\rho}$, T_2 , FA and MD) covering multiple lumbar disc levels (top to bottom) for a 28-year-old female subject.

Degenerative disc disease (DDD) grades were determined on T_2w image by qualitative assessment criteria. On the contrary, $T_{1\rho}$, T_2 , FA and MD maps quantitative differences on a voxel-by-voxel basis. By visual inspection, the nucleus pulposus (NP) and annulus fibrosus (AF) in IVDs were distinctively separable on the all quantitative maps while some of discs on T_2w images did not show clear difference between the NP and the AF. Table shows that Schneiderman grades and subject's age significantly correlated with all parameters ($p < 0.001$). Univariate analysis demonstrated that $T_{1\rho}$ correlated significantly with MD and FA ($r = 0.729$ and -0.715 , respectively; $p < 0.001$ for both). T_2 also correlated significantly with MD and FA ($r = 0.805$ and -0.811 , respectively; $p < 0.001$ for both). In addition, $T_{1\rho}$ showed significant correlation with T_2 ($r = 0.824$; $p < 0.001$).

Conclusion: In this study, we performed quantitative multiparametric MRI to investigate its sensitivity to changes in tissue microstructure of *in vivo* human lumbar IVDs. Our results suggest that each parameter may attribute different sensitivity to tissue properties.

References: [1] Schneiderman et al., 1987.